

Comparison of modified Kreyberg's, modified Papanicolaou, Ayoub-Shklar, and Haematoxylin and Eosin stains to demonstrate keratin in paraffin embedded tissue sections

Aprajita Srivastava¹, Anil Singh², Kunal Sah³, Vineet Raj⁴, Bhavana Gupta^{5,*}

¹PG Student, ²Professor & HOD, ³Professor, Saraswati Dental College, Lucknow, Uttar Pradesh, ⁴Professor & HOD, Chandra Dental College & Hospital, Lucknow, Uttar Pradesh, ⁵Senior Resident, Dept. of Oral Pathology, King George Medical University, Lucknow, Uttar Pradesh, India

***Corresponding Author:**

Email: drbhavanagupta02@gmail.com

Abstract

Introduction: Keratin is an intermediate protein with a diameter of 7-11 nm which forms the cytoskeleton of all the epithelial cells. It forms the superficial most layer (stratum corneum) in keratinized epithelium in the oral cavity. Keratin may also be present in various pathologic conditions like squamous cell carcinoma, verrucous carcinoma and odontogenic keratocyst. The aim of the present study was to compare and evaluate the efficacy of staining of Ayoub-Shklar, Modified Papanicolaou, Routine Haematoxylin and Eosin and Modified Kreyberg's to stain known keratin tissue, and to obtain the best stain for keratin.

Materials and Method: A total of 75 paraffin embedded tissue blocks were taken of known keratin containing tissue which included Well Differentiated Squamous Cell Carcinoma (WDSCC), Hyperkeratosis with or without dysplasia (HWD), Orthokeratinized Odontogenic Keratocyst (OKC) and Verrucous Carcinoma (VC). Four sections measuring 4 microns in thickness of each block were cut and were stained with all the mentioned stains.

Results: Keratin was stained by all the four stains (Ayoub-Shklar, Modified Papanicolaou, Routine Haematoxylin and Eosin and Modified Kreyberg's) distinctly in WDSCC, HWD, OKC and VC. Ayoub-Shklar and Hematoxylin and Eosin stains showed better results, and was also statistically significant among all the stains for WDSCC, HWD, OKC and VC when intensity and patterns were compared.

Conclusion: It can be concluded that all the four stains (Ayoub-Shklar, Modified Papanicolaou, Routine Haematoxylin and Eosin and Modified Kreyberg's) can demonstrate keratin and based on the overall staining intensity and pattern. Ayoub-Shklar and H and E stains can be used efficiently to stain keratin but have certain limitations.

Keywords: Keratin, Ayoub Shklar stain, Modified Papanicolaou stain, Haematoxylin and Eosin stain, Modified Kreyberg's Stain.

Introduction

Oral epithelium can be classified into two types according to their morphology and pattern of differentiation i.e. keratinized and non-keratinized epithelium.⁽¹⁾ Keratins are the IF-forming proteins which are expressed in all types of epithelial cells. They play an important role in epithelial cell protection from mechanical and non-mechanical stressors. Keratins have been proven to be a useful diagnostic and prognostic marker in epithelial malignancies.⁽²⁾ Keratin can be confirmed by using Schiff's reagent along with various stains such as Kreyberg's method, modified Papanicolaou, and Ayoub-Shklar methods.⁽³⁾

The modified Kreyberg's method involves substitution of alcian green by Alcian blue 8GX and alcoholic saffron is substituted by 2GX and acidified metanil yellow. The results showed keratin stained with red or orange color.⁽⁴⁾

Papanicolaou stain is a routinely used staining technique, commonly available in oral pathology lab. The main use of Orange G6 in Papanicolaou method is to stain keratin. Superficial cells with high content of keratin stain yellow-orange hue and parabasal cells stain green to blue in color.⁽⁵⁾ Elzay et al have reported the modification of PAP stain by adding Phloxine-B, a

red acid dye which is a derivative of fluorescein with distinct bluish shade. It is used to stain keratin, prekeratin and mucin which appears distinct red in color.^(5,6)

Ayoub-Shklar stain is a quick and reliable histological marker to demonstrate the presence/absence and degree of keratinization in the paraffin embedded sections. In this stain, keratin appears distinct red in color. All these special stains to demonstrate keratin have certain advantages and disadvantages. The presence of keratin protein can be detected by immunohistochemistry, but this technique is time consuming and is not economical.⁽³⁾ Hence, the present study was undertaken to demonstrate the efficacy and reliability of Ayoub-Shklar, modified Papanicolaou, routine Haematoxylin and Eosin and modified Kreyberg's method of staining, so that an optimal staining technique which is specific, cost and time effective can be formulated.

Materials and Method

Three groups of keratin containing tissues were obtained for the study and were stained with Ayoub-Shklar, Modified Papanicolaou, Routine Haematoxylin and Eosin and Modified Kreyberg's stain.

The study groups included:

Group A- Well differentiated squamous cell carcinoma (WDSCC) (25 Cases)

Group B- Hyperkeratosis with or without dysplasia (HWD) (25 Cases)

Group C- Miscellaneous (OKC and VC) (25 Cases)

Four sections each of 4 micron thickness from the paraffin embedded tissue were taken and stained with Ayoub Shklar, Modified Papanicolaou, Routine Haematoxylin and Eosin and Modified Kreyberg's stain.

Procedure for Haematoxylin and Eosin: Materials used

Solution: Harris haematoxylin, Acid alcohol, Eosin

Staining Procedure:

- The deparaffinized sections in xylene were dehydrated in various grades of alcohol for 4 minutes each.
- After water wash for 10 minutes, the slides were stained with Harris Haematoxylin stain for 4 minutes.
- Later water washed for 10 minutes and after differentiation in acid alcohol, the slides were dipped under tap water for bluing for 5 minutes and were stained with eosin for 7 sec.

Procedure for Ayoub Shklar stain: Materials used

Solution:

- 5% acid fuschin solution, Acid Fuschin-5gm, Distilled water-100 ml
- Aniline blue orange G solution, Aniline blue (water soluble)-0.5, Orange G-2gm Phosphotungstic acid-1gm, Distilled water-100ml

Staining procedure:

- Deparaffinize sections through 2 changes of xylene, absolute alcohol, and 95% alcohol, to distilled water. Stain sections in acid fuchsin solution for 3 mins.
- Transfer directly to aniline blue-orange G solution for 45 min. Transfer directly to 95% alcohol for several changes. Dehydrate with 2 changes of absolute alcohol. Clear with 2 to 3 changes of xylene and mounted.

Procedure for modified Papanicolaou stain: Materials Used

Solution: Harris hematoxylin, Orange G6, Eosin-azure, Phloxine-B.

Staining Procedure:

- Deparaffinize sections through 2 changes of xylene, absolute alcohol, and 95% alcohol, to distilled water.
- Stain with Harris hematoxylin for 6 min. Two changes of tap water and single dip in acid alcohol, phloxine-B for 5 minute in Distilled water and dehydrate.
- Orange G-6 for 5 min. Rinse in 95% alcohol and then eosin azure for 1 min. Rinse in 90% alcohol, dehydrate. Clear and mount.

Procedure for modified Kreyberg's stain: Materials used

Solution:0.3% Acetic Acid Solution, 1% Alcian Blue Solution, Ammonia-Alcohol Solution, Harris Haematoxylin, Acid Alcohol Solution, 1% Erythrosin B Solution, Alcoholic Metalnil Yellow Solution

Staining Procedure:

- Deparaffinize and dehydrate in distilled water. Place in 3% acetic acid for 3 minutes
- Place in 40 ml of 1% alcian blue solution in a glass Coplin jar and microwave at power level 1 (60W) for 3 minutes. Dip the slides up and down and allow them to remain in the hot solution for 5 minutes. Rinse in three changes of distilled water.
- Place in ammonia-alcohol solution for 10 minutes. Wash well with tap water and rinse in distilled water. Place in Harry's Haematoxylin solution for 45 seconds. Wash with distilled water. Acid alcohol solution for 10 seconds. Rinse in four changes of distilled water.
- Place in erythrosin B solution for 5 minutes. Rinse quickly in one change of distilled water. A few quick dips in two changes of 95% alcohol followed by two changes of absolute alcohol.
- Place in alcoholic metalnil yellow for 30 seconds. Dehydrate with four changes of absolute alcohol. Clear in three or four changes of xylene and mount with synthetic resin.

The results were analyzed for efficacy and pattern of the four staining techniques and examined according to:

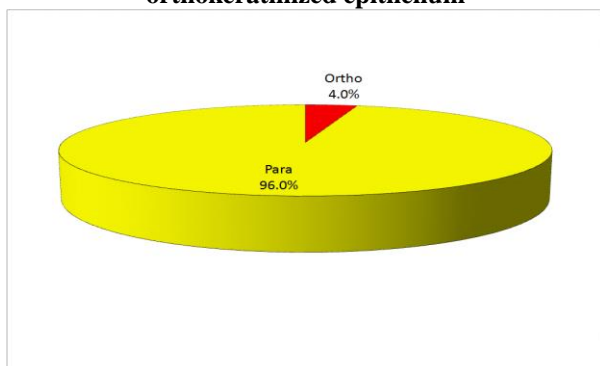
- Type of Surface keratin (parakeratinized or orthokeratinized)
- Pattern of staining (whether good, average or poor).⁽³⁾

Slides were coded and evaluated based on the intensity and pattern as per the modified scoring criteria of Rahma Al-Maaini and Philip Bryant (2008)⁽⁷⁾ (Table 1). The results were statistically analysed using SPSS software (Statistical Package for Social Sciences) Version 15.0 statistical Analysis Software.

Table 1: Criteria and scores for grading different stains in tissue sections

Criteria	Score	
Intensity	0	Poor
	1	Average
	2	Good
	3	Excellent
Pattern	0	Poor
	1	Average
	2	Good
	3	Excellent

Graph 1: Percentage of parakeratinized and orthokeratinized epithelium



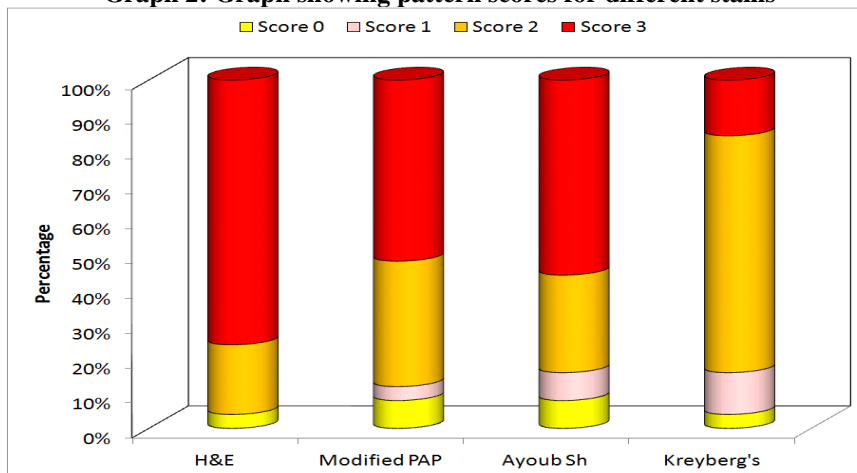
Results

Graph 1 shows the percentage of parakeratinized & orthokeratinized epithelium. Groupwise, comparison for stain pattern showed that the difference between H&E and Modified PAP, H&E and Ayoub Shklar and H&E and Modified Kreyberg’s were statistically significant. It was found that H&E had Pattern scores of significantly higher order as compared to that of Modified PAP, Ayoub-Shklar and Modified Kreyberg’s stain ($p < 0.05$). None of the other differences were significant statistically ($p > 0.05$). On the basis of these results, the order of staining pattern scores for different stains in the present study were as follows: H&E > Modified PAP > Ayoub-Shklar > Modified Kreyberg’s. (Table 2, Graph 2)

Table 2: Frequency table for pattern scores for different stains

Pattern Score	H & E (n=25)		Modified PAP (n=25)		Ayoub Shklar (n=25)		Kreyberg’s (n=25)	
	No.	%	No.	%	No.	%	No.	%
0	1	4	2	8	2	8	1	4
1	0	0	1	4	2	8	3	12
2	5	20	9	36	7	28	17	68
3	19	76	13	52	14	56	4	16
Mean Score±SD	2.68±0.69		2.32±0.90		2.32±0.95		1.96±0.68	
Median Score	3		3		3		2	
Inter-quartile range (IQR)	2.5-3		2-3		2-3		2-3	

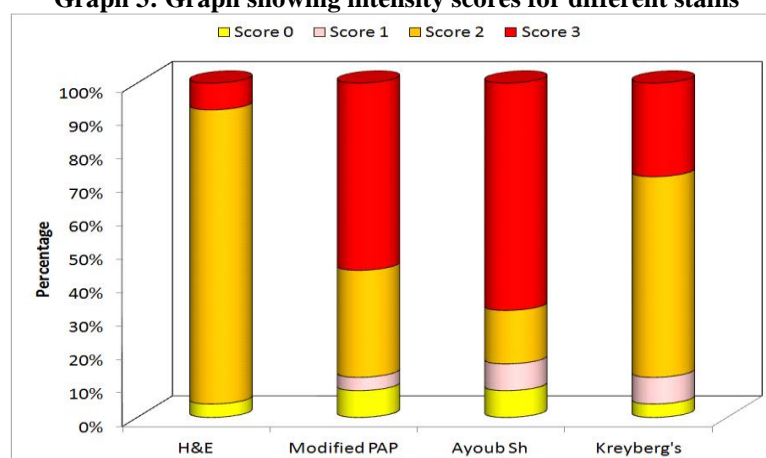
Graph 2: Graph showing pattern scores for different stains



Group wise comparison for stain intensity, except for the difference between H&E and Modified PAP and between H&E and Ayoub-Shklar, none of the differences were found to be significant statistically. It was found that H&E had intensity scores of significantly lower order as compared to that of Modified PAP and Ayoub-Shklar ($p < 0.05$). The order of intensity scores for different stains in the present study were as follows: Ayoub-Shklar > Modified PAP > Modified Kreyberg’s > H&E. (Table 3 and Graph 3)

Table 3: Frequency table for intensity scores for different stains

Intensity Score	H & E (n=25)		Modified PAP (n=25)		Ayoub Shklar (n=25)		Kreyberg's (n=25)	
	No.	%	No.	%	No.	%	No.	%
0	1	4	2	8	2	8	1	4
1	0	0	1	4	2	8	2	8
2	22	88	8	32	4	16	15	60
3	2	8	14	56	17	68	7	28
Mean Score±SD	2.00±0.50		2.36±0.91		2.44±0.96		2.12±0.73	
Median Score	2		3		3		2	
Inter-quartile range (IQR)	2-2		2-3		2-3		2-3	

Graph 3: Graph showing intensity scores for different stains

Group wise comparison for overall visualization, except for the difference between H&E and Modified PAP and H&E and Modified Kreyberg's, none of the differences were found to be significant statistically. It was found that H&E had scores of significantly higher order as compared to that of Modified PAP and Modified Kreyberg's stain ($p < 0.05$). The scores for different stains in the present study were as follows: H&E > Ayoub Shklar > Modified PAP > Modified Kreyberg's. (Table 4, Graph 4)

Table 4: Frequency table for combined scores for different stains

Overall score	H & E (n=25)		Modified PAP (n=25)		Ayoub Shklar (n=25)		Kreyberg's (n=25)	
	No.	%	No.	%	No.	%	No.	%
0	0	0	0	0	0	0	0	0
1	0	0	0	0	0	0	0	0
2	0	0	0	0	2	8.0	4	16.0
3	0	0	5	20.0	3	12.0	2	8.0
4	3	12.0	6	24.0	4	16.0	6	24.0
5	19	76.0	10	40.0	5	20.0	9	36.0
6	3	12.0	4	16.0	6	24.0	4	16.0
Mean Score±SD	5.00±0.50		4.52±1.01		4.60±1.53		4.28±1.31	
Median Score	5		5		5		5	
Inter-quartile range (IQR)	5-5		4-5		3-6		3.5-5	

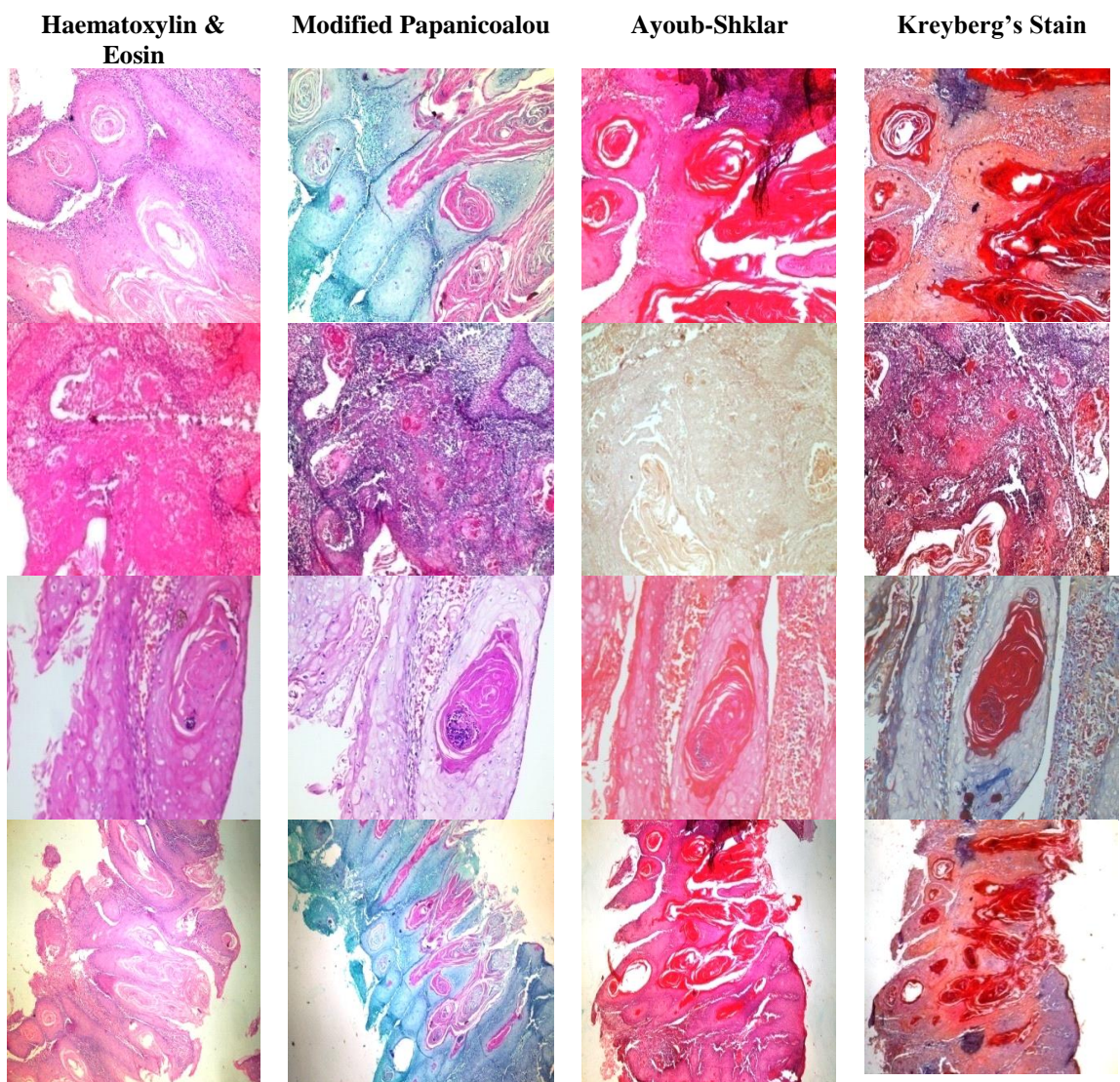
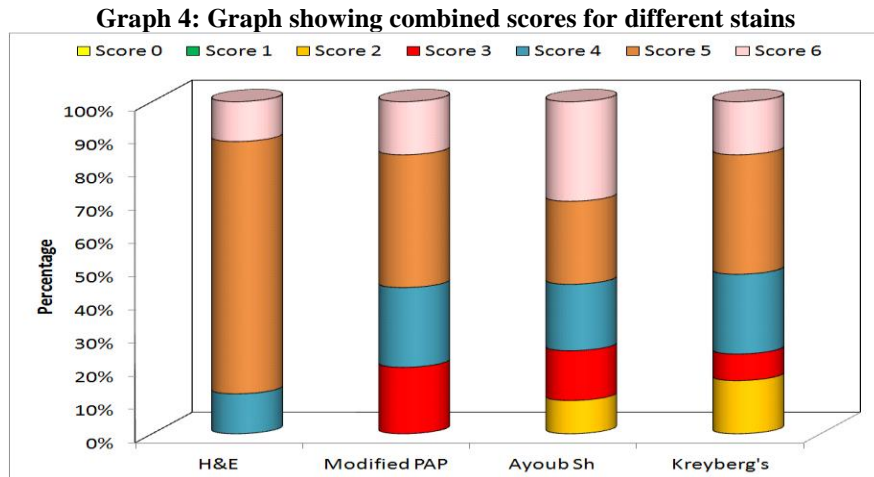


Fig. 1: Keratin pearl staining in 4 tissue sections stained by H&E, Modified Pap, Ayoub Shklar and Kreyberg's Stain. (Pic. 1, 2, 3 X400 and pic 4 X100)

Discussion

Oral mucous membrane can be classified into keratinized epithelium and non keratinized epithelium. The cells of keratinized epithelium undergoes continuous differentiation of cells and form a superficial layer of cornified cells filled with keratin.⁽⁸⁾ Keratin (protein) are intermediate filament with a diameter of 7-11nm and it forms the cytoskeleton of all the epithelial cells.⁽²⁾

Stress can alter keratin expression and makes it structurally reorganized. The reorganization of keratin is regulated by post-translational modification and association of keratin with scaffolding proteins. These changes depends upon the duration and severity of stress. For example, disassembly of network and degradation of K8/K18 occurs in hypoxic conditions. Protein modification occurring during phosphorylation modulates intrinsic properties of keratin like solubility, conformation and filament structure and other post-translational modifications.^(1,8,9) Keratins protect epithelial cell integrity during stressful conditions and it has recently been known as regulator of cellular functions as well as apico-basal polarization, determining cell size.^(10,11)

Given the characteristic cell type, differentiation and functional status-dependent keratin expression patterns in epithelial cells, the availability of specific keratin antibodies, and the fact that epithelial tumors largely maintain the features of specific keratin expression associated with the respective cell type of origin, keratins have long and extensively been used as immunohistochemical markers in diagnostic tumor pathology. Squamous cell carcinomas, independently of their site of origin, are characterized by the expression of the stratified epithelial keratins K5, K14 and K17 and the hyper proliferative keratinocyte-type keratins K6 and K16. In poorly differentiated squamous cell carcinomas, co-expression of the simple epithelial keratins K8, K18 and K19 is often observed. Most adenocarcinomas, consistently express keratinocyte type keratins, notably K5, and vimentin.^(3,12,13) Use of keratins as diagnostic markers in tumor pathology is by far their most common application in the field of cancer. In cases remaining unclear on the basis of clinical presentation and conventional histopathology, including carcinomas that are poorly differentiated or spreading over several organs and metastases of unknown primary tumor site, keratin demonstration is especially valuable for correct tumor.⁽³⁾

All the epithelial tumors contain features of specific keratin association with the respective cell of origin, hence keratins are widely used as immunohistochemical markers in Epithelial tumors have characteristic keratin which is in accordance with the cell of origin. Due to this quality keratin is widely used as immunohistochemical marker identifying tumors. For example, oral squamous cell carcinoma are characterized by K5, K14 and K17 and

hypoproliferative K6 and K16 while in poorly differentiated squamous cell carcinoma K8, K18 and K19 expression. Markers like K5, K14, K17 can characterize squamous cell carcinoma. K6 and K16 which are hypoproliferative can also characterize squamous cell carcinoma. Whereas poorly differentiated squamous cell carcinoma can be detected by K8, K18 and K19 markers is seen. For cases which remain unclear clinically and histopathologically, keratin demonstration proves to be very valuable.⁽³⁾

Special stains are the stains that are used to visualize specific tissues and cellular structures. These are the dyes that bind to the cellular components either physically or by chemical bonds. Ayoub Shklar,⁽¹⁴⁾ Modified Papanicolaou⁽⁵⁾ and Modified Kreyberg's⁽⁴⁾ are special histochemical stains used to stain keratin specifically. These stains may highlight small foci of overt epithelial differentiation that sometimes is missed in routine H&E. These stains, highlights even the minute areas of keratin which can be missed by routine H and E staining.⁽¹⁵⁾

Previous studies done by Rao et al.⁽¹⁵⁾ have shown that Ayoub Shklar method was better than PAP, Dane Herman, Gram's and modified Alcian blue PAS method in terms of staining intensity and equal efficacy in demonstrating type of keratin with all the stains. Ramulu et al.⁽³⁾ have shown that all stains were efficient in staining keratin but Hand E stain was better in demonstration of keratin pearls in oral squamous cell carcinoma cases.

Conclusion

Based on the overall staining intensity & pattern to demonstrate keratin, Ayoub Shklar and H & E stains showed better results. Further studies on larger sample size should be conducted using keratin specific histochemical stains, and should also be further correlated with the keratin type to understand the uneven staining intensity and pattern. To conclude, keratin was well demonstrated by all the four special stains which can be used as a useful adjunct to routine staining methods in demonstrating keratin.

References

1. Nanci A. Ten Cate's Oral Histology: Development, Structure and Function, 8th ed. Philadelphia: Mosby Elsevier; 2013.
2. Karantza V. Keratins in health and cancer: more than mere epithelial cell markers. *Oncogene* 2011;30(2):127-38.
3. Ramulu S, Kale AD, Hallikerimath S, Vijayalaxmi K. Comparing modified Papanicolaou stain with Ayoub-shklar and Haematoxylin-eosin stain for demonstration of keratin in paraffin embedded tissue sections. *J Oral Maxillo Fac Pathol* 2013;17(1):23-30.
4. Churukian CJ, Schenk EA. A Modification of Kreyberg's Method for Demonstrating Keratin and Mucin. *J Histotechnol* 1984;7(3):146-8.
5. Elzay RP. A modification of the Papanicolaou exfoliative cytology stain to demonstrate keratin in paraffin- block

- tissue sections. *Oral Surg Oral Med Oral Pathol* 1983;56(1):51-3.
6. Sheehan D, Hrapchak BB. *Theory and Practice of Histotechnology* 2nd ed. Mosby: St. Louis; 1980.
 7. AI-Maaini R, Bryant P. Honey as an alternative to formalin in the demonstration of connective tissue components. *J Histotechnol* 2008;31(2):67-72.
 8. Kumar GS, Bhaskar SN. *Orban's Oral Histology and Embryology*. 13th ed. Mosby Elsevier: Churchill Livingstone; 2012.
 9. Omary MB, Nam-On Ku, Strnad P, Hanada S. Toward unraveling the complexity of simple epithelial keratins in human disease. *J Clin Invest* 2009;119:1794–805.
 10. Oriolo AS, Wald FA, Ramsauer VP, Salas PJ. Intermediate filaments: a role in epithelial polarity. *Exp Cell Res* 2007;313(10): 2255–64.
 11. Styero ML, Kowalczyk AP. And Victor Faundez. Intermediate Filaments and vesicular Membrane Traffic: The Odd Couple's First Dance? *Traffic* 2005;6(5):359–65.
 12. Hernandez BY, Frierson HF, Moskaluk CA, Li YJ, Clegg L, Cote TR et al. CK20 and CK7 protein expression in colorectal cancer: demonstration of the utility of a population-based tissue microarray. *Hum Pathol* 2005;36(3):275-81.
 13. Yang GC. Ultrafast Papanicolaou Stain. An alternative preparation for fine needle aspiration cytology. *Acta Cytol* 1985;39(1):55-60.
 14. Ayoub P, Shklar GA. Modification of Mallory connective tissue stain as a stain for keratin. *Oral Surg Oral Med Pathol* 1963;16(5):580-1.
 15. Rao RS, Patil S, Majumdar B. Comparison of special stains for keratin with routine Haematoxylin and Eosin Stain. *J Int Oral Health* 2014;6(6):1-5.