

## Threat to implants: Peri- implantitis: A case report

Komal Thakkar<sup>1,\*</sup>, Pinal Patel<sup>2</sup>, Archita Kikani<sup>3</sup>, Mihir Shah<sup>4</sup>

<sup>1,2</sup>PG Student, <sup>3</sup>Professor, <sup>4</sup>Head of Department, <sup>1,3,4</sup>Dept. of Periodontics and Oral Implantology, <sup>2</sup>Dept. of Periodontics, <sup>1,3,4</sup>Ahmedabad Dental College & Hospital, Ahmedabad, Gujarat, <sup>2</sup>Darshan Dental College & Hospital, Udaipur, Rajasthan, India

**\*Corresponding Author:**

Email: thakkar.komal2@gmail.com

### Abstract

The use of dental implants has revolutionized the treatment of partially and fully edentulous patients today. Implants have become a feasible treatment approach for managing a broad range of clinical dilemmas due to their high level of predictability. It promises to sets high hope for patients to 'bite on' along with the best esthetic appearance. However, as every good has a bad along even our peri-implant tissue may develop discomforts due to these foreign bodies or can lose the supportive bone, even in cases of successful osseointegration. Such situation is suggestive of implant failure. One of such reason is 'Peri-implantitis' and probably one of the main causes of implant loss. The term peri-implantitis is described as destructive inflammatory process affecting the soft and hard tissues around osseointegrated implants, leading to the formation of a peri-implant pocket and loss of supporting bone. The current case report elaborates on the introduction, diagnosis of peri-implant diseases and its treatment at peri-implant site after 9 months of implant placement.

**Keywords:** Peri- Implantitis, Peri-Mucositis, Classification of Peri-Implantitis

### Introduction

Dental implants have become an indispensable established therapy in dentistry in order to replace missing teeth in different clinical situations. Scenario of replacing teeth has shifted from denture to the implant placement, for which a number of companies have emerged with economical screws & different implant systems.<sup>(1)</sup> Under care and attention of indications, anatomical and intra-individual limiting factors, insertion of dental implants appears to represent a "safe" treatment option. Nevertheless, in the last decades increasing evidence raised on the presence of peri-implant inflammations representing one of the most frequent complications affecting both the surrounding soft and hard tissues which can lead to the loss of the implant. This could be due to practitioners negligence, improper care by patients and many other reasons leading to implant failure and peri implant tissues irritation.<sup>(2)</sup> The commonly encountered diseases of implants are: peri-implant mucositis and peri-implantitis.

Peri-implant mucositis is a disease that involves inflammatory lesions of the mucosa that surrounds implants, without supporting bone loss.

Peri-implantitis is the destructive inflammatory process affecting the soft and hard tissues surrounding dental implants. The array of periodontal pathogens found around failing implants (those affected by peri-implantitis) are very similar to those found in association with various forms of periodontal disease.<sup>(1)</sup> The clinical signs and symptoms<sup>(2)</sup> of peri-implantitis include inflammation, bleeding on probing, pocket more than 4mm, suppuration and progressive bone loss.

Classification of peri-implantitis was proposed by Froum et al in 2012 (Fig. 1).<sup>(3)</sup>

CLASSIFICATION OF PERIIMPLANTITIS		
EARLY	MODERATE	ADVANCED
<ul style="list-style-type: none"> <li>• PD <math>\geq</math> 4mm</li> <li>• BONE LOSS 25% OF THE IMPLANT LENGTH</li> </ul>	<ul style="list-style-type: none"> <li>• PD <math>\leq</math> 6mm</li> <li>• BONE LOSS 25% TO 50% OF IMPLANT LENGTH</li> </ul>	<ul style="list-style-type: none"> <li>• PD <math>\geq</math> 8mm</li> <li>• BONE LOSS &gt; 8mm</li> </ul>

**Fig. 1: Classification of Peri-implantitis**

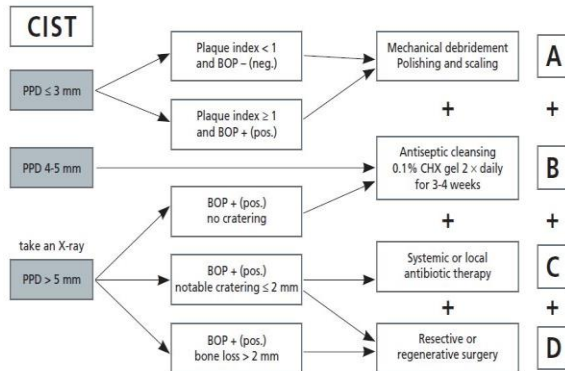
### Management<sup>(4,5)</sup>

The treatment of peri-implant infections comprises conservative (non-surgical) and surgical approaches. Depending on the severity of the peri-implant disease (mucositis, moderate or severe peri-implantitis) a nonsurgical therapy alone might be sufficient or a step-wise approach with a non-surgical therapy followed by a surgical treatment may be necessary. Non-surgical treatment includes mechanical and surgical therapy along with antimicrobials.

The surgical treatments can be done using resective or regenerative approaches. Intervention should be performed if probing depths exceed 5 mm or are progressive as well as under occurrence of local inflammation signs.

Resective surgical therapy may result in re-osseointegration in only minor superficial defects. From functional, esthetic and long-time-survival point of views, full regeneration and re-osseointegration is desirable. Studies have shown that it is possible to regenerate experimentally induced defects using various graft materials and/or resorbable membranes following the principles of guided bone regeneration. Management

of Peri-implantitis has been described by Lang et al (Fig. 2).<sup>(6)</sup>



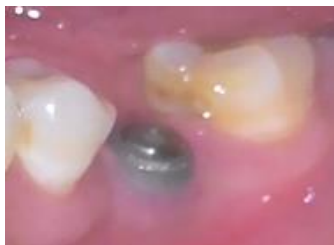**Fig. 2: Management of Peri-implantitis Cumulative Interceptive Supportive Therapy- CIST (Lang et al 2004)**

**Case Report**

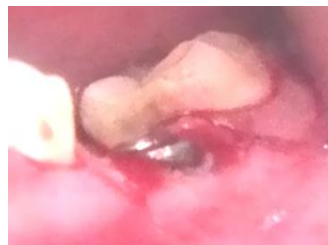A 36 yr old male patient reported to the Dept. of Periodontology with a complaint of pain in lower left back region of jaw since a week. We gathered his medical as well as dental history of implant placement 6 months back. It seemed that patient did not observe any prior discomfort related to the implant site. On

examination implant was found to be at the same site of jaw where patient complained of pain. Probing pocket depth around the implant was 6 mm accompanied by bleeding on probing. It was diagnosed as a case of moderate peri-implantitis.

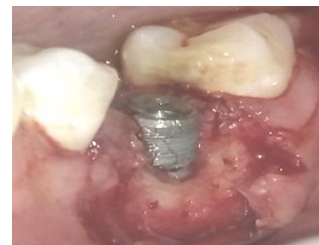**Treatment:** At first all the pre-operative preparations were completed and a surgical intervention was planned, 2% lignocaine with 1:2,00,000 adrenaline was used to anesthetize the surgical site. Initially, crevicular incision was given along with vertical incision, the flap was reflected so is to appreciate the defect site. Along with the thorough debridement at the surgical site, decortication was performed to promoted osteogenesis. The collagen membrane (Healiguide®) was pre-sutured followed by placement of Nova Bone® (Bioactive Bone graft). The site was sutured with non-resorbable silk suture 3/0. The standard post-operative instructions were given to patient and recalled after 7 days for suture removal. On the day of follow up sutures were removed and povidone iodine irrigation was done. At each visit after 20 days, oral hygiene instructions were reinforced. 9 months postoperatively, the crown was given after observing the absence mobility and probing depth. Intra oral radiographs were taken at the 1 day and after 9 months of the surgery for peri-implantitis which showed good bone regeneration. (Fig. 3-11)



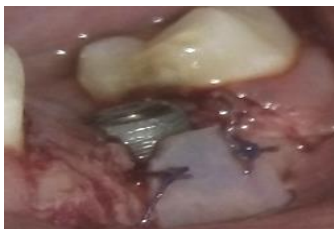**Fig. 3: Preoperative view**



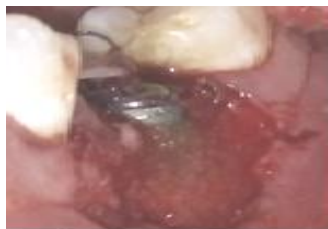**Fig. 4: Incision given at the site**



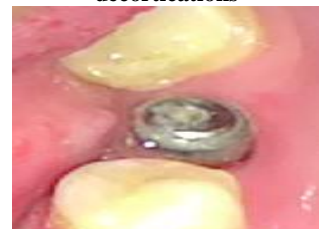**Fig. 5: Flap reflection and decortications**



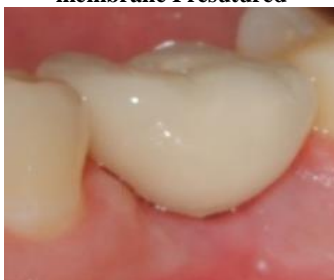**Figure 6: Healiguide Collagen membrane Presutured**



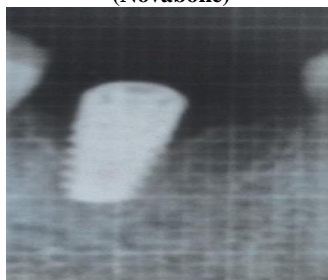
**Figure 7: Bone Graft placed (Novabone)**



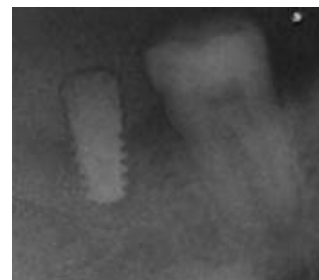
**Figure 8: Post-operative view**



**Figure 9: 9 month follow up**



**Figure 10: Preoperative radiograph**



**Figure 11: Post-operative radiograph**

## Discussion

The mode of treatment differs for both the situations i.e., Peri-implant mucositis and peri-implantitis. According to the literature, it is proved that peri-implant mucositis can be successfully treated if detected at initial to moderate phase.<sup>(7,8)</sup> Non-surgical therapy has not been shown to be effective for the treatment of peri-implantitis.<sup>(9,10)</sup> The surgical treatment proposed for such mucositis have given convincing results. However, longitudinal studies are yet to validate, the treatment modality which may be optimal, given the different clinical scenario. Apart from all surgical modalities, routine monitoring of dental implants act as the essential part of this treatment. Thus, periodontal evaluation and maintenance is mandatory. Moreover, patient's motivation for the oral hygiene care and his positive attitude towards the treatment helps to overcome the peri-implant complications immediately after implant placement.<sup>(11,12)</sup> The updated knowledge of the clinician and his effective handling of implants as well as the tissue increases the chances of implant longevity and decreases the peri implant complications.

## References

- Mombelli A, Lang NP. The diagnosis and treatment of peri-implantitis. *Periodontol 2000* 1998;17:63-76.
- Fransson C, Lekholm U, Jemt T, Berglundh T. Prevalence of subjects with progressive bone loss at implants. *Clin Oral Implants Res* 2005;16:440-6
- Froum SJ, Rosen PS. A proposed classification for periimplantitis. *Int J Periodontics Restorative Dent* 2012;32:533-40.
- Lindhe J, Meyle J. Peri-implant diseases: Consensus report of the Sixth European Workshop on Periodontology. *J Clin Periodontol* 2008;35 (Suppl. 8):282-5.
- Smeets R, Henningsen A, Jung O, Heiland M, Hammächer C, Stein JM. Definition, etiology, prevention and treatment of peri-implantitis – a review. *Head & Face Medicine*. 2014;10:34.
- Lang NP, Berglundh T, Heitz-Mayfield LJ, Pjetursson BE, Salvi GE, Sanz M. Consensus statements and recommended clinical procedures regarding implant survival and complications. *Int J Oral Maxillofac Implants* 2004;19:150-4.
- Sanz M, Chapple IL. Clinical research on peri-implant diseases: Consensus report of Working Group. *J Clin Periodontol* 2012;39(Suppl. 12):202-6.
- Pontoriero R, Tonetti MP, Carnevale G, Mombelli A, Nyman SR, Lang NP. Experimentally induced peri-implant mucositis. A clinical study in humans. *Clin Oral Implants Res* 1994;5:254-9.
- Salvi GE, Aglietta M, Eick S, Sculean A, Lang NP, Ramseier CA. Reversibility of experimental peri-implant mucositis compared with experimental gingivitis in humans. *Clin Oral Implants Res* 2012;23:182-90.
- Charalampakis G, Leonhardt A Rabe P, Dahlen G. Clinical and microbiological characteristics of periimplantitis cases: A retrospective multicenter study. *Clin Oral Implants Res* 2012;23:1045-54.
- Faggion CM Jr, Chambrone L, Listl S, Tu YK. Network meta-analysis for evaluating interventions in implant dentistry: The case of peri-implantitis treatment. *Clin Implant Dent Relat Res* 2013;15(4):576-88.
- Roos-Jansaker AM, Lindahl C, Persson GR, Renvert S. Long-term stability of surgical bone regenerative procedures of peri-implantitis lesions in a prospective case-control study over 3 years. *J Clin Periodontol* 2011;38(6):590-7.