

Retrospective study of primary extranodal abdominal lymphoma from a tertiary healthcare centre

Kajal R Parikh^{1,*}, Sanjay V Dhotre², Mahesh Patel³, Hitendra Barot⁴, Amit Satasiya⁵

¹Tutor-Resident, ²Associate Professor, ³Additional Professor, ⁴Assistant Professor, ⁵Tutor Dept. of Pathology, B J Medical College, Ahmedabad, Gujarat

***Corresponding Author:**

Email: kajalparikh1@gmail.com

Abstract

Introduction: The aim of this study is to describe histomorphological and clinical features of primary extranodal abdominal lymphoma involving GI tract and spleen at pathology department, civil hospital, Ahmedabad and to compare our results to those reported in literature.

Materials and Method: Sixteen patients with primary extranodal abdominal lymphomas diagnosed over a period of two years were retrospectively studied histopathologically.

Results: Out of 16 cases, 14 cases had Non-Hodgkin's lymphoma of intestine and two cases had primary splenic Non-Hodgkin's lymphoma. There were 13 males and 03 females, with median age of 48 years. The majority of cases had intestinal lymphoma. High grade lymphoma accounted for 42%.

Conclusion: The current study showed that primary extra nodal abdominal lymphomas occurs in 4th to 6th decades with male preponderance. Small intestine is the predominant site and diffuse large B cell type being the commonest histologic variant.

Keywords: Primary extranodal abdominal lymphoma, GI tract, Spleen, Histomorphology.

Introduction

Most Non-Hodgkin's lymphomas arise in lymph nodes, although 25-40% of NHL patients presents with a primary extranodal lymphoma. The gastrointestinal tract is the predominant site of extranodal Non-Hodgkin's lymphoma. It accounts for about one third of all primary extranodal NHLs but only 1 to 4% of malignancies arising in the GI tract.⁽¹⁾ Despite their rarity, primary NHLs of GI tract are important since their epidemiologic features, staging, histological classification and management are distinct from that of primary extranodal lymphoma. Primary splenic lymphoma is rare accounting for less than 1% of lymphoid malignancy.⁽²⁾ Even though splenic involvement is common in lymphoid malignancies, isolated splenic involvement as the presenting feature of lymphoma is rare.⁽³⁾ The aim of this study is to analyse the clinicopathological features of primary extranodal abdominal lymphoma involving GI tract and Spleen.

Materials and Method

A total of 16 cases of patients with primary GI lymphoma and primary splenic lymphoma diagnosed at Pathology department, Civil hospital, Ahmedabad over a period of two years (August 2015 to August 2017) were studied retrospectively. Medical records of all patients were reviewed and clinical and pathological information were recorded.

Tissue sections were obtained from formalin fixed paraffin embedded blocks and stained with hematoxylin and eosin. Special stains such as Periodic Acid-Schiff and reticulin stain were used in selected cases. Each biopsy was investigated immunohistochemically by

staining for Leucocyte common antigen (LCA), CD 20, CD 3, Keratin and EMA. Histopathological classification was done using the current REAL/WHO classification.

Results

From the August 2015 to August 2017, 16 patients with primary extranodal Non-Hodgkin's lymphoma involving GI tract and spleen were included in the study. Out of 16 cases, 14 cases had Non-Hodgkin's lymphoma of intestine and two cases had primary splenic Non-Hodgkin's lymphoma. There were 13 (76.5%) males and 03(23.5%) females, with median age of 48 years. The male to female ratio was 3:1. The distribution of patients in various age groups is shown in Table 1. Three patients (18.75%) were below 20 years of age. The largest number of patients was between the ages of 40 and 60 years. The distribution of lymphoma among various sites in abdomen is depicted and compared with different studies in Table 2. The majority of cases had intestinal lymphoma. Various histological patterns encountered are presented and compared with a study in Table 3. The commonest morphological appearance was of diffuse large B cell lymphoma seen in 43.75% of cases.

Table 1: Age distribution extranodal abdominal lymphomas

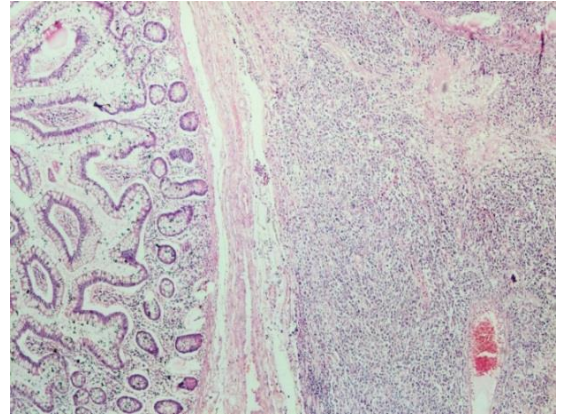
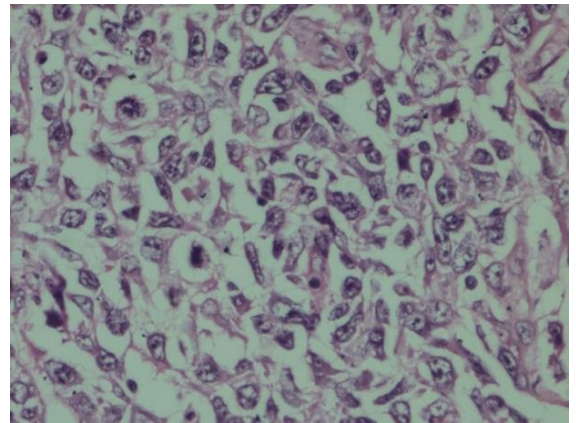
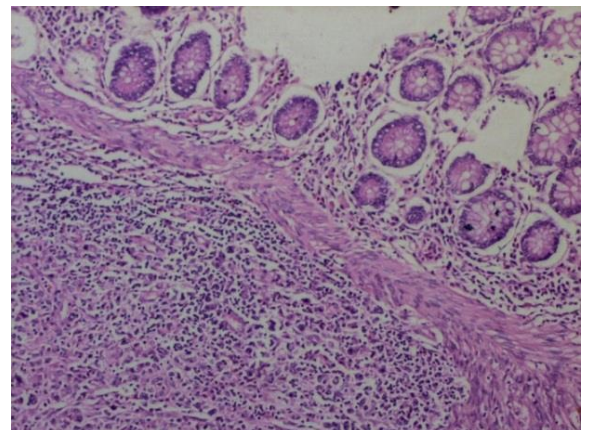
Age in years	No. of Patients	% of Total
0-20	03	18.75
21-40	03	18.75
41-60	07	43.75
61-80	03	18.75
Total	16	100%

Table 2: Site distribution of extra nodal abdominal lymphomas

Site	Authors		
	A.H.Nagi et al ⁽¹⁴⁾	Shirsat HS et al ⁽¹⁵⁾	Present study
Oesophagus	01	01	--
	2.13%	1.23%	--
Stomach	21	40	--
	44.68%	49.38%	--
Small Intestine	12	22	09
	25.53%	27.19%	56.25%
Gastro-ileal	05	--	--
	10.64%	--	--
Caecum	--	02	01
	--	2.46%	6.25%
Ileocaecum	--	03	
	--	3.70%	
Colon	08	04	04
	17.02%	4.93%	25%
Spleen	--	--	02
	--	--	12.5%
Multiple sites	--	09	
	--	11.11%	
Total	47	81	16
	100%	100%	100%

Table 3: Histological pattern of extranodal abdominal lymphoma

Histological Type	Authors		
	A.H.Nagi et al ⁽¹⁴⁾	Shirsat HS et al ⁽¹⁵⁾	Present study
Small cell – Diffuse	07	01	04
	14.89%	1.23%	25%
Large cell – Diffuse	14	21	07
	29.79%	25.95%	43.75%
Mixed Small and Large cell	04	--	03
	8.51%	--	18.75%
MALT type	22	48	01
	46.81%	59.25%	6.25%
Marginal Zone	--	--	01
	--	--	6.25%
T cell lymphoma	--	09	--
	--	11.11%	--
IPSID	--	02	--
	--	2.46%	--
Total	47	81	16
	100%	100%	100%

**Fig. 1: H & E staining, Diffuse proliferation of neoplastic lymphocytes in submucosa of colon in Diffuse large B cell lymphoma****Fig. 2: H&E staining 40x, Large cells with vesicular nuclei, prominent nucleoli and many mitotic figures in Diffuse large B cell lymphoma****Fig. 3: H&E staining, Presence of mixed population of neoplastic lymphocytes in submucosa of cecum**

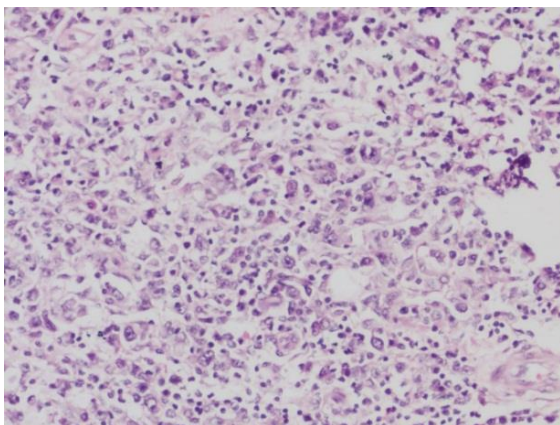


Fig. 4: H&E staining 40x shows presence of large as well as small lymphocytes in Non-Hodgkin's Lymphoma - Mixed cellularity type

Discussion

The gastrointestinal tract is the most frequent location for primary extranodal Non-Hodgkin's lymphomas.^(6,7) However primary NHLs of GIT accounts for only 1-4% of GI malignancies.⁽¹⁾ Small intestinal lymphomas account for 20% to 40% of primary gut lymphomas in Western populations, and they are among the most common malignant tumors of the small intestine.^(8,9) Primary colorectal lymphomas are uncommon accounting for only 0.2% of large intestinal malignancies and 10 to 15% of primary GI lymphomas.^(10,11) Our study also showed majority of extra nodal lymphomas involving small intestine (56.25%) followed by colon (25%). Primary splenic lymphoma is a rare entity accounting for less than 1% of lymphoid malignancies.⁽²⁾ PSLs constitute a heterogeneous group of diseases with wide variations in clinical presentations and lymphoid population from which they originate. The PSLs include splenic marginal zone lymphoma, hairy cell leukemia, hairy cell variant, splenic diffuse large cell lymphoma, lymphoplasmacytic lymphoma, primary splenic follicular lymphoma, B and T- prolymphocytic leukemia, large granular lymphocytic leukemia and hepatosplenic T- cell lymphoma.⁽¹²⁾ In our study two cases of primary splenic lymphomas diagnosed with histomorphology of splenic marginal zone lymphoma and diffuse large B cell lymphoma. In this study of extra nodal abdominal lymphoma, male to female ratio was 3:1. The peak age at presentation was between 4th to 6th decades which is different from western studies where the peak age incidence appear to be in 7th decade.^(13,14) Anatomical localization in our study suggested that majority of patients had small intestinal lymphoma (56.25%) followed by large intestine (25%) which is different from other studies in which stomach was the predominant involved site. The most common histological pattern of these lymphomas was diffuse large cell type while in other studies MALT type was the commonest histological type.^(4,5,14-16) However,

Radic-Kristo et al.⁽¹⁷⁾ reported much higher incidence of Diffuse Large B Cell Lymphoma in 71% cases similar to our study.

Conclusion

The current study showed that primary extra nodal abdominal lymphomas occurs in 4th to 6th decades with male preponderance. Small intestine is the predominant site and diffuse large B cell type being the commonest histologic variant.

References

1. Loehr WJ, Mujahed Z, Zahn FD, Gray GF, Thorbjarnarson B. Primary lymphoma of the gastrointestinal tract: A review of 100 cases. *Ann Surg* 1969;170:232-8.
2. Rosai and Ackerman's surgical pathology, 10th edition, volume 2, page no.1908-1911.
3. Koiso H, Yokohama A, Mitsui T, Saitoh T, Handa H, Murakami H, et al. Follicular lymphoma presenting with marked splenomegaly: Report of three cases. *Acta Haematol* 2012;128:47-52.
4. A.H.Nagi, M.Ayuband L.A.Menawy. Primary Non-Hodgkin's lymphomas of gastro-intestinal tract- A clinicopathological study. *E:/Biomedica Vol.22 Jul. - Dec.2006/Bio-18.84-87.*
5. Shirsat HS, Vaiphei K. Primary gastrointestinal lymphomas- A study of 81 cases from a Tertiary Healthcare Centre. *Indian journal of cancer/July-September2014/Volume 51/Issue 3;290-292.*
6. Mushtaq S, Mamoon N, Ahmad S. Primary gastric lymphoma in Northern Pakistan, *Pak. J. Path.* 2001; 12 (4):18-24.
7. Brodova V. MALT / Monocytoid lymphoma. <http://www.geocities.com/-verab/mlt/malt.html>.2005
8. Gascoynar D, Muller-Hermelink HK, Chott A, et al. B cell lymphoma of the small intestine. In Hamilton SR, Aaltonen LA, eds. *WHO classification of Tumors, Pathology and Genetics: Tumors of the Digestive System*. Lyon, France: IARC Press, 2000:83-86.
9. Domizio P, Owen RA, Shepherd NA, et al. Primary lymphoma of the small intestine: a clinicopathological study of 119 cases. *Am J Surg Pathol* 1993;17:429-442.
10. Muller-Hermelink HK, Chott A, Coyne RD, et al. B cell lymphoma of the colon and rectum. In Hamilton SR, Aaltonen LA, eds. *WHO classification of Tumors, Pathology and Genetics: Tumors of the Digestive System*. Lyon, France: IARC Press, 2000:83-86.
11. Shepherd NA, Hall PA, Coates PJ, et al. Primary malignant lymphoma of the colon and rectum: a histopathological and immunohistochemical analysis of 45 cases with clinicopathological correlations. *Histopathology* 1988;12:235-252.
12. Iannitto E, Tripodo C. How I diagnose and treat splenic lymphomas. *Blood* 2011;117:2585-95.
13. W Lewin KJ, Ranchod M, Dorfman RF. Lymphomas of the gastro intestinal tract, a study of 117 cases presenting with gastro intestinal disease. *Cancer*, 1978;42: 693
14. Farinha P, Gascoyne R.D. Molecular Pathogenesis of Mucosa associated lymphoid tissue lymphoma. *J.Clin Onco*, 2005; Vol. 23, No. 26:6370-6378.
15. Cogliatti SB; Schmid V, Schmacher U. Primary B cell gastric lymphoma. A clinicopathological study of 145 patients. *Gastroenterology*, 1991;101:1159.
16. Grathlein s, Perez J. A. MALT lymphoma; the clinical background. *E medicine. Com/med/topic 3204.htm*.2005.

17. Radić-Kristo D, Planinc-Peraica A, Ostojić S, Vrhovac R, Kardum Skelin I, Jasic B. Primary Gastrointestinal non-Hodgkin Lymphoma in Adults. Clinicopathologic and Survival Characteristics. Coll Antropol 2010;34:413-7.