

Analysis of effect of trabeculectomy in adult primary open angle glaucoma patients using spectral domain optical coherence tomography in Indian population

Udayaditya Mukhopadhyay¹, Nabanita Barua^{2,*}, Sangeeta Thakur³

¹Associate Professor, ²Clinical Tutor, ³Post Graduate Trainee, Dept. of Ophthalmology, ¹North Bengal Medical College, Siliguri
²Nil Ratan Sircar Medical College, Kolkata, ³Regional Institute of Ophthalmology, Kolkata

***Corresponding Author:**

Email: nabanita_br@yahoo.co.in

Abstract

Purpose: To evaluate the change in retinal nerve fiber layer thickness (RNFL) using Optical Coherence Tomography after trabeculectomy in adult patients with primary open angle glaucoma (POAG).

Methods: A total of 40 eyes (30 patients) with POAG, uncontrolled on medical management were enrolled. Average and quadrant wise RNFL thickness were measured pre and post operatively at 1 week, 1 and 3 months. Data was analysed using SPSS software.

Results: Intraocular pressure (IOP) reduced from 28.55+ 8.47 mm Hg, 14.8+ 5.97 mm Hg at 1 week, 14.25 + 4.47 mm Hg at 1 month, 14.9 +4.8 mm Hg at 3 months (p<0.0001)). There was no statistically significant change in RNFL level noted at 1 or 3 months (p=0.1847). Visual function (MD and PSD) also remained unchanged. RNFL thickness had significant negative correlation with age, IOP and pattern standard deviation. We divided the patients in two groups < 50 years and >50 years and analyzed the data but no statistically significant changes were found.

Conclusion: In this study, post glaucoma filtration surgery, there was significant lowering of IOP but no difference in RNFL thickness, visual field parameters in adult POAG patients.

Keywords: Optical coherence tomography, Trabeculectomy, RNFL thickness variation.

Introduction

Glaucoma is second most common cause of blindness worldwide. Glaucoma affects more than 67million person world- wide, of whom about 10 % or 6.6 million, are estimated to be blind.⁽¹⁾ The incidence of Primary open angle glaucoma was estimated at 2.4 million persons per year. In India 12.8% of total blindness are reported to occur due to glaucoma.⁽²⁾

Lamina cribrosa is the site postulated to be effected in glaucoma in mechanical theory. Backward bowing of lamina due to increased intraocular pressure (IOP) causes injury to the nerve fiber layer passing through this. So theoretically, relieving pressure at this site can reverse changes at the optic disc.^(3,4) Such an reversal has been documented well in literature in the context of congenital and juvenile glaucoma.⁽⁵⁻⁸⁾ In adult patients the findings are conflicting, factors affecting are the stage of disease, the amount of IOP reduction, and the age of the patient.^(9,10)

Spectral domain OCT can image early structural damages in glaucoma. We get cross –section view of ONH rather than enface view provided by other imaging device Heidelberg retinal tomography (HRT).⁽¹⁰⁻¹³⁾ The study aims to evaluate changes in RNFL thickness using spectral domain OCT in Trabeculectomy patients before & after surgery in order to demonstrate any structural improvement following IOP reduction in adult patients.

Materials and Methods

The study obtained approval from the Institute Ethics Committee, and followed the principles of the

Declaration of Helsinki. Informed consent was obtained from all the enrolled individuals. It is prospective interventional study with 40 eyes of 30 adult patients (>18 years) with medically uncontrolled glaucoma requiring surgical treatment presenting to the Glaucoma Clinic of a tertiary care eye hospital from January 2014 to August 2015 (18 Months).

Inclusion Criteria:

Patient selection criteria are: Primary Open angle glaucoma in patients >18 years of age with unsatisfactory IOP control on maximum tolerable anti-glaucoma medications, who were scheduled for glaucoma-filtering surgery, were enrolled for the study.

Diagnosis of primary open angle glaucoma by: An IOP > 21 mm of Hg, glaucomatous optic nerve damage (asymmetric cup disc ratio> 0.2), rim thinning, notching, excavation or RNFL defect), an open anterior chamber angle and consecutive reliable characteristic visual field loss on SAP (white on white 24-2: SITA standard) with abnormal glaucomatous hemi-field defect, pattern standard deviation one side 95% of normal limit. Reliable visual field test (<25% fixation loss, <20% false positive, <20% false negative).

Exclusion Criteria: Following patients were excluded from the study: subjects with a previous history of intraocular surgery/ laser therapy, clinically detectable media opacity precluding view of second-order retinal vessels (corneal edema, cataract), secondary glaucoma (trauma, uveitis), any posterior segment pathology that interferes with OCT analysis such as diabetic retinopathy, age related macular degeneration, cystoid macular oedema, macular dystrophy, central serous

retinopathy), unable to undergo the procedure under local anaesthesia.

Each subject will have a detailed history determine profile, exposure to the risk factors of glaucoma, ocular trauma, past treatment for glaucoma. Comprehensive ophthalmic examination including best-corrected visual acuity (BCVA) recorded as LOGMAR values with and without correction, IOP measured by Goldmann Applanation tonometry, slit lamp biomicroscopy, gonioscopy and stereoscopic fundus evaluation on the slit lamp using a 90.0-D lens. Preoperatively RNFL thickness was measured within 2 weeks using spectral domain OCT.

Postoperative visual acuity, IOP, slit lamp biomicroscopy, and disc evaluation will be done at week 1, 1 month, and then 3 months postoperatively. Post op visual acuity, slit lamp biomicroscopy done on day 1. Postoperatively RNFL thickness was measured at 1 week, 1 month and 3 month using spectral domain OCT. Visual field preoperative within 2 weeks & postoperative 1 week, 1month & 3 months was assessed.

The OCT images analysed with the in-built Spectral domain OCT. Commercial SD-OCT (Cirrus HD-OCT; Carl Zeiss Meditec; software version: 3.0) acquires a volumetric data set and uses software to detect the ONH margin automatically on the OCT fundus image and calculate the geometric centre of a given ONH. Then, it resamples the 3D OCT data to generate a virtual 3.4 mm circular scan mimicking the conventional peripapillary OCT scan in order to maintain backward data comparability. With this fully automated RNFL thickness measurement method, the previously mentioned image registration limitation due to eye motion should be reduced. The RNFL parameters studied were average RNFL thickness and RNFL thickness in each of four quadrants defined as superior (46–135°), nasal (136–225°), inferior (226–315°), and temporal (316–45°).

Visual field examination (Automated perimetry): An automated visual field (Humphrey Field Analyzer 24-2 program) analysis was done in proper scheduled. All subjects underwent SITA standard 24-2 perimetry (Carl Zeiss Meditec Inc., Dublin, California, USA). A reliable visual field test was defined as one with fewer than 20% fixation losses, false positive or false negatives.

A field defect was defined by Anderson criteria as having 3 or more significant ($p < 0.05$) non-contiguous points with at least one at the $p < 0.01$ level on the same side of the horizontal meridian in the pattern standard deviation plot, classified as outside normal limit in the glaucoma Hemifield test (GHT) and confirmed in two consecutive tests.

The patients were classified in 3 subgroups: early, moderate and severe.

Early glaucoma was defined by Visual field loss with $MD < 6$ dB

Moderate glaucoma MD 6-12 dB

Severe glaucoma > 12 dB.

In all patients' global indices MD , PSD were calculated.

Surgical Technique

Trabeculectomy surgery can be performed under local or general anesthesia. A bridge suture (passed underneath the superior rectus muscle) or preferably traction suture (placed partial thickness through the peripheral clear cornea) is often used for adequate exposure of the surgical site (superior quadrants of the eye). A conjunctival peritomy is created to expose the superior bare sclera (limbal/ fornix based). After gentle cautery, a partial thickness triangular/ rectangular scleral flap is created in the superior sclera, hinged at the limbus. The scleral flap is dissected forward until the bluish gray zone is exposed. A paracentesis is created in the peripheral clear cornea prior to creating an full thickness sclerostomy. A blade is first used to enter the anterior chamber from just behind the hinge of the scleral flap. The entrance into the anterior chamber is then enlarged using the blade, vannas scissors, and/or a Kelly punch. A peripheral iridectomy is created at this point. Interrupted sutures (usually 9-0 or 10-0 nylon) are then used to close the scleral flap. In few cases releasable sutures was placed. The conjunctival peritomy is then closed using absorbable or nylon sutures.

Mitomycin C (MMC): in 6 cases intra-operative MMC was used in a dose of 0.02-0.04%. The drug is available in a vial (2mg/ml). It is further reconstituted with normal saline (5ml) to make 0.4mg/ml or in 10ml to make 0.2mg/ml. Mitomycin-C (MMC). After peritomy and achieving hemostasis, merocel sponge soaked in the desired concentration is kept for 1-5 minutes subconjunctivally. It is then thoroughly washed with balanced salt solution

Statistical analysis

For statistical analysis data were entered into a Microsoft excel spreadsheet and then analysed by SPSS IBM (Version 19.0. Armonk, NY) was used for statistical analysis (MedCalc software version 12.2.10, Ostend, Belgium) and GraphPad Prism version 5. Data have been summarized as mean and standard deviation. Student's independent sample's t-test was applied to compare normally distributed numerical variables between groups, Unpaired proportions were compared by Chi-square test or Fischer's exact test.

Results

Total number of eyes in this study was 40. Eyes from the subjects were randomly chosen from the patients attending OPD and Glaucoma clinic during the period January 2014 to August 2015 as per the study protocol. Forty eyes of 30 open angle glaucoma patients were taken in this study; 34 eyes underwent trabeculectomy, 6 eyes underwent trabeculectomy with

intraoperative application of mitomycin c. The mean age of patients was 51.50±9.33 years with range 38.00-70.00 years and the median age was 49.00 years. The population was age and sex matched. Table 1 summarizes IOP difference in different group. IOP reduction in our study in overall is from

28.55±8.47mmHg to 14.90±4.8 mm Hg (p<0.0001). In Trabeculectomy group & combined Trabeculectomy with MMC group the IOP reduction was from 28.82±8.40 mmHg to 15.17±5.11 mmHg and 27.00±9.52mmHg to 13.33±2.06 mmHg respectively (P<0.0001 & P=0.0002 respectively).

Table 1: Comparison of IOP Pre-op& postop 1 week, 1 month and 3 months follow-up

		Number	Mean	Std. Dev.	Minimum	Maximum	Median
Total	Pre-op	40	28.5500	8.4730	14.0000	54.0000	26.0000
	1 Week	40	14.8000	5.9709	8.0000	34.0000	14.0000
	1 Months	40	14.2500	4.6746	8.0000	28.0000	12.0000
	3 Months	40	14.9000	4.8741	8.0000	28.0000	14.0000
TRAB	Pre-op	34	28.8235	8.4008	14.0000	54.0000	26.0000
	1 Week	34	15.0000	6.3485	8.0000	34.0000	14.0000
	1 Months	34	14.4706	4.9497	8.0000	28.0000	12.0000
	3 Months	34	15.1765	5.1196	8.0000	28.0000	14.0000
TRAB with MMC	Pre-op	6	27.0000	9.5289	20.0000	42.0000	22.0000
	1 Week	6	13.6667	3.2042	10.0000	18.0000	14.0000
	1 Months	6	13.0000	1.6733	12.0000	16.0000	12.0000
	3 Months	6	13.3333	2.0656	10.0000	16.0000	14.0000

Table 2 summarizes the mean peripapillary RNFL thickness as measured by the OCT for the different surgical group and a significant increase in RNFL thickness was found for the overall measurement & in all quadrants. The RNFL thickness change (mean±SD) was 51.04±17.41 µm for overall RNFL in both trabeculectomy & trabeculectomy with MMC group (P=0.1847). We observed a mean overall RNFL thickness increase in 29 (72.5%) of 40 eyes & mean RNFL thickness decrease in 11 (27.5%) of 40 eyes. But the overall RNFL thickness was increased (9.08±3.50 µm) but not statistically significant (p=0.1847).

Table 2: Comparison of Average RNFL in Pre-op& postoperative 1 week, 1 month and 3 months follow-up

		Number	Mean	Std. Dev.	Minimum	Maximum	Median
Total	Pre-op	40	51.0495	17.4188	26.7500	100.5000	48.0000
	1 Week	40	59.6913	22.7230	32.0800	123.0000	55.7950
	1 Months	40	58.6375	23.7086	5.0000	115.7500	54.8750
	3 Months	40	60.2625	20.9168	34.2500	112.0000	55.6250
TRAB	Pre-op	34	50.4276	17.9324	26.7500	100.5000	47.1600
	1 Week	34	60.1291	23.9967	32.0800	123.0000	54.6900
	1 Months	34	59.0882	25.2838	5.0000	115.7500	54.8750
	3 Months	34	60.5956	22.1622	34.2500	112.0000	54.5000
TRAB with MMC	Pre-op	6	54.5733	15.0582	35.5000	78.0000	55.1200
	1 Week	6	57.2100	14.7706	.0000	78.0000	58.3900
	1 Months	6	56.0833	12.4887	41.5000	73.5000	53.8750
	3 Months	6	58.3750	12.8800	45.5000	80.0000	56.2500

Table 3, image 1, 2 and 3 summarizes nasal, superior, inferior and temporal RNFL in different groups and results were statistically not significant (p values are 0.2489, 0.2410, 0.2595, 0.3365 respectively, all <0.05).

Table: 3 Comparison of nasal quadrant RNFL thickness in Pre-op & postoperative 1 week, 1 month and 3 months follow-up

	Number	Mean	Std. Dev.	Minimum	Maximum	Median
Pre-op	40	47.3250	18.5090	9.0000	90.0000	48.5000
1 Week	40	53.5500	19.7652	9.0000	104.0000	54.0000
1 Months	40	54.7750	19.6853	11.0000	98.0000	56.0000
3 Months	40	55.2000	20.2538	11.0000	120.0000	56.0000

We have sub-divided the patients in < 50 years and > 50 years and analysed the values after 1 months. Table 4 summarizes the mean RNFL thickness measurements after dividing the patients into two groups on the basis of age. In younger patients (< 50 years) a significant increase in the RNFL thickness was found in both age groups with significant reduction of intraocular pressure. The mean IOP & mean RNFL changes were from 21.88±11.16 mm Hg to 13.88± 5.44 mm Hg & 57.96±18.05µm to 60.17±18.37µm respectively (p=0.0002, p=0.6077) in patients aged < 50 years.

Table 4: Comparison of IOP and average RNFL values in Pre-operative and 1 month in <50 and >50 years patients

IOP (<50 y)	Number	Mean	Std. Dev.	Minimum	Maximum	Median	p-value
Pre-op	18	21.8889	11.1606	10.0000	54.0000	21.0000	0.0002
1 Months	18	13.8889	5.4499	8.0000	34.0000	12.0000	
RNFL (<50 y)							p-value
Pre-op	18	57.9600	18.0520	31.6900	108.2500	54.1400	0.6077
1 Months	18	60.1739	18.3780	36.0000	112.0000	55.6250	
PSD (<50 y)							p-value
Pre-op	8	8.5974	3.2348	4.9100	11.4000	8.3600	0.3480
1 Months	8	4.8000	2.4593	4.2800	5.3200	4.8350	
> 50 yrs IOP:							p-value
Pre-op	22	21.0000	8.8239	8.0000	48.0000	21.0000	0.0008
1 Months	22	15.6364	5.2699	8.0000	28.0000	14.0000	
RNFL avg							p-value
Pre-op	22	52.2936	23.0597	5.0000	115.7500	45.1250	0.1400
1 Months	22	59.8157	24.2960	32.0800	123.0000	55.1050	
PSD							p-value
Pre-op	14	6.6300	3.2348	2.1600	13.8000	9.3600	0.2460
1 Months	14	4.8000	2.4593	3.6000	11.3200	5.8350	

In older patients, a significant increase in the RNFL thickness was found in both age groups with significant reduction of intraocular pressure. The mean IOP & mean RNFL changes were from 21.00 ±8.82 mm Hg to 15.63 ±5.26 mm Hg & 52.29±23.05µm to 59.81 ±24.29 µm respectively (p=0. 0.0008,P=0.0008) in patients aged ≥50 years There was no significant PSD changes seen.

Table 5 demonstrates Average RNFL is negatively co-related to age, IOP, PSD (all p< 0.05).

Table 5: Correlation of average RNFL according to age, IOP, MD and PSD

Factors	r-value	p-value	Remarks
Age	-0.45	0.0492	Significant
IOP	-0.49	0.0023	Significant
MD	0.56	<0.0001	Significant
PSD	-0.58	<0.0001	Significant

Comparison of superior quadrant RNFL Thickness in Pre-op & Post-op 1 week, 1 month

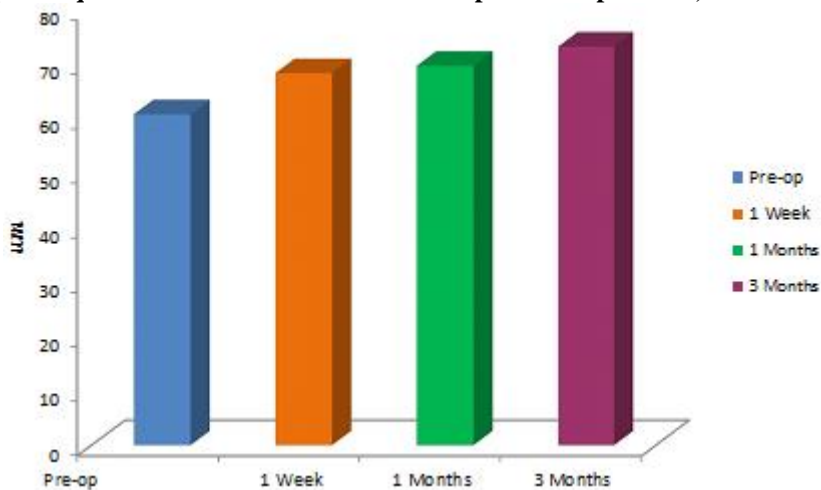


Fig. 1: Superior RNFL variation pre op and 1 week, 1 month and 3 month post op

Comparison of inferior quadrant RNFL Thickness in Pre-op & Post-op 1 week, 1 month and 3 months follow-up

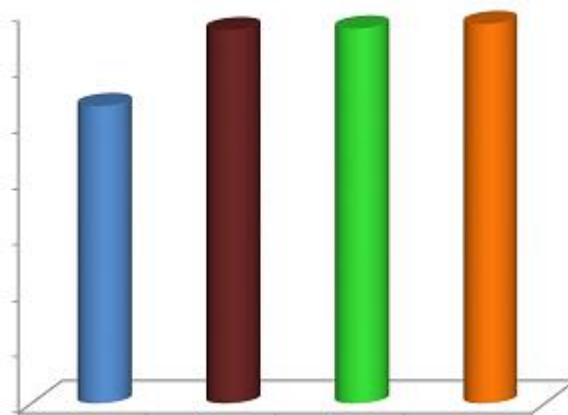


Fig. 2: Inferior RNFL variation pre op and 1 week, 1 month and 3 month post op

Comparison of temporal quadrant RNFL Thickness in Pre-op & Post-op 1 week, 1 month and 3 months follow-up

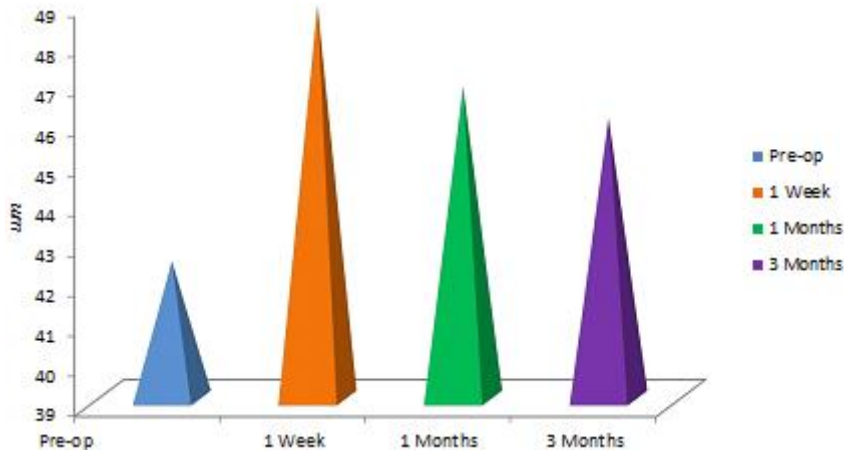


Fig. 3: Temporal RNFL variation pre op and 1 week, 1 month and 3 month post op

Discussion

Lamina cribrosa, in case of glaucoma, produces ischemia of retinal nerve fibre layer by posterior bowing and subsequently compression of neurons.^(3,4) Previous studies have shown in less advance cases both fundus and visual field analysis can improve when IOP is lowered.^(13,14) These changes are well documented in congenital and infantile glaucoma.⁽⁵⁻⁸⁾ Serial documentation with disc photography, OCT analysis, HRT etc can detect early changes.

In this study, we have used SD-OCT for imaging. It is highly producible, fast and gives cross-sectional analysis of lamina cribrosa. We have found no significant difference of RNFL (in all quadrants) at 1 month and 3 month interval, though IOP changed significantly pre and post-surgery. Several studies have shown immediate increase in RNFL value.⁽¹⁷⁻²³⁾ In few studies, these change reverted back to normal on long term follow-up.⁽¹⁶⁾ The changes are explained on the basis of change in anatomical structure rather than true/permanent reversal of cupping. In the setting of lower IOP lamina cribrosa comes back to previous level. Another explanation can be retinal swelling from acute reduction of IOP post-operatively.^(3,4,16)

IOP reduction in our study in overall is from 28.55 ± 8.47 mmHg to 14.90 ± 4.8 mm Hg ($p < 0.0001$). In Trabeculectomy group & combined Trabeculectomy with MMC group the IOP reduction was from 28.82 ± 8.40 mmHg to 15.17 ± 5.11 mmHg and 27.00 ± 9.52 mmHg to 13.33 ± 2.06 mmHg respectively ($P < 0.0001$ & $P = 0.0002$ respectively).

The IOP reduction in previous study was (49.9±16.8%) in Irak et al⁽²³⁾ and Topouzis et al⁽¹⁹⁾ (43.8%±29.9% and 49.3±14.9%, respectively). The difference can be explained on the basis of difference in study population. We had POAG population in all stages, where both had moderate glaucoma (MD -9.9 ± 8.4 dB).^(18,19) These studies along with others have proved the earlier the stage of glaucoma, the more likely it is that reversal of cupping may occur.^(24,25) Mean MD values in our study -13.96 ± 7.88 dB, post-operatively at 3 months 10.61 ± 5.48 ; difference statistically not significant ($p = 0.2192$).

Our study showed average RNFL to be significantly negatively co-related with age, IOP and PSD. RNFL thickness change following IOP reduction has also inconsistent results. Chang et al used scanning laser polarimetry and found a significant increase in RNFL thickness 3–6 months following trabeculectomy, but with no correlation with IOP.⁽²⁴⁾ Using newer machines, Koraszewska et al also reported no change in RNFL thickness in juvenile glaucoma patients following trabeculectomy.⁽²⁵⁾ Their result is same as our study finding.

The Raghu et al study in advanced glaucoma shows that the RNFL thickness increases and cup area decreases for a transient period after glaucoma surgery

but reverts back to preoperative values within 3 months. They reported disc and RNFL changes appear to be irreversible, and lowering IOP substantially does not appear to result in any structural improvement in the ONH or peripapillary RNFL parameters.⁽¹⁶⁾ In our study, no change has been documented.

Our study shows in adult patients with POAG who are medically uncontrolled, surgery could achieve lower IOP targets but structural changes didn't change. We have found correlation between average RNFL and age, IOP, MD and PSD but IOP lowering is not associated with improvement in structural and functional parameters. We analyzed the findings in sub groups (age wise: < 50 years and > 50 years and post-operative time: 1 month and 3 months) but study findings were similar.

Limitations of the study: small sample size, subsequent follow up, and long-term study was essential to assess clinical significance of changes. More elderly patients and advanced glaucomatous damage of patients were included in this study, and this hinders the generalization in a specific group of patients.

References

1. Quigley HA, Broman AT, "The number of people with glaucoma worldwide in 2010 and 2020" Br J Ophthalmology (2006)90,262-7.
2. Garway-Heath DF, Poinoosawmy D, Fitzke FW, Hitchings RA, "Mapping the visual field to the optic disc in normal tension glaucoma eyes" Ophthalmology (2000)107:1809-15.
3. Emery JM, Landis D, Paton D, Boniuk M, Craig JM, "The lamina cribrosa in normal and glaucomatous human eyes" Trans Am Acad Ophthalmol Otolaryngology (1974)78:290-7.
4. Quigley HA, Addicks EM, Green WR, Maumenee AE, "Optic nerve damage in human glaucoma. II. The site of injury and susceptibility to damage" Arch Ophthalmology (1981),635-49.
5. Meirelles SH, Mathias CR, Bloise RR, Stohler NS, Liporaci SD, Frota AC, "Evaluation of the factors associated with the reversal of the disc cupping after surgical treatment of childhood glaucoma" J Glaucoma (2008)17,470-3.
6. Yasuda M, Ando A, Otsuji T, Fukui C, Matsumura M, "Improvement of the topographic parameters of the optic discs after trabeculotomy in two patients with developmental glaucoma" Eye (2006)20,132-134.
7. Leung CK, Woo J, Tsang MK, Tse KK, "Structural and functional recovery in juvenile open angle glaucoma after trabeculectomy" Journal of Pediatric Ophthalmology and Strabismus (2009) 46, 372-5.
8. Wu SC, Huang SC, Kuo CL, Lin KK, Lin SM, "Reversal of optic disc cupping after trabeculotomy in primary congenital glaucoma" Canadian Journal of Ophthalmology (2002),37:337-41.
9. Garway-Heath DF, "Optic disc assessment in primary open angle glaucoma" Community Eye Health (1996)9,25-8.
10. Sommer A, Enger C, Witt K, "Screening for glaucomatous visual field loss with automated threshold perimetry" American Journal of Ophthalmology (1987)103,681-4.

11. Medeiros FA, Zangwill LM, Bowd C, Vessani RM, Susanna R, Weinreb RN, " Evaluation of retinal nerve fiber layer, optic nerve head, and macular thickness measurements for glaucoma detection using optical coherence tomography" *American Journal of Ophthalmology* (2005),139:44–55.
12. Wollstein G, Ishikawa H, Wang J, Beaton SA, Schuman JS, "Comparison of three optical coherence tomography scanning areas for detection of glaucomatous damage" *American Journal of Ophthalmology* (2005)139,39–43.
13. Leung CK, Chan WM, Hui YL, Yung WH, Woo J, Tsang MK, et al, " Analysis of retinal nerve fiber layer and optic nerve head in glaucoma with different reference plane offsets, using optical coherence tomography" *Invest Ophthalmology Visual Science* (2005)46,891–899.
14. Tsai CS, Shin DN, Wan JY, Zeiter JH," Visual field global indices in patients with reversal of glaucomatous cupping after intraocular pressure reduction" *Ophthalmology* (1991)98,1412–19.
15. Katz LJ, Spaeth GL, Cantor LB, Poryzees EM, Steinmann WC," Reversible optic disc cupping and visual field improvement in adults with glaucoma". *American Journal of Ophthalmology* (1989)107:485–92.
16. Raghu N, Pandav SS, Kaushik S, Ichhpujani P, Gupta A, "Effect of trabeculectomy on RNFL thickness and optic disc parameters using optical coherence tomography" *Eye (Lond)* (2012)26,1131–7.
17. Lesk MR, Spaeth GL, Azuara-Blanco A, Araujo SV, Katz LJ, Terebuh AK, et al " Reversal of optic disc cupping after glaucoma surgery analyzed with a scanning laser tomography" *Ophthalmology*(1999)106,1013–8.
18. Kotecha A, Siriwardena D, Fitzke FW, Hitchings RA, Khaw PT, "Optic disc changes following trabeculectomy: Longitudinal and localisation of change" *British Journal of Ophthalmology*(2001)85,956–61.
19. Topouzis F, Peng F, Kotas-Neumann R, Garcia R, Sanguinet J, Yu F, et al, "Longitudinal changes in optic disc topography of adult patients after trabeculectomy" *Ophthalmology*(1999)106,1147–51.
20. Shirakashi M, Nanba K, Iwata K, "Reversal of cupping in experimental glaucoma" *Ophthalmologica*(1991)202,194–201.
21. Coleman AL, Quigley HA, Vitale S, Dunkelberger G. Displacement of the optic nerve head by acute changes in intraocular pressure in monkey eyes. *Ophthalmology*. 1991;98:35–40. [PubMed]
22. Quigley HA. The pathogenesis of reversible cupping in congenital glaucoma. *Am J Ophthalmol*.1977;84:358–70. [PubMed]
23. Irak I, Zangwill L, Garden V, Shakiba S, Weinreb RN. Change in optic disk topography after trabeculectomy. *Am J Ophthalmol*. 1996;122:690–5. [PubMed]
24. Chang PT, Sekhon N, Budenz DL, Feuer WJ, Park PW, Anderson DR, " Effect of lowering intraocular pressure on optical coherence tomography measurement of peripapillary retinal nerve fiber layer thickness" *Ophthalmology*(2007)114,2252–8.
25. Koraszewska-Matuszewska B, Samochowiec-Donocik E, "Evaluation of retinal nerve fiber layer thickness in eyes with juvenile glaucoma after trabeculectomy" *Klin Oczna*. (2004)106,443–4.[PubMed]