

A study of variations of the triceps brachii muscle in north Karnataka population

Pratik Khona¹, Ashwini C^{2,*}

^{1,2}Assistant Professor, Dept. of Anatomy, Gadag Institute of Medical Sciences, Gadag, Karnataka

***Corresponding Author:**

Email: meashumbbs@gmail.com

Abstract

Introduction: Triceps brachii muscle is the only muscle of posterior compartment of arm, consisting of three heads—long, lateral and medial. Radial nerve and profunda brachii artery run in the radial groove that separate lateral and medial head. Triceps brachii is a site for intramuscular injections. Evolutionarily triceps has many sub heads which have either fused or disappeared. Therefore, the knowledge of muscle is essential anthropologically and clinically and this study aims to study the anatomical variations of triceps brachii muscle.

Materials & Methods: In the present study, 60 upper limbs from the Department of Anatomy, Belagavi Institute of Medical Sciences, Belagavi and Gadag Institute of Medical Sciences, Gadag were examined for the variations of triceps brachii muscle during routine dissections of undergraduate students. The variations found were neatly dissected and photographs taken wherever necessary.

Result: Out of 60 upper limbs dissected 2 specimens presented with variations of triceps muscle.

Discussion: Both variations seen were fourth head of origin of muscle seen in two different male cadavers in respectively right and left arm. The variations present were seen only unilaterally in both cadavers. The details of these variations will be discussed in the article.

Conclusion: The variations of triceps brachii muscles are mentioned in literature, but are uncommon and if tendinous fourth head are present over the neurovascular bundles they may lead to compression syndrome. Hence the radiologists, surgeons and orthopedicians have to watch out for these while dealing with posterior compartment of arm.

Keywords: Triceps Brachii, Radial Nerve, Profunda brachii artery, Compression syndrome, Fourth head of triceps.

Introduction

Triceps brachii is a muscle of extensor compartment of the arm. It fills the compartment and arises by three heads (long, lateral and medial), from which it takes its name. The long head arises by a flattened tendon from the infra-glenoid tubercle of the scapula, blending above with the glen humeral capsule, the lateral head arises by a flattened tendon from a narrow, linear, oblique ridge on the posterior surface of the humeral shaft above the radial groove and the medial head takes its origin from entire posterior surface of the humeral shaft below the radial groove. From the middle of the muscle the tendon of triceps begins. It has two laminae, one superficial (in the lower half of the muscle) and the other in its substance. The two layers unite above the elbow after receiving the muscle fibers and are attached, for the most part, to the upper surface of the olecranon. On the lateral side a band of fibers continues down over anconeus to blend with antibrachial fascia.⁽¹⁾ Each fascicle has its own motor neuron sub-nucleus in the motor column in the spinal cord. The medial head is formed mainly by small type I fibers and motor units, the lateral head by large type II b fibers and motor units and the long head is a mixture of fiber types and motor units. It has been suggested that each fascicle "may be considered an independent muscle with specific functional roles."⁽²⁾ All three heads of the triceps brachii are classically believed to be innervated by the radial nerve.⁽³⁾ However, the long head may be innervated by a branch of the axillary nerve.⁽⁴⁾ It has been suggested that the

long head fascicle is employed when sustained force generation is demanded, or when there is a need for a synergistic control of the shoulder and elbow or both. The lateral head is used for movements requiring occasional high-intensity force, while the medial fascicle enables more precise, low-force movements.⁽²⁾ In humans, the Anconeus is sometimes loosely called "the fourth head of the triceps brachii".⁽⁵⁾ Although variations of triceps brachii muscle are relatively less common, they have been at times reported by various authors. Hence this study was undertaken to study variations in morphology of triceps brachii muscle in North Karnataka region and findings were compared with previously found variations by different authors and the possible embryological and comparative anatomical basis for the same has been discussed.

Materials and Methods

In the present study, 60 upper limbs from the Department of Anatomy, Belagavi Institute of Medical Sciences, Belagavi and Gadag Institute of Medical Sciences, Gadag were examined for the variations of triceps brachii muscle during routine dissections of undergraduate students. The posterior compartment of arm was dissected according to the Cunningham manual 1st volume. Any variations in the morphology of triceps like extra heads, absence of any head, abnormal nerve supply were noted. The variations whenever found were neatly dissected and photographs were taken wherever necessary.

Results

Among 60 upper limbs studied we found the variations of triceps brachii muscle in 2 upper limbs of two different male cadavers as shown in table 1.

In the one of the right upper limb of male cadaver a single tendon originating from posteromedial aspect of upper part of the shaft of humerus close to surgical neck above the radial groove was seen. The tendon was running over the neurovascular bundle, containing radial nerve and profunda brachii artery. Length of the tendon was about 8 cm. the tendon continued as muscle belly which was measuring 6 cm long and was joining the medial head of triceps. The fourth head received its nerve supply through a separate branch from the branch of radial nerve supplying medial head of triceps (Fig. 1).

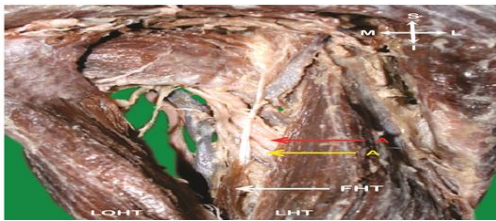


Fig. 1: Showing the Fourth head of triceps with its relations in right upper limb (A-Radial Nerve & Profunda Brachii Artery, LHT- Lateral Head of Triceps, LOHT- Long Head of Triceps, FHT- Fourth Head of Triceps)

Another variation seen was also a case the fourth head but it was taking its origin from the posterior part of the capsule of the shoulder joint just above the surgical neck of the humerus, and lateral to the long head of the muscle. The muscle belly then descended inferomedially and joined with the long head just before it formed the common tendon with the lateral head of the triceps. The fourth head was muscular throughout and no tendon was found (Fig. 2). The muscle belly was measuring 9.5 cms. It received its nerve supply from a separate branch from the branch of radial nerve supplying the long head. The axillary nerve and the posterior circumflex humeral vessels traversed between the long and the fourth head and the muscle belly of fourth head crossed above the profunda brachii artery and radial nerve in the radial groove. No other variations were found on both the upper limbs.




Fig. 2: Showing the Fourth head of triceps with its relations (A-Axillary Nerve & Post Circumflex Humeral Artery, B-Communicating artery, C-Radial Nerve & Profunda Brachii Artery, LHT- Lateral Head of Triceps, LOHT- Long Head of Triceps, FHT- Fourth Head of Triceps)

Discussion

Triceps brachii muscle show many variations. Each of the heads may be fused, in varying degrees, with neighboring muscles. The fibers of the long head may extend to the capsule of the shoulder joint above or distally, for a greater extent than usual on the axillary border of the scapula. Macalister described the variations of triceps brachii as follows: It may have a fourth head from the medial part of the humerus below the head, by a long, slender tendon, and by an aponeurotic expansion from the capsule of the shoulder – this head blended with the inner (medial) head; Macalister has frequently seen the long head split, one attached to the capsule, and the other to the tricipital spine, axillary border, or the first slip was found splitting the capsular ligament, like the curved head of rectus femoris; The existence of a slip from the tendon of latissimus dorsi has been seen several times. It was described by Bergman in 1855; and it was also mentioned by Halbertsma under the name of anconeus quintus; this may occasionally come from the teres major.⁽⁶⁾

A fourth head of triceps may arise from different points on the humerus, scapula, shoulder joint capsule or the coracoid process.⁽⁷⁾ Fabrizio and Clemente demonstrated a single tendon arising from the proximal posteromedial aspect of the shaft of humerus, distal to the shoulder capsule. The tendon of this fourth head passed along the medial aspect of the humerus and gave way to a muscle belly on the medial surface of the distal one-third of the humerus.⁽⁸⁾ Ipsilateral four-headed triceps brachii muscle was found by Tubbs et al. They reported an additional attachment site of the medial head of the triceps brachii. This head originated from the posterior aspect of the surgical neck of the humerus.⁽⁹⁾ Cheema and Singla also found extra head of triceps brachii muscle originating from humerus from the medial side of surgical neck of humerus, the muscle belly of extra head was blending with the long head of triceps brachii muscle.⁽¹⁰⁾ R Kulkarni, R. N. Kulkarni and S Solan found the fourth head of triceps brachii was arising from the upper part of the posterior aspect of the shaft of the humerus immediately below the capsule of the shoulder joint and from the upper part of the oblique line along with lateral head of triceps brachii. The origin was by a long tendon which extended on the medial aspect of arm after crossing the radial nerve and profunda brachii vessels superficially along with the lateral head of triceps brachii. In the lower one third of the posterior aspect of the arm the tendon continued as muscular belly which merged with the medial part of medial head of triceps brachii.⁽¹¹⁾ P Sonje, P Vatsalaswamy and V Arole found a single tendon which was seen being attached to the posteromedial aspect of upper part of the shaft of humerus close to surgical neck above radial groove and was running close to medial side of the shaft of humerus over the neurovascular bundle, containing radial nerve and

profunda brachii artery and its muscle belly was merging with the medial head of triceps brachii.⁽¹²⁾

The first indication of limb musculature was observed in the seventh week of development as a condensation of mesenchyme near the base of the limb buds embryologically. Similar to other regions, connective tissue dictates the pattern of muscle formation. With elongation of the limb buds, the muscle tissue divides into flexor and extensor components. As soon as the buds form, ventral primary rami from the appropriate spinal nerves penetrate into the mesenchyme. Immediately after the nerves have entered the limb buds, they establish an intimate contact with the differentiating mesodermal condensations.⁽¹³⁾ The triceps muscle is derived from the extensor component and may be that during this period the accessory muscles must have formed. Or otherwise as in the variations in the present study neurovascular bundles might have separated the fourth head from the medial head and long head of triceps brachii respectively.

When we look into Comparative anatomy, the triceps brachii muscle in carnivores is bulky and is made up of many sub heads of the muscle:

- Long head has – anterior and posterior parts. Branches of the profunda brachii artery and vein pass out between these two parts
- Medial head has – small- intermediate and long heads.
- Lateral head

The components of Medial head those are, the long head, separable from the triceps lateralis only for a very short distance after its origin, which is from a triangular area on the posterior surface of the shaft of the humerus, beginning at the lip of the articular surface, the most superficial fibers arising from the joint capsule and the intermediate head, it takes a tendinous origin from a short line on the postero-medial edge of the shaft of the humerus, immediately beneath and behind the insertion of the latissimus tendon.⁽¹⁴⁾ According to this the present cases in the study may be non-fusion of these to heads during evolution.

Table 1: Shows the distribution of specimens

Total No. of Upper limbs Studied	No. of Upper limbs with normal triceps muscle	No. of Upper limbs with Fourth head of triceps muscle	No. of Upper limbs with other variations of triceps muscle
60	58	02	NIL

Conclusion

The fourth head of the triceps brachii muscle may be seen due to the following probable causes

- While differentiation of the musculature if there is any connective tissue or neurovascular bundle interfering in its development

- Fusion or disappearance of the sub heads of the three heads of the triceps brachii muscle is not completed.

In the present study as the muscle belly is being supplied by the branch from the radial nerve supplying the medial head in first case and the branch of radial nerve supplying the long head in second, we would suggest it to be the evolutionary cause of persistence of sub head in the first case and embryological reason of neurovascular bundle interfering the development in the second case as the communicating artery separate the fourth head from long head. If the fourth head is tendinous as in the first case then it passing over the neurovascular bundle can cause compression of the same in strenuous exercise and work like weightlifting. Hence knowing such variations for surgeons, radiologists and anatomists becomes necessary.

References

1. Williams P. L., Warwick R., Dyson M., Bannister L. H., Gray's Anatomy, 39th Ed., New York, Churchill Livingstone, 2005, 615–616.
2. Lucas-Osma, AM; Collazos-Castro, JE. "Compartmentalization in the triceps brachii motoneuron nucleus and its relation to muscle architecture". J Comp Neurol 2009, 516 (3), 226–39.
3. Bekler H, Wolfe VM, Rosenwasser MP "A Cadaveric Study of Ulnar Nerve Innervation of the Medial Head of Triceps Brachii". Clinical Orthopaedic Related Research, 2009, 467(1), 235–238.
4. de Se`ze MP, Rezzouk J, de Se`ze M, Uzel M, Lavignolle B, Midy D, Durandean A. "Does the motor branch of the long head of the triceps brachii arise from the radial nerve?" Surgical Radiological Anatomy 2004, 26 (6), 459–461.
5. Sawant S P. Study of variant heads of triceps muscle with its developmental basis. IJAPBS 2013, 2(2), 23–26.
6. Bergman RA, Afifi AK, Miyauchi R. Illustrated Encyclopedia of Human Anatomic Variation: Opus I: Muscular System : Alphabetical Listing of Muscles: T, Triceps Brachii. <http://www.anatomyatlases.org/AnatomicVariants/MuscularSystem/Text/T/47Triceps.shtml> (assessed may 2017)
7. Anson BJ. Morris' Human Anatomy. 12th Ed., New York, McGraw-Hill. 1966; 482–484.
8. Fabrizio PA, Clemente FR. Variation in the triceps brachii muscle: a fourth muscular head. Clinical Anatomy. 1997; 10: 259–263.
9. R. Shane Tubbs, E. George Salter and W. Jerry Oakes. Triceps brachii muscle demonstrating of fourth head. Clinical anatomy: 2006; 19[7]: 657–666.
10. Cheema P, Singla R. Four headed triceps brachii muscle. International Journal of Anatomical Variations (IJAV). 2011; 4: 43–44.
11. Kulkarni R, Kulkarni RN, Solan S. Unilateral right quadriceps brachii – a case report. Anatomica Karnataka. 2012; 6: 15–17.
12. Sonje P, Vatsalawamy P, Arole V. Fourth head of triceps brachii muscle – a case report. International Journal of Anatomical Variations (IJAV). 2013; 6: 167–169.
13. Langman J. Medical Embryology. 2nd Ed., Baltimore, Williams and Wilkins, 1969, 143–146.
14. D. Dwight Davis. The shoulder architecture of Bears and other carnivores. Chicago Natural History Museum: 1949; 31[16]: 34.