

Desquamative gingivitis – A nonspecific clinicopathological entity

Nilotpol Kashyap¹, Brij Kumar^{2,*}, Kangkan Roy³, Mukesh Kashyap⁴

¹Professor & HOD, ²Senior Lecturer, ^{3,4}PG Student, ^{1,2,3}Dept. of Pedodontics and Preventive Dentistry, ⁴Dept. of Oral & Maxillofacial Surgery, Raipur, Chhattisgarh

***Corresponding Author:**

Email: brij220787@gmail.com

Abstract

To explain a unique case of Desquamativegingivitis, this has a nonspecific clinicopathological appearance which was treated with antioxidant and a systemic and topical corticosteroid application. A fifty year old woman reported with Desquamative gingivitis with peeling of mucosa and generalized erythematous gingiva involving maxillary anterior region and left buccal mucosa which was histopathologically diagnosed as nonspecific infection and treated with systemic and topical steroid, antioxidant and 2% betadine gargling.

Desquamative gingivitis is a nonspecific infection and can be successfully managed with systemic and topical corticosteroid and antioxidant with the periodic follow up. We discuss the clinical and histopathological features and management of the disease.

Keywords: Desquamative gingivitis, Nonspecific infection, Corticosteroid.

Introduction

Desquamative gingivitis is an abnormal condition portrayed by extraordinary erythema, desquamation and ulceration of free and attached gingiva. It is not a particular disease, yet a gingival reaction showed by an assortment of clinical disease elements. Lichen planus, pemphigus, pemphigoid, erythema multiforme and lupus erythematosus are a few of the diseases which clinically show as desquamative gingivitis.⁽¹⁾ of these diseases, lichen planus is a generally regular issue influencing the skin and mucous layers.⁽²⁾ These sores of oral lichen planus (OLP) have unmistakable morphology. Hereditary or immune system variables, medications and chemicals, contamination and psychogenic impact/stress have all been recommended as predisposing elements.⁽³⁾ Desquamative gingivitis is accepted to be a clinical indication of certain mucocutaneous disease as opposed to a particular pathologic element.⁽⁴⁾ A precise conclusion of the fundamental disease of endless desquamative gingivitis can be made on the premise of watchful history and clinical perception, light microscopic examination of gingival biopsy examples, and immunopathologic investigation outcomes. The hugeness of early analysis in the remedial administration of the patients is accentuated. The reaction to topical corticosteroids and also systemic corticosteroids like dapsone or sulfapyridine has been satisfying. The recognizable proof of the basic sickness in chronic desquamative gingivitis is imperative and the commitment of the dental practitioner in early analysis and brief restorative consideration is necessary.⁽⁵⁾

The clinical conclusion might be hard to build up. In a few cases critical gingival signs are seen as changes not related to bacterial dental plaque, while in other circumstances the presentation might be more treacherous - with gentle central erythematous. As a further origin of diagnostic vulnerability, the injuries found in

the aforementioned mucocutaneous diseases are at first fundamentally the same as, and then grows unrecognizable and difficult to separate upon ulcerating. In such situations histological, hematological and immunohistological studies are required to build up the conclusion and characterize a sufficient treatment technique.⁽⁶⁾

I. Case Report

A 50 year old woman of Indian origin reported to the outpatient department of a dental college and hospital. She complained of bleeding gums during brushing and burning sensation in gum region which worsened on intake of spicy food since two months. No significant medical and family history and no past dental history were present. Patient had no significant habits.

On general physical examination patient was co-operative and comfortable in chair. Patient was well-built and well nourished. No signs of pallor, icterus, cyanosis & edema.

On extra-oral examination face was apparently symmetrical. Temporomandibular joint was bilaterally well synchronized, coordinated movements were present. Lymph nodes were non-palpable and non-tender. No sinus or fistula was evident.

On intra-oral examination there was a peeling of mucosa and erythematous gingival involving maxillary anterior region and left buccal mucosa. Patient gave history of vesicles formation which ruptured to form ulceration and erosions. (Fig. 1a)

The region is tender on palpation and spontaneous bleeding present on the maxillary anterior gingiva and left buccal mucosa. (Fig. 1b) (Fig. 1aFig.1b)

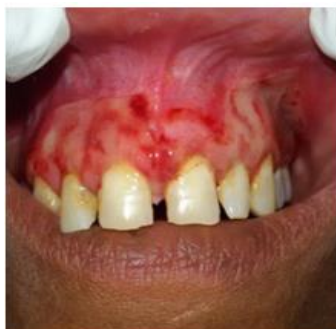

Fig. 1a

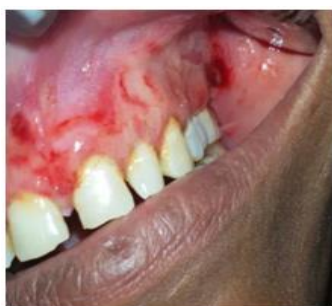

Fig. 1b

Fig. 1a & 1b: Pretreatment - peeling of mucosa and erythematous gingiva in the anterior maxillary region & left buccal mucosa.

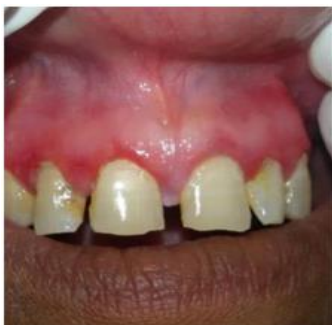

Fig. 1c

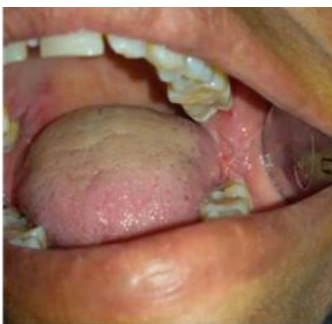

Fig. 1d

Fig. 1c
Fig. 1d
Fig. 1c & 1d: - Posttreatment – There is a complete cure of the lesion.

Provisional diagnosis was given as desquamative gingivitis. Patient was advised for random blood sugar test and exfoliative cytology and incisional biopsy were performed.

On report of RBS was 102.0mg/dl.

Hematoxylin and eosin sections of biopsy specimen revealed in scanner view connective tissue stroma. Low power view revealed connective tissue stroma with moderate to dense and diffuse chronic inflammatory infiltrate, bundles of collagen fibers interspersed with fibroblasts and endothelial lined vascular spaces of varying size and shape.

High power view confirms features of connective tissue stroma composed of collagen fibers and fibroblasts, chronic inflammatory infiltrate chiefly composed of lymphocytes and plasma cells. Overall features are suggestive of Nonspecific infection.(Fig. 2)

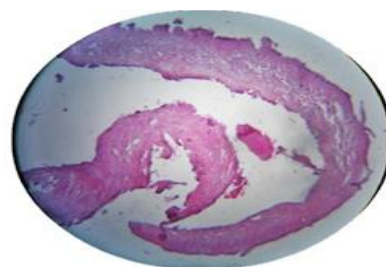


Fig. 2

Fig. 2: Biopsy specimen revealing connective tissue stroma composed of collagen fibers, fibroblasts and chronic inflammatory cell infiltration composed of lymphocytes and plasma cells suggestive of nonspecific infection(X10).

The patient was advised topical use of high potency steroid (clobetasole propionate) thrice daily for one month, antioxidant (lycopene) once daily for one month and oral rinse with betadine 2% gargling for 7 days. Patient was recalled four times in a 7 days interval and on fourth appointment the lesion was healed totally. (Fig. 1c, Fig. 1d). The patient was asked to stop the topical steroid application and reinforcement of oral hygiene instructions were given. Since the lesions may recur, the patient was under observation for 1 year and there was no recurrence.

II. Discussion

Chronic desquamative gingivitis was initially reported in 1894 by Tomes and Tomes however the term was popularized by Prinz in 1932.^(7,8) Initially, a hormonal derangement was suspected to be the cause of desquamative gingivitis, however later McCarthy et al suggested that desquamative gingivitis was not a specific disease entity but represented a gingival response to a variety of mucocutaneous disorders and systemic conditions.⁽⁹⁾

Desquamative gingivitis is frequently connected with Mucous Membrane Pemphigoid followed by Oral

lichen planus and Pemphigus Vulgaris with Oral lichen planus alone representing almost 24% to 45% of the cases.¹⁰ In this case, the patient was a 50-year-old woman diagnosed provisionally as desquamative gingivitis. Differential diagnosis for desquamative gingivitis are pemphigoid, lupus erythematosus, linear IgA disease, pemphigus vulgaris.⁽¹¹⁾ In this present case patients complained of burning sensation and bleeding gum on provocation and clinically desquamation and severe erosion in the gingiva and posterior buccal mucosa and patient gave history of vesicles formation which ruptured and erosion/ulceration formation. History and clinical examination were suggestive of mucous membrane pemphigoid. Histopathologic examination revealed non-specific infection. Further confirmatory investigations in this regard were not carried out.

In desquamative gingivitis, there is a disturbance in the ground substance of the gingival connective tissue. The possible impact of the female sex hormones in encouraging the progressions of the ground substance is considered.⁽¹²⁾ Patients are managed with as per the seriousness of symptoms.⁽¹³⁾ In our case the lesions were extensive which can be treated with combination of systemic corticosteroids like Prednisolone and Topical Corticosteroids Triamcinolone, Baclofomethasone Dipropionate, Betamethasone, Clobetasol Propionate, Fluocinonide.

Immunosuppressive agents like Azathioprine, Cyclophosphamide, Cyclosporine, Dapsone were used as treatment options. Antibiotics like Sulphonamides and tetracyclines were also used.^(14,15)

Nowadays monoclonal antibodies like rituximab are used in treatment of such condition.⁽¹⁴⁾

III. Conclusion

This case report presented that Desquamative gingivitis is a non-specific infection and can be successfully managed with tapering dose of systemic corticosteroid methylprednisolone and topical corticosteroid 0.1% Triamcinolone acetate and antioxidant lycopene. The importance of combined systemic and topical steroid and antioxidant therapy in the treatment of such a case has been highlighted in our report.

References

1. Aguirre A, Vasquez JL, Nisengard RL. Desquamative gingivitis. In: Carranza FA, Editor. Clinical Periodontology, 10th ed. New Delhi: Elsevier publishers;2007.p.411-33.
2. Scully C, Beyli M, Ferreiro MC, Ficarra G, Gill Y, Griffiths M, et al. Update on oral lichen planus: Etiopathogenesis and management. Crit Rev Oral Biol Med 1998;9:86-122
3. Katz J, Goultschin J, Benoliel R, Rotstein I, Pisanty S. Lichen planus evoked by periodontal surgery. J ClinPeriodontol1988; 15:263-5.
4. Markopoulos AK, Antoniadis D, Papanayotou P, Trigonidis G. Desquamative gingivitis: a clinical,

- histopathologic, and immunologic study. Quintessence Int 1996;27:763-7.
5. Soukos N, Spyropoulos M. Chronic desquamative gingivitis. Etiology, Clinical and Histological features, immunopathological studies, diagnosis and treatment. OdontostomatolProodos 1990;44:151-8.
6. José Luis Castellanos Suárez. Gingival disorders of immune origin.Medicina Oral 2002;7:271-83.
7. Tomes J, Tomes G. Dental surgery. 4th edition. London: Churchill; 1894.
8. Prinz H. Chronic diffuse desquamative gingivitis Dent Cosmos, 1932;74:331.
9. Newman, Henry H. Takei, Perry R Klokkevold, Fermin A. Carranza, editors. Carranza's Clinical Periodontology. 11th ed. Los Angeles, California: Elsevier;2012.p.111-116.
10. Lo Russo L, Fedele S, Guiglia R, Ciavarella D, Lo Muzio L, Gallo P, et al. Diagnostic pathways and clinical significance of Desquamative gingivitis. J Periodontol.2008;79(1):4-24.
11. Bagan J, Lo Muzio L, Scully C. Mucosal disease series Number III Mucous membrane pemphigoid. Oral Dis 2005; 11:197- 218
12. Engel MB, Harold G. Ray HG, Orban B. The pathogenesis of desquamative gingivitis: disturbance of the connective tissue ground substance. J Dent Res1950;29:410-8.
13. Alkan A, Gunhan O, AlkanA,Otan F. A clinical study of oral mucous membrane pemphigoid. J Int Med Res. 2003 Jul-Aug;31(4):340-4
14. ParisiE,RaghavendraS,WrethPV.Modificationtp the approach of the diagnosis of mucous membrane pemphigoid: a case report ans review of the literature. Oral Surg Oral Med Oral Pathol Oral Radiol Endod.2003;95:182-6.
15. SollecitoTP, ParisiE.Mucous Membrane Pemphigoid. Dent Clin North Am 2005.49(1):91-10.