

Non-surgical management of a periapical abscess in a adolescent patient: A case report

Himanshu Aeran^{1,*}, Shivangi Chandra², Megha Rautela³

¹Director Principal, Professor & HOD, ²Senior Lecturer, ³Post Graduate Student, ¹Dept. of Prosthodontics & Oral Implantology, ^{2,3}Dept. of Pedodontics & Preventive Dentistry, Seema Dental College and Hospital, Veerbhadra Road, Rishikesh, Uttarakhand

***Corresponding Author:**

Email: drhimanu@yahoo.com

Abstract

Aim and Background: Treatment of the damaged or carious molars often presents a set of challenges unique to the posterior dentition. Traditional dental treatments continue to be refined to improve the prognosis when treating the posterior dentition. Root canal treatment using calcium hydroxide as an antibacterial dressing has been reported to be successful in healing large abscess-like periapical lesions. The suggested treatment of periapical abscess with metapex followed by conventional root canal treatment of the involved tooth could result in complete healing of teeth which are initially considered hopeless or recommended for extraction.

Case Description: The article is to present a case report on the management of periapical abscess associated with mandibular right first molar utilizing metapex followed by conventional root canal treatment. The patient was evaluated after filling of canals with metapex every three months for one year. Radiographic examination on follow up showed healing of the defect as well as resolution of periapical radiolucency. Clinical evaluation also revealed reduction of tooth mobility.

Conclusion: Non-surgical healing with metapex is a non-traumatic and cost effective option that can be employed in cases of periapical lesions. It is a good alternative treatment option in cases where peri-apical surgery is indicated.

Keywords: Periapical abscess, Metapex, Root canal treatment.

Introduction

Profound caries lesions may lead to invasion of microorganisms to the dental pulp.⁽¹⁾ Periapical lesions develop as a sequelae to pulp disease.⁽²⁾ Periapical lesions can promote the development of dentoalveolar abscess and periapical bone loss. They are generally diagnosed either during dental radiographic examination or following acute pain in tooth. Most periapical lesions can be classified as dental granulomas, radicular cyst or abscesses.⁽³⁾ Characteristics suggestive of abscesses include size (60-67%) incidence of abscesses in periapical lesions greater than 10mm.⁽⁴⁾ 92% incidence of abscesses in periapical lesions greater than 200mm,⁽⁵⁾ involvement of multiple teeth with necrotic pulp,⁽⁶⁾ straw colored aspirate or drainage, cholesterol crystals etc.⁽⁷⁾ Periapical lesions cannot be differentially diagnosed into abscess and nonabscess lesions. Treatment of the damaged molar often presents a set of challenges unique to the posterior dentition⁽⁸⁾ Up to 85% treatment success has been reported for periapical lesions after endodontic therapy alone which implies that most periapical lesions including abscesses respond to endodontic therapy alone, as also discussed by Nair(1999).⁽⁹⁾ This is explained by the effect of biomechanical preparation on intracanal microbiota, enzymatic mechanisms, immunological mechanisms involving neutralization of antigenic toxins, and breakdown of epithelial lining with involvement of macrophages, non-killer T lymphocytes and Langerhans cell, based on the these features,

conservative endodontics should be the first line of treatment.⁽¹⁰⁾

Based on conservative endodontic treatment there are various intracanal medicaments like calcium hydroxide, antibiotics, steroids, etc for the management of periapical abscess whereas calcium hydroxide based intracanal medicaments are considered as the gold standard. Calcium hydroxide nowadays is widely used as an intracanal endodontic material, due to its high alkalinity tissue dissolving effect, causes induction of repair by hard tissue formation and bactericidal effect. Several works have been done studied the mixture of other substances to calcium hydroxide with the purpose of improving some of its properties. Among these additional substances are vehicles that can speed up or slow down ionic dissociation, substances that aid the filling of pulpal cavity by means of their consistency, substances used as antimicrobial medium and media that enhance radiopacity. Metapex, a silicone oil-based calcium hydroxide paste containing 38% iodoform is very popular. In the presence of large periapical lesions such as in our case placement of intracanal calcium hydroxide.⁽¹¹⁾

Case Description

A 15-year-old female patient reported to the Department of Pedodontics and Preventive Dentistry, with the chief complaint of swelling of gum, pain and difficulty in mastication in right lower back region. The swelling was present since the 15 days. Extraoral examination revealed swelling at the right side angle of

the mandibular extending to body of the mandible. Intraoral examination revealed that Oral hygiene status of patient was fair and Grade I mobility was evident in the 46. Tooth was tender on percussion and vitality test was negative.

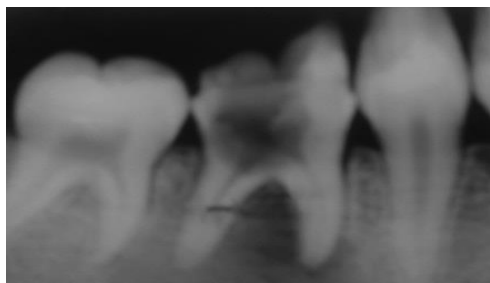

Fig. 1: Preoperative Radiograph

Intra oral periapical radiograph revealed a unilocular periapical radiolucency with smooth, sclerotic borders, 1.5 cm in widest dimension, and involving the periapices of mesial roots (Fig.1) of 46. It was provisionally diagnosed as chronic periapical lesion. Emergency treatment included drainage of the abscess with prescription of antibiotic regimen (Amoxicillin 500 mg and Clavulanic acid 125 mg combination) and analgesic Diclofenac sodium 50 mg twice a day for five days. Patient was re-evaluated after five days, as the swelling and inflammation subsided.

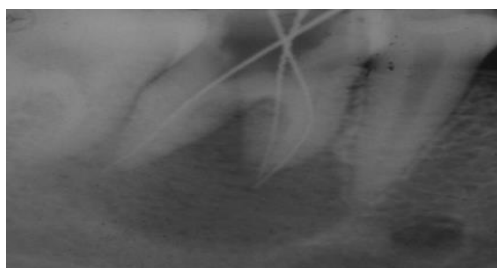


Fig. 2: Working Length

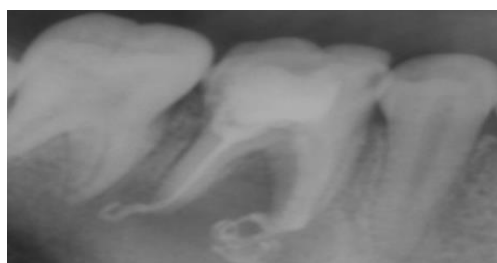

Fig. 3: Intracanal Dressing with Metapex

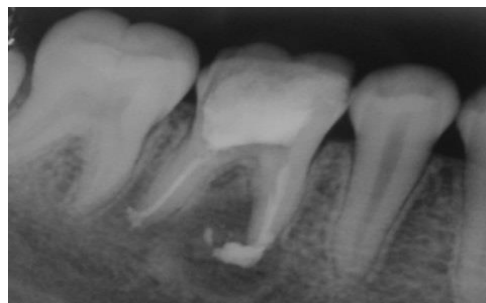

Fig. 4: 2 Month Follow up

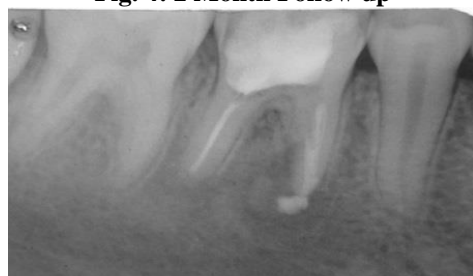


Fig. 5: 4Month Follow up

The patient was offered three treatment choices – non surgical endodontic therapy, periapical surgery, or extraction and prosthetic replacement. She was averse to surgery and opted for non – surgical treatment. She was further keen to preserve the existing crown, as she was satisfied with its function. Conventional root canal treatment was initiated at the second appointment (Fig.2). After bio-mechanical preparation of canals, a non-setting calcium hydroxide paste (Metapex, Meta Biomed Co. Ltd.) was dispensed into the canals and temporary restoration was placed (Fig.3), some of the metapex extruded beyond the apex of the tooth 46 which had undergone resorption itself with time . Follow up was done after one week and when the patient was asymptomatic, tooth was restored with Glass ionomer cement. Further follow-up radiographs were taken at 2 months (Fig-4), 4 months (Fig-5), at 6 months follow-up the tooth was obturated (Fig-6) and at 8 months follow-up visit it was seen that there was resolution of the radiolucency w.r.t 46 (Fig- 7).

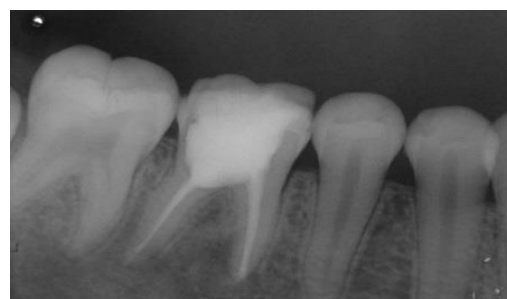

Fig. 6: Obturation w.r.t.46

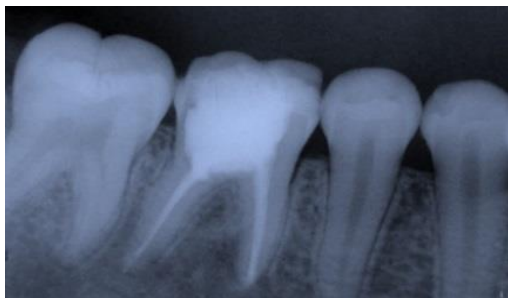

Fig. 7: 8 Month Follow up

Radiographic changes showed in series of follow ups that there was significant reduction in lesion and appearance of new trabeculae pattern and increased bone density in the periapical area. Finally, tooth was obturated with lateral condensation with gutta percha points, followed by permanent restoration with Glass ionomer cement and crown. Recall appointments consisted of reinforcement of oral hygiene instructions, scaling if required and periapical radiographs of the involved tooth.

Discussion

In the present case on clinical examination shows caries which involves the pulp leading to periapical infection. The tooth is non vital and on radiographically shows radiolucency on mesial root of the tooth 46. The perfect mechanism involved in formation of periapical lesions is not fully understood. It is considered that if the pulp becomes necrotic the environment around the periapical area become suitable to allow microorganisms to multiply and various toxins enter into the periapical tissue initiating inflammatory reaction which leads to formation of periapical lesions.⁽¹²⁾

A appropriate treatment varies with the presence, nature and extent of involvement of the diseases For management of periapical abscesses, recommended protocol is drainage and after one week the definitive treatment could be carried out¹. Young molar teeth with pulp necrosis and large periapical lesions in children are frequently treated with root canal treatment. Recent studies have shown, however, that intracanal application of certain medicaments prior to the completion of endodontic therapy may produce highly favorable results when followed by conventional therapy, even when the periapical area is very large.⁽¹³⁾

Metapex was used which consist of $\text{Ca}(\text{OH})_2$ and iodoform, as intra canal medicament in the above cases. It has also been reported that treatment with $\text{Ca}(\text{OH})_2$ resulted in a high frequency of periapical healing, especially in young patients. Healing of lesions may take many months.⁽¹⁴⁾

It is apparent that its use beyond the apex intentionally or accidentally has been associated with the successful nonsurgical management of many cases of large periapical lesions.^(15,16) The exact mechanism

of action of calcium hydroxide is still speculative. It has been advocated that direct contact between the calcium hydroxide and the periapical tissue was necessarily beneficial for Osseo inductive reasons. It is suggested that if the calcium hydroxide is confined to the root canal, it is possible that the inflammation created by the diffusion of the calcium hydroxide through the apical foramen may be sufficient to cause break-up of the abscessic epithelial lining, thereby allowing a connective tissue invagination into the lesion with ultimate healing suggested that the action of calcium hydroxide beyond the apex may be fourfold: (i) anti-inflammatory activity; (ii) neutralization of acid products; (iii) activation of the alkaline phosphatase, (iv) antibacterial action. Even copious amounts of sodium hypochlorite are necessary to utterly dissolve all remnants of pulp tissue as well as completely destroy all microorganisms.⁽¹⁶⁾

Conclusion

Non-surgical healing with metapex is a non-traumatic and cost effective option that can be employed in cases of periapical lesions. It is a good alternative treatment option in cases where peri-apical surgery is indicated but patients want to avoid introral surgery.

References

1. Fernandes M, Ataide D. I. Nonsurgical management of periapical lesions. *J Conserv Dent.*2010;13(4):240-5.
2. Kusgoz A, Yildirim S, Gokalp A. Nonsurgical endodontic treatments in molar teeth with large periapical lesions in children: 2-year follow-up. *Oral Surgery, Oral Medicine, Oral Pathology, Oral Radiology and Endodontology* 2007;104(1).
3. Kritigya Gupta et al, a clinical study on management of mandibular molar with large periapical abscess and furcario involvement: a conservative approach. *Annals and Essence of dentistry, Vol. IV Issue3 Jul-Sep2012,26-29.*
4. Lalonde ER, Luebke RG. The frequency and distribution of periapical abscesss and granulomas. An evaluation of 800 specimens. *Oral Surg Oral Med Oral Pathol.*1968;25:861-8.
5. Morse DR, Patnik IW, Schacterlie GR. Electrophoretic differentiation of radicular abscesss and granulomas. *Oral Surgery, Oral Medicine and Oral Pathology.*1973;35:249-64.
6. Shear M, Speight P. *Abscesss of the Oral and Maxillofacial Regions.* 4th ed 2007. Blackwell Munksgaard.
7. Eversole RL. *Clinical Outline of Oral Pathology: Diagnosis and Treatment.* 2nd ed 1984. Philadelphia,PA.
8. John P. Ducar, Fred Tsutsui and Robert L. Merin. Therapeutic Choices in the Molar Region. *Journal of the California Dental Association*2002;1-10.
9. Nair PN, Sjogren U, Figdor D, Sundqvist G. Persistent periapical radiolucencies of root-filled human teeth, failed endodontic treatments, and periapical scars. *Oral Surg Oral Med Oral Pathol Oral Radiol Endod.*1999;87:617-27.

10. Varun Kapoor et al, Non-surgical endodontics in retreatment of periapical lesions. *J Clin Exp Dent.*2012;4(3):e189-93.
11. Gautam S, Rajkumar B, Landge SP. Antimicrobial efficacy of Metapex (Calcium hydroxide with Iodoform formulation) at different concentrations against selected microorganisms-An in vitro study.*Nepal Med Coll J* 2011;13(4):297-300.
12. Pulver WH, Taubman MA, Smith PH. Immune components in the human dental periapical lesions. *Arch Oral Biol* 1978;23:435-443.
13. Öztan, M.D. Endodontic treatment of teeth associated with a large periapical lesion, *Int Endo J* Jan 2002;35:1 pages73-78.
14. Masoud Saatchi. Healing of large periapical lesion: A nonsurgical treatment approach. *Aust Endod J* 2007;33:136-140.
15. Webber RT (1983) Traumatic injuries and the expanded endodontic role of calcium hydroxide. In: Gerstein CH, ed. *Techniques in Clinical Endodontics*. Philadelphia, PA: WB Saunders, pp.238-9.
16. M. K. Chaliskan, Prognosis of large abscess-like periapical lesions following nonsurgical root canal treatment: a clinical review. *International Endodontic Journal*, 37, 408-416, 2004.