

## Screening by VIA-VILI: A boon for women in developing countries

Sumita Mehta<sup>1</sup>, Ritu Khataja<sup>2</sup>, Swati Rai<sup>3,\*</sup>, Anshul Grover<sup>4</sup>, Ankita Mann<sup>5</sup>, Jyoti Saini<sup>6</sup>

<sup>1,4</sup>Specialist, <sup>2</sup>Assistant Professor, <sup>3</sup>Senior Resident, <sup>5,6</sup>Senior, <sup>1,4,5,6</sup>Dept. of DGO, BJRM Hospital, New Delhi, <sup>2</sup>Dept. of DGO, BSA Hospital, New Delhi, <sup>3</sup>Dept. of Obstetrics & Gynaecology, ESIPGIMSR, Basai Darapur, New Delhi

**\*Corresponding Author:**

Email: drswatirai09@gmail.com

### Abstract

**Aim:** To assess the diagnostic accuracy of visual screening methods VIA and VILI (Visual Inspection with Acetic Acid & Visual Inspection with Lugol's Iodine) for early detection of cervical cancer among women in urban slum areas.

**Materials & Methods:** A cross-sectional study was conducted in Department of Obstetrics & Gynaecology at Babu Jagjeevan Ram Memorial Hospital, Delhi from January 2013 to May 2015. Total of 1800 sexually active women between age group of 25-45 years were screened by VIA/VILI. Screen positive women underwent colposcopic examination and directed biopsy, if required.

**Results:** Among 1800 women, 171(9.5%) were screen positive. Of these 28 women(16.37%) were VIA positive, 40 women(23.39%) were VILI positive and 103 women(60.23%) were both VIA & VILI positive. 150 women underwent colposcopic examination, rest 21 women were lost to follow up. 92 women had abnormal colposcopic findings while 58 had normal findings. In the women who had abnormal colposcopy, 19 had inadequate colposcopy rest 73 women underwent biopsy. On histopathology, nonspecific cervicitis was found in 35 women (47.94%), metaplasia in 25(34.25%), CIN-1 in 10(13.70%) and CIN-2/3 in 3(4.11%). Sensitivity of screening methods was 79.35%, specificity was 75.32% and positive predictive value was 17.81%.

**Conclusion:** Cervical cancer is the second most common cancer in women globally. Cervical cancer is a leading cause of cancer-related death among women in developing countries. As cytology-based screening is difficult to implement, in such low-resource settings hence, alternative low-cost and effective screening methods based on visual examination of the cervix that require simple equipment and relatively brief training have been explored for the control of cervical cancer in low-resource settings.

**Keywords:** VIA, VILI, Carcinoma cervix.

### Introduction

Cancer is a major cause of death worldwide & is mostly underestimated and at times even unaccounted. In India cervical cancer is the most common cause of cancer in females and second most common in the world.<sup>(1)</sup> There is a burden of 5.9 million cervical cancer patients in the world to which there is addition of 900,000 cases every year.<sup>(2)</sup> Every year 200,000 patients are losing their life due to carcinoma cervix. Age old saying states that 'prevention is always better than cure'. For prevention of this disease to progress, interventions are to be implemented as early as possible.

Screening programs need to be in place to pick up pre-invasive disease early so that management can be done timely. The incidence of carcinoma cervix has decreased more than 50% in the past 30 years in developed countries because of the implementation of widespread universal screening methods and same trend is observed in developing countries in recent times.<sup>(3)</sup> Various methods are evolving for screening. In a resource poor country like India where screening is only opportunistic, strict implementation of screening methods based on risk benefit ratio is required to reduce the incidence. Thus a screening method which is simple, safe with small learning curve and low cost is the need of hour.

So we conducted a study to assess the diagnostic accuracy of visual screening methods; VIA (Visual Inspection with Acetic Acid) and VILI (Visual Inspection with Lugol's Iodine) for early detection of cervical cancer.

### Materials & Methods

A cross-sectional study was conducted in Department of Obstetrics & Gynaecology at Babu Jagjeevan Ram Memorial Hospital, Delhi from Jan 2013 to May 2015. Total of 1800 sexually active women between age group of 21-45 years were screened by VIA/VILI after informed consent. Women with obvious cervical growth, post hysterectomy and patients who had never been sexually active were excluded from the study.

VIA (visual inspection after application of acetic acid) was done using 5% acetic acid. The cervix was inspected at transformation zone after one minute of application of 5% acetic acid. Dysplastic or cancerous lesions due to high nucleo-cytoplasmic ratio of undifferentiated cells appear acetowhite on background of normal epithelium on cervix and this was considered VIA positive.

This was followed by VILI (visual inspection after application of Lugol's iodine) in which cervix is inspected after application of Lugol's iodine. It causes normal epithelium comprising of glycogen to turn

mahogany brown. But, precancerous and invasive lesions lack glycogen and thus do not take up iodine, hence appear saffron yellow and were considered positive.

Woman found to be screen positive by either of the visual tests were informed about the test immediately and taken up for colposcopy. Colposcopy directed biopsy was taken wherever necessary. The biopsy samples were sent for histopathology. Women with negative VIA and VILI result were called after 3 years for follow-up. The treatment of precancerous lesions was done as per IARC guidelines.<sup>(4)</sup>

## Results

A total of 1800 women in the age group of 21 to 45 years attending Gynecology OPD for any complaints were screened by the visual methods VIA and VILI after informed consent. Duration of study was for two and half years. All women belonged to low socioeconomic status. Fifty-two percent women were illiterate. 81.90% of women were not aware about any screening test for carcinoma cervix.

Among the screened women, 171(9.5%) were screen positive. Twenty eight women(16.37%) were VIA positive, 40 women(23.39%) were VILI positive and 103 women(60.23%) were both VIA & VILI positive. 150 women underwent colposcopic examination, rest 21 women were lost to follow up. In the women who underwent colposcopy, 58 had normal findings while 92 had abnormal colposcopic findings. In 19 women, colposcopy was inadequate. Rest of the women (n=73) underwent colposcopic biopsy. (Fig. 1)

On histopathology, nonspecific cervicitis was present in 47.94% (n=35), metaplasia in 34.25% (n=25), CIN-1 in 13.70% (n=10) and CIN-2/3 in 4.11% (n=3). Sensitivity of screening methods was 79.35%, specificity was 75.32% and positive predictive value was 17.81 %. (Fig. 2)

## Discussion

The major difference between prevention strategies for cervical cancer from other cancers is the early detection & timely treatment of intraepithelial precursor lesions which take 5-10 years to turn malignant. So timely intervention in the form of screening can prevent the morbidity and mortality associated with this cancer.<sup>(5)</sup> Having said that, awareness regarding screening for cervical cancer is dismal. In our study, 81.9% women were not aware about screening. None of the women had ever undergone screening whereas in the study by Apollinaire G et al 28.2% had cervical screening in past.<sup>(6)</sup> This can be tribute to high level of illiteracy(52%) in our study group.

Most screening programs are cytology based, which has proven to be a boon for developed countries but in India and other low income countries, this is available to a small percentage of women and that to in the urban areas. This is due to lack of resources,

infrastructure, funds and trained cytopathologists. Also it has limited sensitivity ranging from 30-80% and high false negative rate. Hence it is not cost effective to use cytology based screening program in such circumstances.<sup>(7)</sup>

On the contrary, visual screening methods are easy to implement, simple and safe.<sup>(8)</sup> Low level of infrastructure is required for implementation. Health care personnel need to undergo short training periods and specialists are not necessary.<sup>(9)</sup>

Among our study group, 171 women (9.5%) were screen positive which is comparable with the study by Usha et al.<sup>(10)</sup> They were either VIA positive (16.37%), VILI positive (23.39%) or positive for both (60.23%). 40% of the women who were screen positive, were between the age group of 26 years to 35 years. This is similar to study by Luthra et al who found the average age of dysplasia in their study group was 33.8 years.<sup>(11)</sup> This shows that severity of dysplasia increases with age and screening for carcinoma cervix should start early after the onset of sexual activity and all women should be screened at least once by the age of 26-35 years.

150 women underwent colposcopic examination for confirmation of the disease and rest was lost to follow up. There were 92 women (61.3%) with abnormal colposcopic findings and 73 underwent biopsy.

Histopathologically, nonspecific cervicitis was found in majority of cases; 47.94%(n=35) metaplasia in 34.25%(n=25), CIN-1 in 13.70% and high grade lesion in 4.11%. Appollinaire G et al found nonspecific chronic cervicitis in only 4.6% women, CIN1 in 5.9%, and CIN2/3 lesions in 1.2% while Tonveli et al found abnormal histopathological report in 36%.<sup>(6,12)</sup>

We found combined sensitivity and specificity of both screening methods as 79.35% and 75.32% respectively but Tonveli et al found it to be 71% and 47% respectively. There is wide range of sensitivity and specificity of VIA and VILI quoted in literature. This is probably due to inter observer variation, light source, presence of infection and inflammation in various studies.<sup>(13,14)</sup>

VIA has the advantage of being cheap and more sensitive while VILI is much better appreciable and easily available. Combining both the tests increases the specificity and sensitivity for detection of dysplasia.

Although the limitation of visual screening methods is that they are messy, have inter observer variation, time taking; proper counseling is required to convince the subjects.<sup>(15)</sup> But in India, millions of women are never even screened. Thus, in a high population country with very poor resources, a method which is cheap and can screen large number of woman at one time will be fruitful. Also low-cost and effective screening methods based on visual examination of the cervix that require simple equipment and relatively brief training are the answer to control cervical cancer in low-resource settings.

A new global guideline on screening for cancer cervix that provides evidence based recommendation for screening, follow-up and treatment for high risk lesions has been released by ASCO (American Society of Clinical Oncology).<sup>(16)</sup> The guidelines state that “Every woman no matter where she lives, be it a developed or developing nation should have at least one good cervical cancer screen in her lifetime.” Our study also emphasizes the same and recommends visual methods for use in low resource settings.

### Conclusion

VIA AND VILI should be made a routine part of our gynaecological examination as it adds only few minutes to our examination but years to somebody's life.

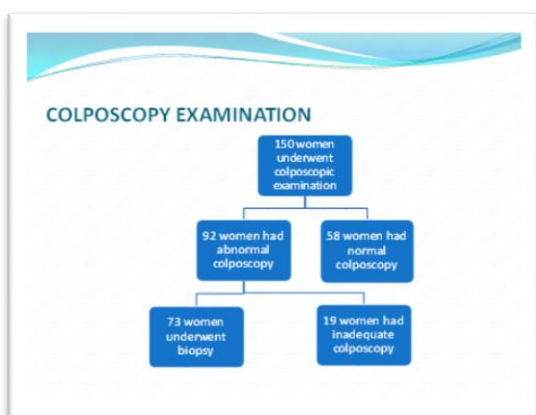


Fig. 1: Colposcopy Examination

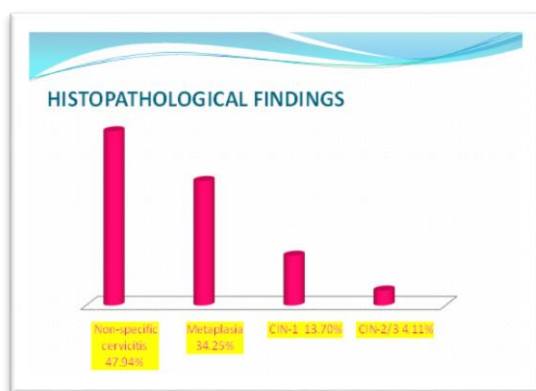


Fig. 2: Histopathological Findings

### References

- Ahmedin J, Freddie B. Global cancer statistics. CA: A Cancer Journal for clinicians. Feb 2011;61(2).
- Parkin DM, Bray F. Global Cancer statistics, 2002. CA: A Cancer Journal for clinicians. Mar 2005;55(2);74-108.
- Practice Bulletin No. 168: Cervical Cancer Screening and Prevention. ObstetGynaecol 2016 Oct;128(4):e111-30.
- Sankaranarayanan R, Thara S, Sharma A, Roy C, Shastri S, 26. Mahe C, et al. Accuracy of conventional cytology:

- Results from a multicentre screening study in India. J Med Screen 2004;11:77-84.
- Ngelange CA, Limson GM. Acetic-acid guided visual inspection vs. cytology based screening for cervical cancer in the Philippines. Int. J of GynaeObst; Nov 2003;83(2);141-150.
- Apollinaire G, Judith c, Abdoul K, Boris T, Konan S, Mamourou K et al. Cervical Cancer Screening Program by Visual Inspection: Acceptability and Feasibility in Health Insurance Companies. Obstet Gynecol Int. 2015;2015:798453.doi: 10.1155/2015/798453. Epub 2015 Jun 18.
- Lynett D, Quinn M et al. Screening for cervical cancer in developing countries. Vaccine 24S3 (2006) S3/71-S3/77.
- Rengaswamy S et al. Effect of visual screening on cervical cancer incidence and mortality in Tamil Nadu, India: a cluster-randomised trial. Lancet 2007;370:398-406.
- Sellers JW, Sankaranarayanan R. Colposcopy and treatment of cervical intraepithelial neoplasia: A beginners' manual. Lyon, France: IARC Press, 2003.
- Usha P, Bidinger P.D et al Visual Inspection with Acetic Acid (VIA) Screening Program: 7 Years' Experience in Early Detection of Cervical Cancer and Pre-Cancers in Rural South India. J of community medicine 2015 Jul-Sep;40(3):203-207.
- Luthra UK, Prabhakar AK, Seth P, Agarwal SS, Murthy NS, Bhatnagar P, et al. Natural history of precancerous and early cancerous lesions of the uterine cervix. ActaCytol1987;31:226-34.
- NV Tonyali, F Kayikcioglu, B Karadag, MF Kose, Y Karasu, DK ComertCan Visual Inspection with Acetic Acid and Lugol's Iodine be used Instead of Colposcopy in Low Resource Settings? DOI: 10.7727/wimj.2015.476.
- Saleh HS, El Hameid AAA, Mowafy HE, Sherif HE, Abdelsalam WA (2016) Visual Inspection of the Cervix with (Acetic Acid or Lugol's Iodine) for Cervical Cancer Screening. Cervical Cancer 1:111.doi:10.4172/2475-3173.1000111.
- Denny L, Kuhn L, Pollack A, Wainwright H, Wright TC Jr (2000) Evaluation of alternative methods of cervical cancer screening for resource-poor settings. Cancer 89:826-833.
- Wright TC, Kuhn L. Alternative approaches to cervical cancer screening for developing countries. Best Pract Res ClinObstetGynaecol. 2012 Apr;26(2):197-208.
- Alexandria Va. New Cervical Cancer Guidelines Addresses Global Resources Disparities. May 25,2016. <https://www.asco.org/news-releases/new-cervical-cancer-guideline-addresses-global-resource>.