

## Hemisection: A Section for Salvation

Jinal Desai<sup>1,\*</sup>, Priyadarshini Nadig<sup>2</sup>, Sarath Chandran<sup>3</sup>

<sup>1</sup>PG Student, <sup>2</sup>Reader, <sup>3</sup>Professor & Head, Dept. Periodontology & Implantology, Manubhai Patel Dental College, Vadodara, Gujarat

\*Corresponding Author:  
Email: jinaldesai8@gmail.com

### Abstract

Hemisection denotes removal or separation of root with its accompanying crown portion of mandibular molars. This procedure represents a form of conservative dentistry, aiming to retain as much of the original tooth structure as possible. The results are predictable and success rates are high. Here is a case report of a 46 year old male with hemisection procedure performed in the tooth #46 with grade III furcation involvement followed by fixed partial denture.

**Keywords:** Mandibular molars, Hemisection, Furcation defects, Root resection

### Introduction

Furcation defects have presented a major challenge to therapists because of their unique anatomical characteristics and their variable response to treatment.<sup>(1)</sup> Attachment loss in the furcation is one of the most serious anatomical sequelae of periodontitis.

The primary goal of periodontal treatment remains the maintenance of the natural dentition in health and comfortable function. Different therapeutic methods for furcation involved tooth are furcation-plasty; tunnel preparation; root resection; guided tissue regeneration at mandibular molars and tooth extraction. Resective therapies like root amputation or resection remain important in an array of therapeutic procedures in periodontal therapy.<sup>(2)</sup> Root separation and resection (RSR) is frequently used in cases of deep class II and class III Furcation involved molars where regenerative procedure is not possible.

### Case Report

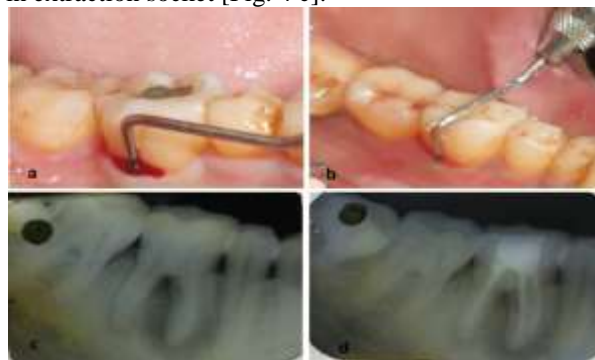A 46-years-old male patient reported with the complaint of pain and mobility of right mandibular first molar. On clinical examination, the tooth was sensitive to vertical percussion and revealed grade I mobility. On probing the area, there was 13 mm deep periodontal pocket and 14 mm clinical attachment loss (CAL) on the mid-buccal and mid-lingual aspect of the tooth [Fig. 1 a & b]. On radiographic examination, the IOPA showed grade II furcation involvement and radiolucency surrounding mesial root of tooth #46 [Fig. 1 c]. On electronic pulp testing, the tooth #46 found to be non-vital. Based on this, a diagnosis of Perio-Endo lesion was made.

In phase I therapy, thorough scaling & root planing and root canal access opening of tooth #46 were carried out. In phase II therapy, the endodontic treatment (RCT) was completed and the chamber was filled with silver amalgam to maintain a good seal [Fig. 1 d].

Under local anaesthesia, full thickness flap was reflected after giving a crevicular incision from premolar to second molar. Upon reflection of the flap, complete

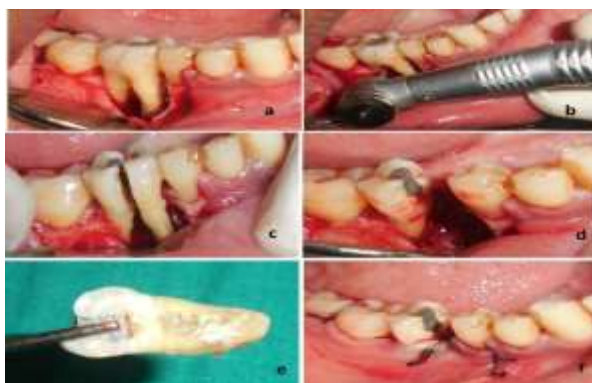bone loss along the mesial root and furcation was evident [Fig. 2 a]. As the defect was extending till the apex of mesial root, hemisection of mesial root was carried out with rotary instrument under irrigation [Fig. 2 b]. The extraction site was debrided and irrigated, then bony defect was recontoured. The flap was repositioned and sutured with 3-0 black silk sutures [Fig. 2 f]. The occlusal table was minimized to redirect the forces along the long axis of the distal root. Suture removal was done after seven days; clinical site was completely healed and was showing grade II mobility [Fig. 3 a]. IOPA shows the well retained distal root and extraction socket of the mesial root. Significant widening of periodontal ligament space along with retained distal root is evident [Fig. 3 b].

The further follow up was done up to 3 months, where mobility significantly reduced from grade II to no mobility and significant bone formation seen on radiograph [Fig. 3 c]. After 3 months, fixed metal prosthesis involving retained distal half and mandibular second premolar was given [Fig. 4 a]. The FPD and hemisectioned distal root is well maintained and stable after 2 years [Fig. 4 b]. 2 year follow-up radiograph shows no widening of periodontal ligament space along with retained distal root and significant bone formation in extraction socket [Fig. 4 c].

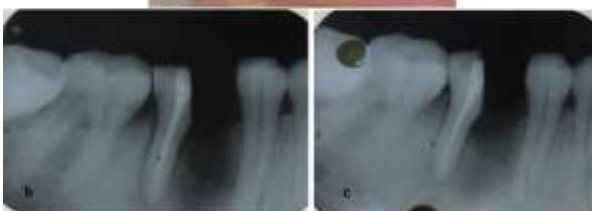
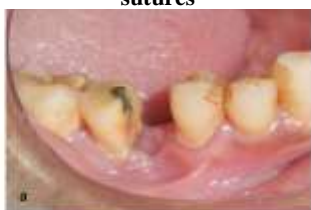

**Fig. 1: Pre-operative photographs and radiographs of tooth #46: a) 13 mm probing pocket depth i.r.t buccal aspect b) 14 mm probing pocket depth i.r.t lingual aspect**

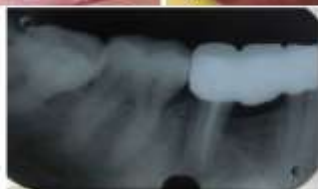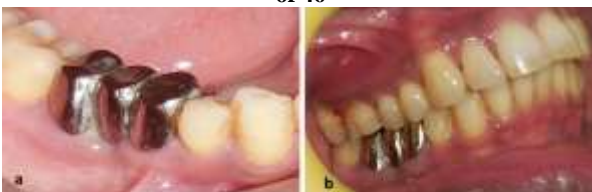c) pre-op radiograph showing radiolucency involving mesial root & furcation area d) radiograph after RCT



**Fig. 2:** Intra-operative photographs of tooth # 46 a) full thickness flap reflection, showing bony defect along the mesial root b) a rotary instrument is used to make vertical cut toward the bifurcation area c) immediately after hemisection of crown d) immediately after removal of resected mesial root along with remaining crown e) resected mesial crown-root portion f) flap closure with 4-0 black silk sutures



**Fig. 3:** Post-operative photographs and radiographs of tooth # 46: a) follow-up clinical picture after 7 days b) immediate post-op radiograph showing well retained distal root & extraction socket c) radiograph after 3 months showing bone formation in socket & distal aspect of 46



**Fig. 4:** Photographs and radiograph showing fixed partial denture i.r.t tooth #45 & retained distal half of tooth #46 a) buccal view of FPD placed after 3 months of surgery b) post-operative clinical photograph after 2 year, showing well retained functional prosthesis c) post-operative radiograph after 2 year, showing well retained functional prosthesis

## Discussion

Molars are the tooth type demonstrating the highest rate of periodontal destruction in untreated disease and suffer the highest frequency of loss for periodontal reasons.<sup>(2)</sup> Loss of such posterior teeth is eventful and undesirable often leading to teeth drifting, loss of masticatory function and loss of arch length, which requires prevention and maintenance measures.<sup>(3)</sup>

Several lines of evidence indicate that teeth with furcation involvements are at higher risk for periodontal disease progression and tooth loss during periodontal recall.<sup>(4)</sup> While regeneration of the periodontium is an accepted treatment goal, not all furcation defects can be effectively treated using regenerative procedures.<sup>(5)</sup> Therefore, respective therapies including root resection procedures remain important procedures in periodontal therapy.

Root amputation, hemi-section, radisection and bisection/ bicuspidization are various resection procedures for treatment of furcation defects which cannot be retained by regenerative procedures. Hemi-section is defined as the removal of half of a tooth performed by sectioning the tooth and removing one root. It is frequently used with reference to lower molars. Buhler et al stated that hemi-section should be considered before every molar extraction,<sup>(5)</sup> because it provides a good, absolute, and biological cost saving alternative with good long term success.

Many factors determine the clinician's decision to choose one treatment plan over another when confronted with a Class III furcation invasion of a mandibular molar. These may be enumerated in three areas:<sup>(6)</sup>

- a. Local factors - tooth anatomy, tooth mobility, crown root ratio, severity of attachment loss, inter-arch and intra-arch occlusal relationship, strategic dental value for retention or removal;
- b. Patient factors - health of a patient, importance of the tooth to the patient, costs, and time factor;
- c. Clinician factors - a good case selection, diagnostic and treatment planning skills, awareness of therapeutic options and clinical insight or skill in providing service.

The decision concerning the final treatment to be performed should be made after the effects of the cause-related therapy have been evaluated. Carnevale et al<sup>(7)</sup> suggested the following sequence for the treatment of furcation involved tooth:

- Phase 1 Endodontic treatment
- Phase 2 Crown build-up
- Phase 3a Root resection or root separation during preliminary prosthetic preparation
- Phase 3b Relining and insertion of a prefabricated shell provisional restoration
- Phase 3c Impression for a metal reinforced provisional restoration
- Phase 4 Insertion of the reinforced provisional restoration
- Phase 5a Periodontal surgery

Phase 5b Root resection or root separation if not previously executed

Phase 5c Tooth preparation during surgery

Phase 5d Relining of the reinforced provisional restoration

Phase 6 Clinical and radiographic re-evaluation

Phase 7 Final prosthetic tooth preparation and impressions

Phase 8 Insertion of the definitive prosthetic reconstruction.

The long-term results of root resection are well described in periodontal literature.<sup>(8,9)</sup> In a systemic review by Huynh-Ba et al, survival rate of molars treated with amputation(s) and hemisections was found 62% to 100%.<sup>(10)</sup> The success rate is quite high when resections are performed by careful diagnosis and the procedures are appropriately performed.<sup>(11,12)</sup> Likewise the reasons for failure are equally well-known.<sup>(13,14)</sup> The primary causes for failure after root resections are root fracture, caries, endodontic complications, cement washout, restorative failures and periodontal attachment loss. The majority of studies indicate that failure rate of resection procedures ranges from 3% and 26% and most periodontal failures occur after 5 to 10 years.<sup>(15)</sup>

## Conclusion

Hemisection can successfully treat specific furcation defects that cannot be solved by other surgical and nonsurgical approaches. Even when less invasive modes of therapy have failed (scaling, root planing, occlusal adjustment, and flap surgery perhaps with osseous recontouring and synthetic or natural bone grafting material where indicated), it is no longer necessary to lose a molar with complete furcation problems. When restorative dentistry has already been finished, and the retention of part of the tooth will extend the life of a crown or fixed partial denture, the patient certainly deserves the option of hemi-section or root amputation rather than extraction.

In this case report, a molar tooth with through & through furcation involvement and extensive bone loss involving mesial root was successfully treated with hemi-section procedure with long term survival in terms of stability and functionality.

## References

1. Pamela K, McClain G, Robert G, Schallhorn. Focus on furcation defects – guided tissue regeneration in combination with bone grafting. *Perio 2000* 2000;22:190–212.
2. Cattabriga M, Pedrazzoli V, Thomas G, Wilson Jr. The conservative approach in the treatment of furcation lesions. *Perio 2000* 2000;22:133–153.
3. Behl AB. Hemi-section of a multi-rooted tooth — A case report. *Open Access Sci Rep* 2012;1:1-3.
4. Panos N, Papapanou S, Maurizio S, Tonetti. Diagnosis and epidemiology of periodontal osseous lesions. *Perio 2000* 2000;22:8–21.
5. Buhler H. Survival rates of hemisected teeth: an attempt to compare them with survival rates of alloplastic implants. *Int J Perio Rest Dent* 1994;14:537-43.
6. Park JB. Hemisection of teeth with questionable prognosis. Report of a case with seven-year results. *J Int Acad Perio* 2009;11:214-9.
7. Carnevale G, Pontoriero R, Hürzeler MB. Management of furcation involvement. *Perio 2000* 1995;9:69-89.
8. Harrington GW. The perio-endo question: differential diagnosis. *Dent Clin North Am* 1979;23:673.
9. Klavan B. Clinical observations following root amputation in maxillary molar teeth. *J Periodontol* 1975;46:1-5.
10. Huynh-Ba G, Kuonen P, Hofer D. The effect of periodontal therapy on the survival rate and incidence of complications of multirrooted teeth with furcation involvement after an observation period of at least 5 years: a systematic review. *J of Clinic Perio* 2009;36:164–176.
11. Carnevale G, Gianfranco D, Tonelli M, Marin C, Fuzzi M. A retrospective analysis of the periodontal prosthetic treatment of molars with inter-radicular lesions. *Int J Perio Rest Dent* 1991;11:189-205.
12. Basten CH-J, Ammons WF, Persson R. Long-term evaluation of root-resected molars: a retrospective study. *Int J Perio Rest Dent* 1996;16:207-219.
13. Buhler H. Survival rates of hemisected teeth: an attempt to compare them with survival rates of alloplastic implants. *Int J Perio Rest Dent* 1994;14:537-43.
14. Erpenstein H. A 3-year study of hemi-sectioned molars. *J Clin Perio* 1983;10:1-10.
15. Langer B, Stein SD, Wagenberg B. An evaluation of root resections. A ten-year study. *J Periodontol* 1981;52:719-22.