

Successful management of Idiopathic gingival enlargement associated with generalized aggressive periodontitis: A rare case report

Lata Goyal^{1*}, ND Gupta², Namita Gupta³

¹Senior Research Associate, AIIMS, Rishikesh, Uttarakhand, ²Professor & HOD, ³Former Resident, Dept. of Periodontics & Community Dentistry, ZADC, AMU, Aligarh

***Corresponding Author:**

Email: latagoyal83@gmail.com

Abstract

Gingival enlargement occurs due to various reasons and in association with various syndromes. But gingival enlargement in association with generalized aggressive periodontitis is a rare finding. As both the clinical conditions are associated with genetic background, it is a matter of interest to search for the possibility of syndromic association of these two diseases. We are presenting a case of 18 year old female with nonsyndromic idiopathic gingival enlargement in association with generalized aggressive periodontitis. Treatment was done by internal bevel gingivectomy, open flap debridement and infrabony pocket elimination. There was no recurrence till 2 year postoperative period.

Keywords: Aggressive periodontitis, Fibromatosis, Gingival hyperplasia

Introduction

Gingival fibromatosis is a rare disorder characterized by proliferative fibrous overgrowth of the gingival tissue that involves marginal, attached and interdental gingiva causing esthetic and functional problems.⁽¹⁾ Gingival tissue usually have firm and fibrotic consistency. Histologically connective tissue has dense collagen fibre bundle, mild chronic inflammatory cells, relatively avascular with numerous fibroblasts.⁽²⁾ It may occur as isolated disorder⁽³⁾ or can be a part of a multisystem syndrome. presenting as an autosomal dominant condition like Laband or Rutherford⁽²⁾ or as a recessive mode of inheritance⁽⁴⁾ such as Cross or Ramon syndrome. Recently involvement of SOS 1 gene has been also suggested⁽⁵⁾ but its heterogenous nature hints towards mutation of other genes also. Another genetically inherited condition is aggressive periodontitis which represents a severe and rapidly progressive form of periodontitis. Various risk factors have been identified causing aggressive periodontitis including familial aggregation, gene polymorphisms, neutrophil functional defects, antibodies response, viral infection, smoking, and stress.⁽⁶⁾ We are presenting a rare case in which both the conditions idiopathic gingival fibromatosis and generalized aggressive periodontitis are diagnosed in a same patient which was successfully managed by means of internal bevel gingivectomy, open flap debridement, pocket elimination and correction of bony defects.

Case Report

An 18-year-old girl reported to the Department of Periodontics with a chief complaint of swollen gums for the past 4 years. She was comfortable with mastication and her main concern was esthetics. She was not taking any medicines, antiepileptic, antihypertensive or immunosuppressive medication. She had undergone her

treatment 2 years back when she got her gingivectomy done but swelling recurred within 5 months. On extraoral examination her face was symmetrical but lips were non competent. Lymph nodes were not palpable and non tender. She was not having any skeletal deformity and her medical and family history was non contributory to present condition. Intraoral examination revealed fibrotic, nonhemorrhagic gingival overgrowth of firm consistency with mild inflammatory component on lingual/palatal aspect involving marginal, interdental and attached gingiva (Fig. 1). Clinical examination revealed generalized spacing in upper and lower anterior teeth. Her oral hygiene was satisfactory. Her full mouth plaque index (Silness and Loe)⁽⁷⁾ was 0.9. Gingival enlargement was graded in accordance to index originally described by Angelopoulos and Goaz 1972 and later modified by Miller and Damn 1992.⁽⁸⁾ Her overall score was below 1. Gingival enlargement was also measured in the buccal-lingual direction in all interdental papilla according to the index described by Seymour *et al.* 1985 and modified by Miranda *et al.* 1998: Miranda-Brunet (MB) index.⁽⁹⁾ Baseline clinical parameters like probing depth, clinical attachment level, mobility, furcation involvement were recorded. Routine blood investigations and hemogram was within normal limits. In contrast to scanty local factors, severe bone loss was evident on orthopantomogram. (Fig. 2). In the light of above clinical findings diagnosis of gingival fibromatosis with generalized aggressive periodontitis was made.

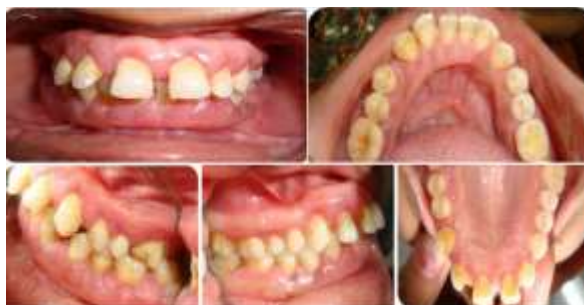

Fig. 1: Preoperative intraoral labial, left lateral, right lateral showing both maxillary and mandibular arches

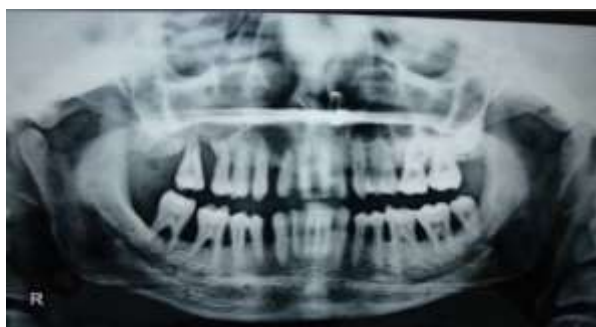

Fig. 2: Panoramic radiographic view showing generalized severe bone loss

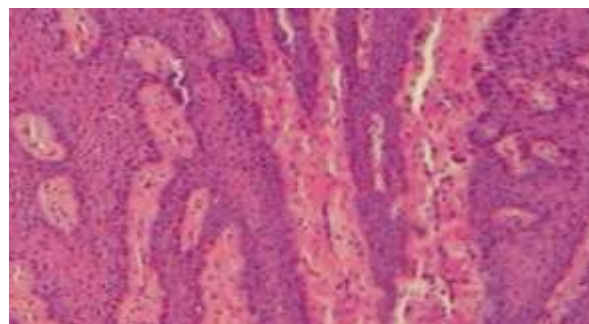


Fig. 4: Histopathological examination revealed hyperkeratosis, elongated rete pegs and acanthosis

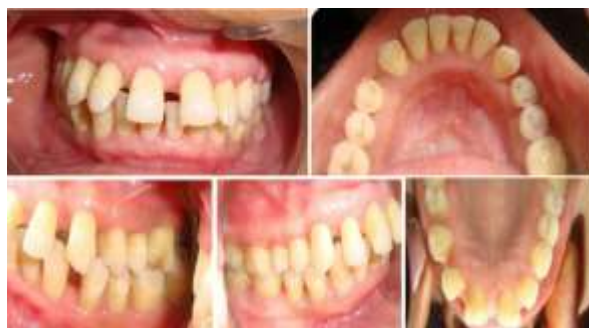

Fig. 5: Postoperative intraoral labial, left lateral, right lateral showing both maxillary and mandibular arches

Treatment: Initial treatment consisted of oral hygiene instructions followed by scaling and root planing (SRP). 6 weeks after SRP full mouth internal bevel gingivectomy followed by open flap debridement was done under local anesthesia (Fig. 3). Procedure was performed sextant wise. The patient was given amoxicillin/Clavuanate and metronidazole three times a day to prevent bacteremia and acefenac 500 mg twice a day to relieve postoperative pain. Periodontal dressing (Coe Pack) was given and was removed after 1 week. Excised tissue was sent for histopathological examination. It revealed hyperkeratosis, elongated rete pegs, numerous collagen bundles and inflammatory infiltrate (Fig. 4). Patient was recalled every 3 months. There was uneventful healing with no recurrence during 2 year postoperative period (Fig. 5).

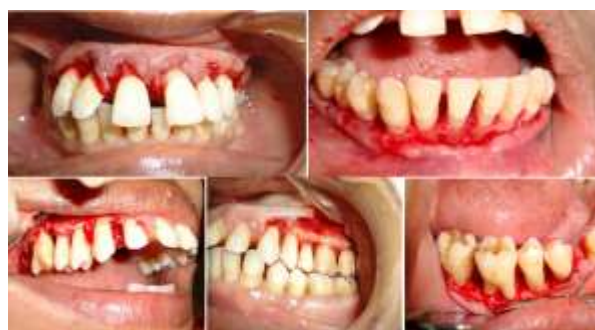

Fig. 3: Open Flap debridement and internal bevel gingivectomy

Discussion

Here we are presenting a case of idiopathic gingival fibromatosis in association with generalized aggressive periodontitis. As both of these diseases have genetic background, it is a matter of interest that whether the occurrence of both the clinical conditions hints towards a new syndrome or represents independent segregation. Idiopathic gingival enlargement is linked to chromosome 2p21-p22 and 5q13-q22 but case reported by Cassavechia⁽¹⁰⁾ where both the condition coexisted did not show the same loci suggesting the need of further research. Regarding pathogenesis it is suggested that TGF- β is two times higher in fibroblast while MMP 1, MMP 2 and their inhibitors are unaltered.⁽¹¹⁾ Mutation of SOS 1 gene has also been suggested.⁽⁵⁾ Increase in collagen and glycosaminoglycans rather than fibroblast using Ki 67 has also been suggested recently.⁽¹²⁾ GF has been associated with various syndromes like Zimmerman-Laband, Cross, Rutherford, Prune-Belly syndrome, mental retardation, hypertrichosis, Murray-Puretic-Drescher syndrome, hypertelorism and supernumerary teeth.⁽³⁾ but association with aggressive periodontitis has been reported by very few authors.⁽¹³⁻¹⁵⁾ Aggressive periodontitis has genetic predisposition characterized by alteration in cellular signaling by means of priming of neutrophils which is responsible for tissue destruction.⁽⁶⁾ Neutrophils shows increased H₂O₂ production and decreased L selectin shedding.⁽⁶⁾ Chaturvedi R⁽¹³⁾ also reported increased neutrophils activity assessed by increased nitro-blue-tetrazolium

reduction test in a patient presented with aggressive periodontitis and gingival enlargement. Padmanabhan S⁽¹⁴⁾ also reported similar condition with additional feature of vitiligo which may be a coincidence. Shetty A et al⁽¹⁵⁾ found reduced phagocytic activity of neutrophils in a patient with idiopathic gingival enlargement and aggressive periodontitis but neutrophil chemotaxis assay was within normal limits. Based on limited data available it is difficult to comment on syndromic association of these two clinical conditions. This area needs further research as it is a great challenge for the dental professionals to treat fibromatosis and aggressive periodontitis in a same patient. Treatment considerations include initial therapy, periodontal surgery, treatment of residual risk factors, problem focused surgical therapy in patients demonstrating good plaque control and compliance to achieve effective root debridement thus enhancing regenerative therapy, decreasing gingival recession and periodontal maintenance. Treatment in the present case included internal bevel gingivectomy, open flap debridement, pocket elimination and correction of bony defects by osteoplasty/osteotomy. Patient was recalled every 3 months for followup and healing occurs uneventfully. There was no recurrence till 2 year postoperative period.

Conclusion

We have presented a successfully treated case of nonsyndromic idiopathic gingival fibromatosis in association with generalized aggressive periodontitis. Diagnosis was based on clinical, histopathological and radiological findings. Whether the association of these two conditions is merely a coincidence or point towards a new syndrome is matter of research. To further understand pathogenesis more insight into immunological and genetic basis is needed.

References

1. Bittencourt LP, Campos V, Moliterno LF, Riberio DP, Sampalo RK. Hereditary gingival fibromatosis: Review of the Literature and a case report. *Quintessence Int* 2000;31:415-18.
2. Coletta RD, Graner E. Hereditary gingival fibromatosis: A Systematic review. *J Periodontol* 2006;77:753-64.
3. Goyal L, Bey A, Gupta ND, Varshney A. Diagnosis and management of nonsyndromic hereditary gingival fibromatosis in a 13 year old girl: Report of a rare case. *Contemp Clin Dent* 2012;3:210-13.
4. Singer SL, Goldblatt J, Hallam LA, Winters JC. Hereditary gingival fibromatosis with a recessive mode of inheritance. Case reports. *Aust Dent J* 1993;38:427-32.
5. Hart TC, Zhang Y, Gorry MC, Hart PS, Cooper M, Marazita ML *et al.* A mutation in the *SOS1* gene causes hereditary gingival fibromatosis type. *Am J Hum Genet* 2002;70:943-54.
6. Gainet J, Dang PM, Chollet-Martin S, Brion M, Sixou M, Hakim J *et al.* Neutrophil dysfunctions, IL 8 and soluble L selectin plasma levels in rapidly progressive versus adult and juvenile periodontitis: Variations according to disease severity and microbial flora. *J Immunol* 1999;163:5013-19.

7. Silness J, Loe H. Periodontal disease in pregnancy. II. Correlation between oral hygiene and periodontal condition. *Acta Odontol Scand* 1964;22:112-35.
8. Miller CS, Damm DD. Incidence of verapamil-induced gingival hyperplasia in a dental population. *J Periodontol.* 1992;63:453-56.
9. Seymour RA, Smith DG, Turnbull DN. The effects of phenytoin and sodium valproate on the periodontal health of adult epileptic patients. *J Clin Periodontol.* 1985;12:413-19.
10. Casavecchia P, Uzel MI, Kantarci A, Hasturk H, Dibart S, Hart TC. Hereditary gingival fibromatosis associated with generalized aggressive periodontitis: A case report. *J Periodontol* 2004;75:770-78.
11. Coletta RD, Almeida OP, Reynolds MA, Sauk JJ. Alteration in expression of MMP 1 and MMP 2 but not TIMP - 1 and TIMP -2 in hereditary gingival fibromatosis is mediated by TGF-beta 1 autocrine stimulation. *J Periodontal Res* 1999;34:457-63.
12. Saygun I, Ozdemir A, Gunhan O, Aydintug YS, Karsiloglu Y. Hereditary gingival fibromatosis and expression of Ki-67 antigen: A case report. *J Periodontol* 2003;74:873-78.
13. Chaturvedi R. Idiopathic Gingival Fibromatosis Associated with Generalized Aggressive Periodontitis: A Case Report. *J Can Dent Assoc* 2009;75:291-95.
14. Padmanabhan S, Dwarakanath CD. Severe gingival enlargement associated with aggressive periodontitis. *J Indian Soc Periodontol* 2013;17:115-19.
15. Shetty A, Gupta N, Shetty D, Kadakia R. Idiopathic gingival enlargement associated with generalized aggressive periodontitis in a 19 year old female. *J Indian Soc Periodontol* 2014;18:244-48.