

Rigid internal fixation of zygoma: A comparison between two point v/s three point fixation

Indraj Arora^{1*}, Rajesh Dhirawani², Ankit Rathod³, Sanchit Jain⁴

¹PG Resident, ²Professor & HOD, ³Retinal Consultant, ⁴Senior Lecturer, ^{1,2,4}Dept. of OMFS, ^{1,2,4}Hitkarini Dental College, Jabalpur, Madhya Pradesh, ³Janjyoti Super Speciality Eye Hospital, Jabalpur, Madhya Pradesh, India

***Corresponding Author:**

Email: indrajarora09@gmail.com

Abstract

Zygomatic complex fractures, many at times present challenging diagnostic and reconstructive problems for the surgeon. Treatment options for reduction of isolated zygomatic bone fractures range from closed reduction without fixation to open reduction with multiple points of exposure and fixation such as 1-point, 2-point, 3-point fixation depending upon degree of displacement. There is a general consensus that open reduction is the treatment of choice for comminuted fractures but the reduction method for management of less severe fractures is still controversial. In the present study, 110 patients of ZMC fracture were randomly assigned into two point (group 1) or three point fixation (group 2). Road traffic accident was the cause of zygomatic fractures in 80% cases, accidental falls in 10%, sports injuries and assault 10%. Patients were reviewed clinically, photographically as well as radiographically 1 week postoperatively followed by review after 4 weeks and 12 weeks. Reviewing results from all the aspects and keeping in mind the limitation and variables in this study, it can be concluded that fixation of ZMC fracture with two point fixation is an equally effective method as three point fixation; that provides stability in all three planes and results in no displacement in moderately displaced zygomatic bone fractures. However the cases with muscle entrapment or infra orbital rim displacement more than 2 mm or muscle entrapment; an additional site should be addressed to reduce the post-operative complications like dystopia or enophthalmos.

Keywords: Dystopia, Enophthalmos, Fixation, Fracture, Zygomaticomaxillary complex.

Introduction

The face occupies the most prominent position in the human body rendering it vulnerable to injuries. The convexity and projection of zygomatic bone forms the greatest prominence of cheek, blow to this part of face is quiet common making it second most common bone of mid face to get fractured (45% of all midface fractures) after the nasal bone in facial region. The body and process of zygomatic bone makes up the lateral middle third of facial skeleton. Assaults and road traffic accident (RTA) are mainly attributed as cause of fracture.⁽³⁾

Disruption of the zygomatic position carries significant physiological, aesthetic & functional sequelae causing impairment of ocular and mandibular function. Therefore, it is mandatory for zygomatic bone injury to be properly diagnosed and adequately managed.⁽⁴⁾

Achieving normal anatomic contour and position of malar eminence and zygomatic body is crucial to render favorable results in reconstruction of midface. Therefore the treatment must attain adequate and stable reduction at fracture site so as to restore the complex multidimensional relationship of zygoma to surrounding structures. Owing to the paucity of clinical studies, the precise stability of the zygoma with reference to the fixation sites and number of fixation point remains a topic of debate.⁽¹⁾

The aim of this study is to compare the functional and esthetic results of two-point and three-point fixation with miniplates in patients with zygomatic

fracture, so as to formulate an operative strategy to achieve the surgical objective of stable fixation while minimizing the morbidity of procedure.

Materials and Methods

110 adult patients who reported to our department having displaced zygomatic complex fracture without indication for orbital floor reconstruction were included in the study. The patients would undergo open reduction with internal fixation of the fractured segments using titanium miniplates under general anesthesia. Procedure and the study were explained to the patient and those who gave informed consent were included in the study. The study was approved by ethical committee as it involves open reduction and internal fixation.

Adult patients having displaced zygomatic complex fractures with definite indication for open reduction and fixation who reported within 72 hrs of injury were included in the study.

All the patients with systemic disease contraindicating general anaesthesia, blow out fracture, where additional procedure in required for reconstruction of orbital floor or any other associated midface fracture were excluded from the study. Bilaterally displaced fracture of zygoma, Gunshot wound fracture and patients with history of previous zygomatico maxillary complex fractures or osteotomies involving the infra orbital foramen were also excluded.

Surgical Protocol

Amsterdam treatment protocol (2008) was followed intraoperatively and the patients were divided into two groups in which group I patients were treated with two-point fixation protocol (fixation at frontozygomatic suture and zygomaticomaxillary buttress) and group II involving three-point fixation protocol (fixation of frontozygomatic suture, infraorbital rim and zygomatic buttress).

Operative procedure involved open reduction and internal fixation using non compressive miniplates under general anesthesia. Exposure of the frontozygomatic buttress region was achieved by lateral brow incision and upper buccal sulcus respectively. After ensuring reduction and anatomical alignment at all the three fracture sites, miniplates were applied at these two points in group I patients. (Fig. 2)

In group II patients, exposure of frontozygomatic suture, infraorbital and zygomatic buttress region was achieved by lateral brow incision, infraorbital incision

and upper buccal sulcus incision respectively. After ensuring reduction and anatomical alignment of all the three fracture sites, miniplates are applied at these three points. (Fig. 3)

Patients were reviewed clinically 1 week postoperatively followed by review after 4 weeks and 12 weeks. Throughout the study these patients were evaluated preoperatively and postoperatively for various parameters. Observer, who evaluate patients preoperatively and postoperatively was blinded with the intraoperative procedure (either 2-point or 3-point fixation is done). Conventional radiographs (paranasal sinus view and sub-mentovertex view) and CT-scan were taken 12 weeks postoperatively to visualize, the fracture site, rotation displacement of zygoma and postoperative bone healing.

The analysis was done on clinical basis and radiographic basis. Detail description of both are given below.

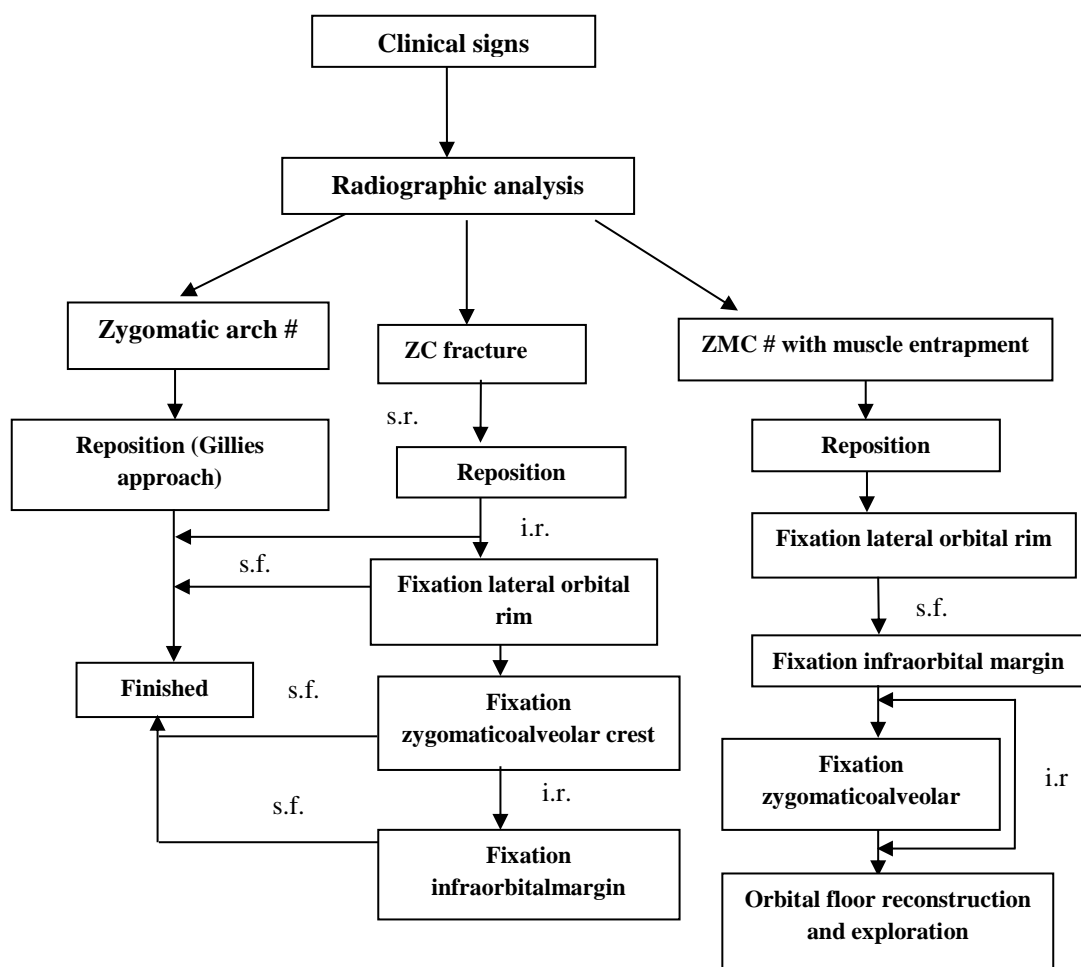


Fig. 1: Amsterdam Treatment protocol: s.r. stable reposition, i.r. instable reposition, s.f. stable fixation, i.f. instable fixation⁽³⁰⁾

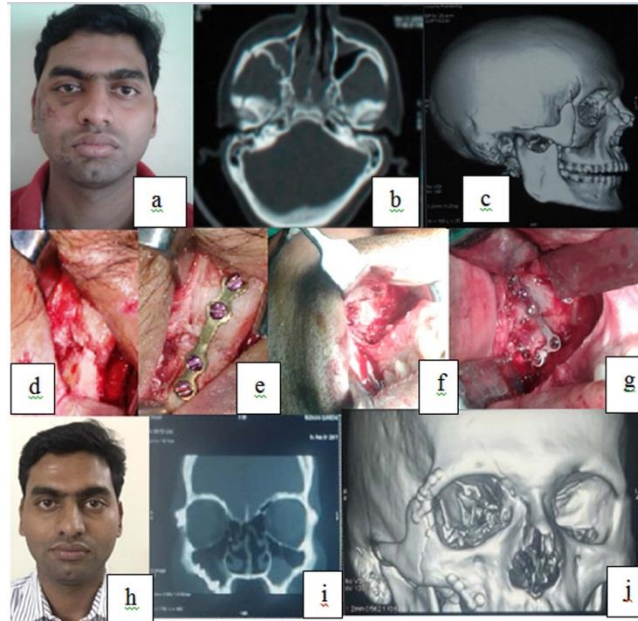


Fig. 2: group 1 a-preoperative picture with Right Eye enophthalmos ;b-axial CT cut showing fractured anterior and postero-lateral wall of maxillary sinus;c-3D CT showing ZMC fracture right side; d-exposed fracture in FZ region; e-FZ fracture reduced and fixed using 1.5mm 4 hole titanium plate; f-fractured zygomatic buttress right side; g-fractured buttress reduced and fixed using 2mm 4 hole L plate;h-6 months postoperative picture of the patient; i-coronal CT cut of the patient 6 months postoperatively; j-3D CT showing fixation at FZ and buttress region.

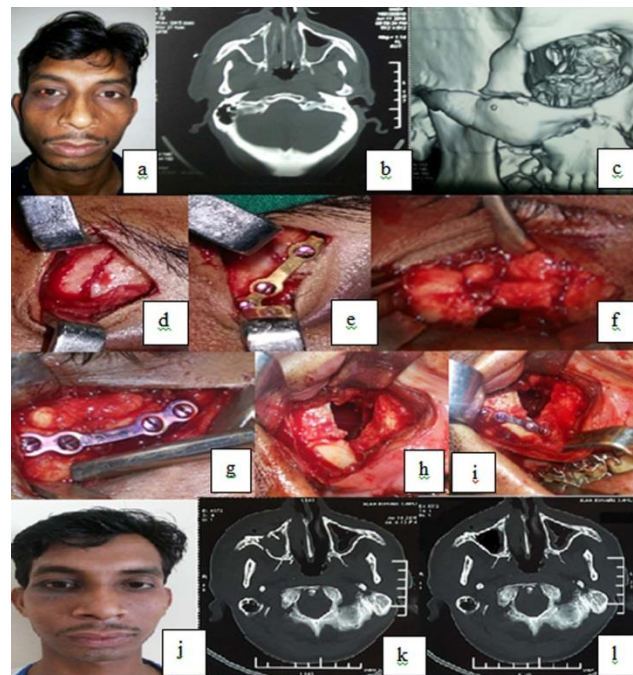


Fig. 3: Group 2 a-preoperative picture with sub-conjunctival hemorrhage with posterior limit undefined; b-axial CT cut showing fractured anterior wall of maxillary sinus and fluid filled sinus;c-3D CT showing fractured ZMC right side; d-exposed fractured FZ region; e-fracture FZ region reduced and fixed using 1.5 mm 4 hole titanium plate; f-fracture intraorbital region exposed using intraorbital incision; g-intraorbital fracture reduced and fixed using 1.5mm 4 hole orbital plate; h-fracture in the zygomatic buttress region exposed using keen's approach; i-zygomatic buttress fracture reduced and fixed using 2mm 4 hole plate; j-6 months postoperative picture of the patient; k-1 month postoperative axial CT cut ; l-6 months postoperative axial CT cut

Clinical Parameters

a) Facial Symmetry⁽³⁾

- i. Malar prominence was evaluated using Hinderers line: A line is drawn from lateral canthus of eye to corner of mouth; another line is drawn from ala to tragus region. Point of intersection of both the lines is marked bilaterally. Taking glabella (Point A) as a reference point; distance calculated from glabella to point B & B'

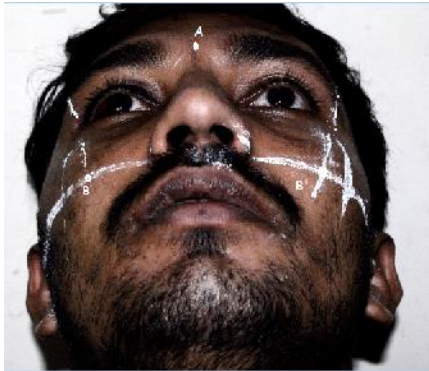

Fig. 3: Measurement of malar asymmetry using Hinderer's lines. Point A: glabella; Point B: malar prominence on right side; Point B' : malar prominence on left side.

- ii. Surgeon's evaluation of facial asymmetry⁽¹⁰⁾
Scoring was done as follow
 - a. -5 points: marked asymmetry of the face
 - b. 0 points: mild asymmetry
 - c. 5 points: no asymmetry
- iii. Self-evaluation of facial asymmetry⁽¹⁰⁾
Scoring was done as follows
 - a. -5 points: not pleased with appearance
 - b. 0 points: not fully pleased with appearance
 - c. 5 points: pleased with appearance

b) Limited Mouth Opening: (interincisal distance was calculated)

Scoring was done according to maxillofacial injury severity score.⁽⁸⁾

- i. mouth opening range 2-3.7cm
- ii. mouth opening range less than 2 cm

c) Ophthalmological Evaluation⁽¹⁰⁾

- i. Diplopia
 - a. Normal vision
 - b. Double vision
- ii. A P globe position was evaluated using Hertel's exophthalmometer

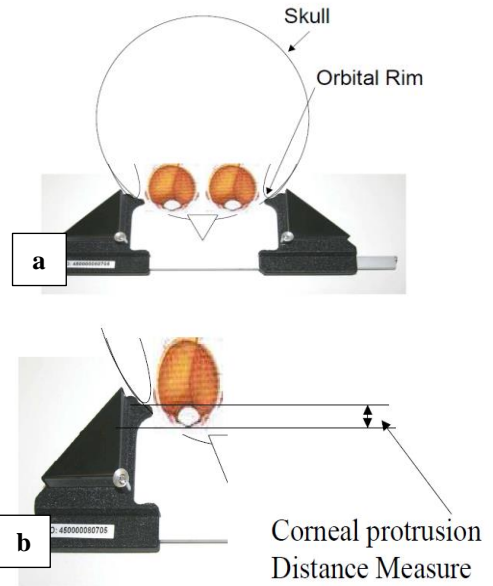


Fig. 4 a: Diagrammatic presentation of use of hertel's exophthalmometer⁽¹⁷⁾

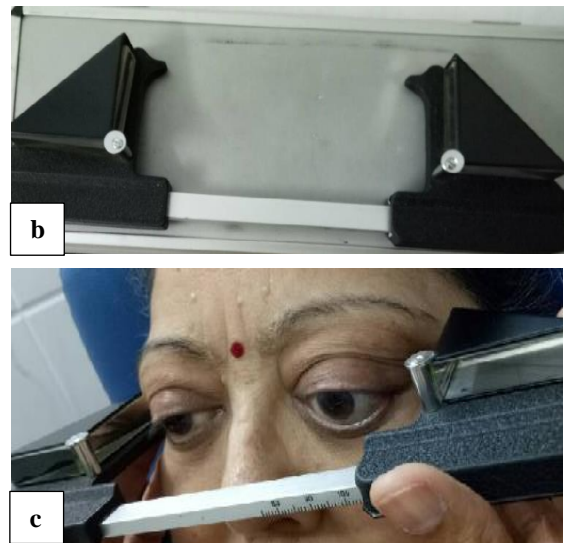


Fig. 4 b: Hertel's exophthalmometer; c. Hertel's exophthalmometer used to measure AP globe projection

Photographic Parameters

- 1. Vertical globe position: Vertical dystopia is measured by drawing a vertical line over the bridge of the nose perpendicular to a line drawn on the supraorbital region. Point a and a' measures the distance of both the pupil from supra orbital region. Difference between a & a' is measured.

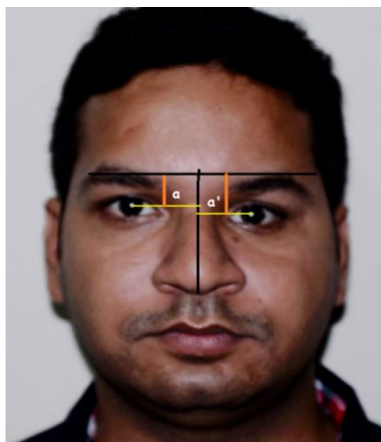


Fig. 5: Measurement of dystopia using front profile of the patient

- a) < 2mm asymmetry
 - b) > 2mm asymmetry
2. Photographs- Aesthetic assessment was done and scored as proposed by Holmes and Mathews.⁹
- a) Grade I : Excellent cosmetic result, no malar asymmetry
 - b) Grade II: Good cosmetic result, malar asymmetry on careful inspection.
 - c) Grade III: Poor cosmetic result, noticeable malar asymmetry
 - d) Grade IV: Gross malar asymmetry.

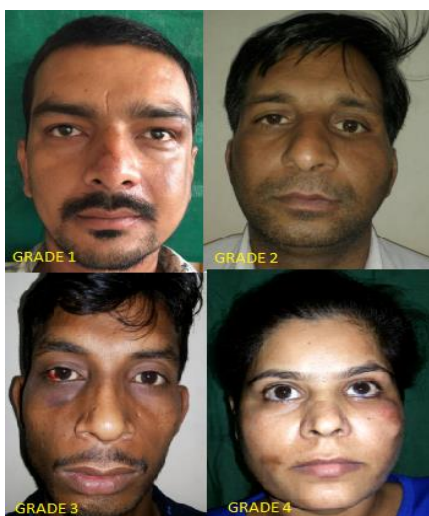

Fig. 6: Frontal profile view of patients showing different grades of Holmes and Mathew criteria for assessment of facial asymmetry.

Radiographic Parameters

1. **Zygomatic Complex Projection:** It was assessed using axial section of the complex. Anterior and posterior zygomatic complex width was recorded followed by measuring the distance between the most prominent and most dependent point in zygomatic arch.

Same dimensions on the contralateral normal side was recorded to find out deficit in the height.

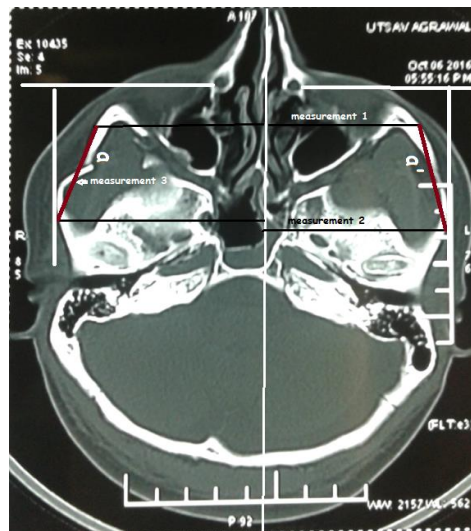


Fig. 7: Axial CT image indicating landmarks, reference lines & measurements.⁽¹¹⁾

Table 1: reference lines for measurement in CT scan⁽¹¹⁾

Measurement 1 (Anterior zygomatic complex width)	Distance from midline to the most lateral aspect of the curve of the zygomatic arch anteriorly.
Measurement 2 (Posterior zygomatic complex width)	Distance from midline to the most lateral aspect of the curve of the zygomatic arch.
Measurement 3 (Zygomatic complex projection)	Distance between point 1 and point 2

All these parameters were noted down and tabulated for specific analysis to compare 2-point fixation to 3-point fixation of displaced zygomaticomaxillary complex.

Results

This study consisted of 110 patients, out of which 80 (72%) were male and 30 (28%) female patients. Road traffic accident was the main cause of zygomatic fractures in 80% cases, followed by accidental falls in 10%, and sports injuries and assault 10% .In this study, road traffic accident was the major cause because of the geographical variations and not following the road traffic rules by the increased population.

The preferred site of fixation according to Amsterdam protocol was the lateral orbital rim. Where the reduction was unstable a second miniplate was placed at the zygomatico-alveolar crest. If necessary a third miniplate was placed at the infraorbital margin. In the present study, Amsterdam protocol is followed intra operatively for both the groups. The results showed that there was minimal or change in the distance in 3

different planes in spite of changing the position of the skull.

In the present study, axial cuts of CT scan were taken to evaluate zygomatic complex width and projection both preoperatively and post operatively in both the groups (Table 1). There was no significant difference between the 2 groups at any interval.

In the present study, facial asymmetry was evaluated in all the patients using Hinderer's line to measure malar prominence both photographically and radiographically (graph 1 & 2); which was first described by hinderer UT. The difference in contra lateral and affected sides were evaluated in all the patients both pre operatively and postoperatively.

In this study, significant difference is seen in the preoperative and post-operative malar prominence in both the groups. Also in this study we concluded that there was significant difference seen in pre-operative and post-operative malar prominence in both the groups.

Postoperative edema was more in group 2 patients in comparison to group 1 patient when evaluated at an interval of 1 month postoperatively. 1 month post-operative swelling can be attributed to comparatively more surgical exploration required for infra orbital fixation in comparison to group 1 patients. Though 3 month postoperative evaluation showed no significant difference in both the groups.

In this study, photographic evaluation of all the patients to evaluate facial asymmetry as well as dystopia were done pre operatively as well as post operatively using Holmes and Mathew⁹ criteria (graph 3). There was no significant difference in between both the groups. In the present study, there was no significant difference in the ocular parameters like diplopia, dystopia and enophthalmos in between both the groups. (Graph 4 & 5)

Upon detailed assessment of the stability, the difference in the mean readings dictating the change in the position of zygomatic bone in all the 3 planes i.e. vertical, transverse and antero-posterior plane were calculated at immediate post-operative CT scans and at 3 months post-operative CT scans. It was found that no significant variations were seen in the position of the zygomatic bone on the CT scans and the stability was maintained in all 3 planes post-operatively.

In the present study, axial cuts of CT scan were taken to evaluate zygomatic complex height and projection of all the patients both pre operatively and post operatively. There was no significant difference seen in the post-operative results of both the groups.

The post-operative infection at the fractured site is not only the result of contamination, but is also related to reduced stability of fracture i.e. mobility of fractured segments. Stability is considered as the best protection against infection, as movement in the presence of foreign bodies (i.e. loose screws) usually leads to

infection and mal-union. In the present study, no infection was seen in any of the cases post-operatively.

Analysis of clinical parameters (malar depression, dystopia and enophthalmos) revealed no statistically significant variation among the two groups. Although 1 month post-operative edema was more in group 2 patients which can attributed to the additional surgical site. The findings of the photographic and radiological assessment revealed no statistically significant variation among the two groups. Sufficient stability was achieved by both the groups to oppose the biomechanical forces tending to displace the zygomatic complex which was evaluated by CT scans.

On the basis of above facts obtained, it could be suggested that three-point fixation for the zygomatic bone fractures has no added advantage over two point fixation. In addition, longer operative time, presence of more hardware, cost of surgery, post-operative scarring (infra orbital region) are some disadvantages of fixation across an additional point.

Statistical Analysis: The recorded data was compiled and entered in a spreadsheet computer program (microsoft excel 2007) and then exported to data editor page of SPSS version 20.0 (SPSS Inc., Chicago, Illinois, USA). The data was found to be normal by the Kolmogorov Smirnov test, hence parametric tests were applied. Intergroup comparison was done using student's t-test, intragroup comparison by using the paired t-test for quantitative data (mean values of hinderer's line and malar prominence) and Chi square test was done for qualitative data (percentages of mouth opening, diplopia, enophthalmos, surgeon's evaluation, self-evaluation and Holmes Mathew criteria). Level of significance was set at 0.05.

Discussion

The zygomaticomaxillary complex (ZMC) functions as a buttress for the face and is the cornerstone to a person's aesthetic appearance, by both setting midfacial width and providing prominence to the cheek. It can best be anatomically described as a "TETRAPOD" as it maintains four points of articulation with the frontal bone, temporal bone, maxilla, and greater wing of the sphenoid, at the zygomaticofrontal (ZF) suture, zygomaticotemporal (ZT) suture, zygomaticomaxillary buttress (ZMB), and zygomaticosphenoid (ZS) suture, respectively.

This tetrapod configuration then lends itself to complex fractures, as fracture here rarely occur in isolation. Additionally, the zygoma serves as the attachment point for muscles of both the mastication and facial animation, and amongst these, it is the masseter muscle that provides the most significant intrinsic deforming force on the zygomatic body and the arch.

The majority of the ZMC fractures occur in men. These injuries are most commonly seen in the second or

third decades of life and are most associated with road traffic accidents which is also confirmed in our study.

Management of the zygomatic complex fractures is controversial. Historically closed reduction was the method of choice for management of all zygomatic complex fractures. These days, miniplates have been the preferred fixation method incraniomaxillofacial surgery because of their relatively small size, adaptability, ease of placement and concealed intraoral approach. The number and location of miniplates for fixation depend on the fracture anatomy, extent, and amount of displacement.

Various authors proposed that 2-point fixation using a miniplate conferred a degree of stability comparable with most methods of 3-point fixation, regardless of the site at which the miniplates were applied. Many other authors such as Manson et al have observed that ZMB is one of the best site of fixation as it is direct antagonist to the pull of masseter muscle and site of fixation is deep and the plate is rarely felt in this area, so the fixation is longer and stronger.⁽²⁶⁾ They also showed that although FZ was having the best bone for fixation but it was the worst single-alignment guide. It can be used for a second or third area of evaluation. After them, infraorbital rim was used for the same objective.

Paik-Kwoon et al stated that two-point fixation at the infraorbital and frontozygomatic suture region would provide significant amount of stability, provided the comminution of zygoma is not severe. Zachariades et al⁽⁴⁾ showed the presence of solid compact bone in the mid face at the frontozygomatic region, infra orbital margin and zygomatic buttress which was used for rigid internal fixation with mini plates and screws at the sites in management of zygomatic complex fractures. They concluded that a single point of fixation failed to address the 3 dimensional rotation in zygomatic complex fractures hence 2 point fixation at the frontozygomatic along with the zygomatic buttress region is required.

Holmes- Mathew⁽⁹⁾ proposed that infra orbital rim is not a preferred choice for mini bone plate osteosynthesis as there are no functional loads in this area and even though the bone is compact at the infra orbital rim it is so thin that only few threads of the screws can be anchored. Also authors like Punjabi SK et al⁽¹⁾ stated that three-point fixation—at frontozygomatic region, zygomatic buttress region and infraorbital region; is most effective and safe method for the reduction of fracture of zygomatic bone.

Ellis E: Kittidumkerng W⁽¹¹⁾ conducted a comparative study between 2 point fixation v/s 3 point fixation and concluded that none of the patient without infra orbital rim fixation had diplopia, a step of infra orbital rim or post reduction rotation. In both the groups, alignment of infra orbital rim was good after fracture reduction which is slightly against our study.

Lee PK et al⁽²⁾ conducted a comparative study of 2 point and 3 point rigid fixation of zygomatic bone fracture. They concluded that 3 point fixation has better stability at fracture site resulting in better malar projection and height along with decreased incidence of dystopia and enophthalmos. Otavio R-Marhino M stated that eye assessment is an imperative part of examination for all zygomaticomaxillary complex and therefore accurate 3 dimensional fracture reduction is most important component of surgical treatment of ZMC fractures. They concluded that surgical exploration of fractured orbital floor should only be performed in presence of clear clinical and radiological evidence which supports our study.

In this study, it was found that when a tripod fracture without any comminution or mild to moderate displacement was stabilized very well with a two-point fixation in the FZ and ZMB region without any complications. However the cases with muscle entrapment or infra orbital rim displacement more than 2 mm or muscle entrapment; an additional site should be addressed to reduce the post-operative complications like dystopia or enophthalmos.

Conclusion

Both the groups in our study were comparable in terms of age and extent of injury. Analysis of clinical parameters (malar depression, dystopia and enophthalmos) revealed no statistically significant variation among the two groups. Although 1 month post-operative edema was more in group 2 patients which can attributed to the additional surgical site. The findings of the photographic and radiological assessment revealed no statistically significant variation among the two groups. Sufficient stability was achieved by both the groups to oppose the biomechanical forces tending to displace the zygomatic complex which was evaluated by CT scans.

Reviewing results from all the aspects and keeping in mind the limitation and variables in this study, it can be concluded that fixation of ZMC fracture with two point fixation is an equally effective method as three point fixation; that provides stability in all three planes and results in no displacement in moderately displaced zygomatic bone fractures.

In addition, longer operative time, presence of more hardware, cost of surgery, post-operative scarring (infra orbital region) are some disadvantages of fixation across an additional point. However the cases with muscle entrapment or infra orbital rim displacement more than 2 mm or muscle entrapment; an additional site should be addressed to reduce the post-operative complications like dystopia or enophthalmos.

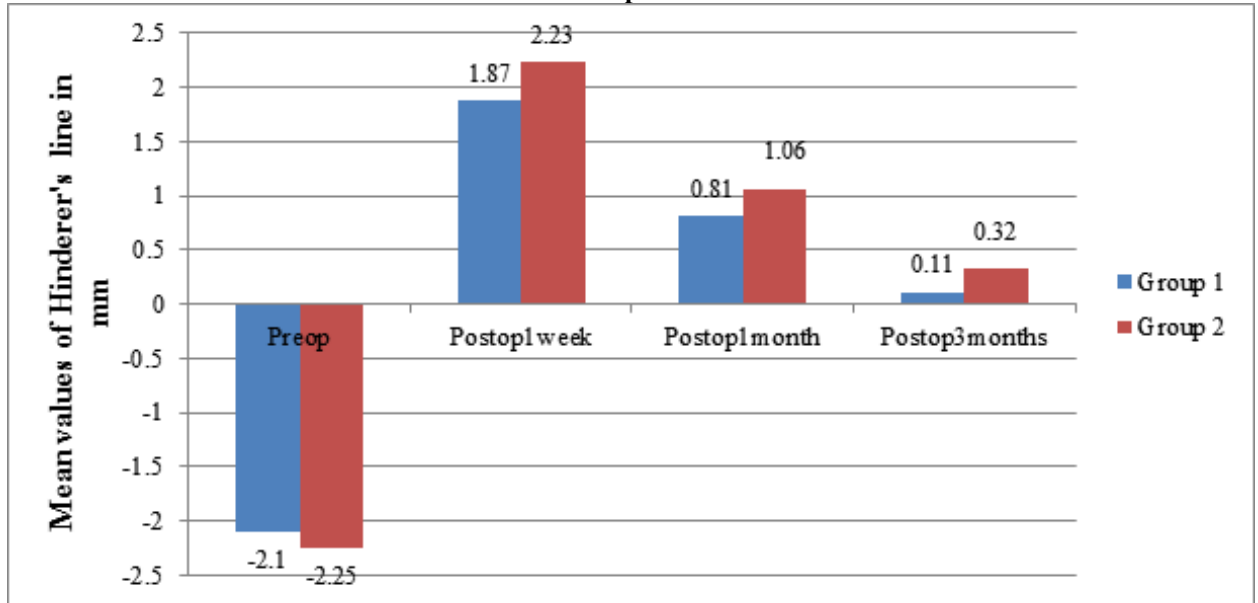
Tables & Graphs

Table 1 shows intergroup comparison on the basis of malar prominence. There was no significant difference between the 2 groups at any interval.

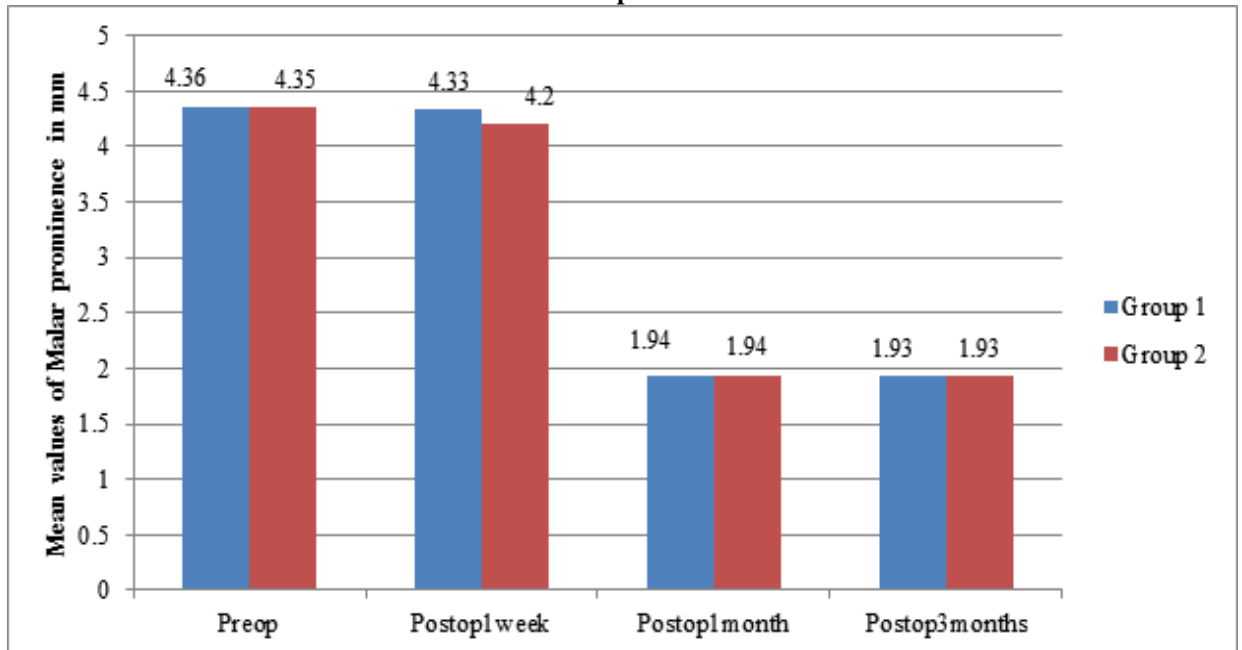
Table 2:

Interval	Group 1 (Mean±SD)	Group 2 (Mean±SD)	p-value
Preop	4.36±0.72	4.35±0.74	.961
Postop 1 week	4.33±0.72	4.2±0.79	.619
Postop 1 month	1.94±0.32	1.94±0.32	.987
Postop 3 months	1.93±0.32	1.93±0.32	.996

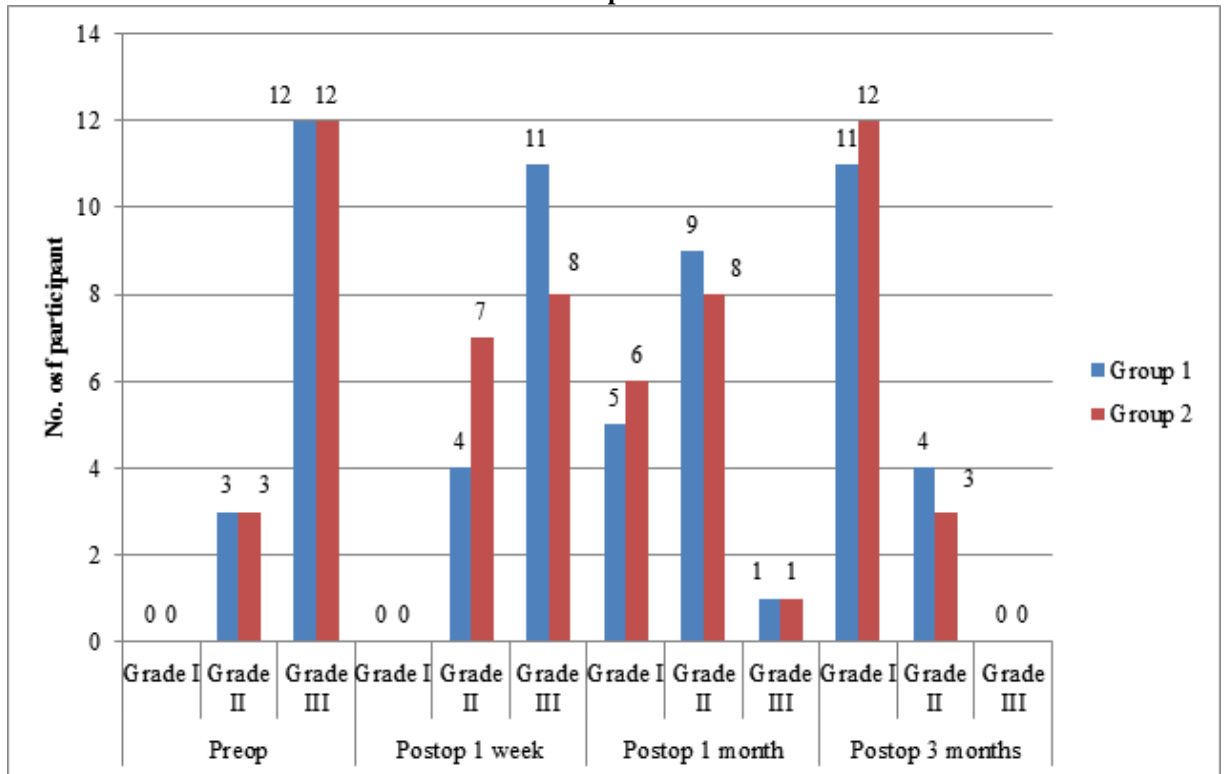
Graph 1:



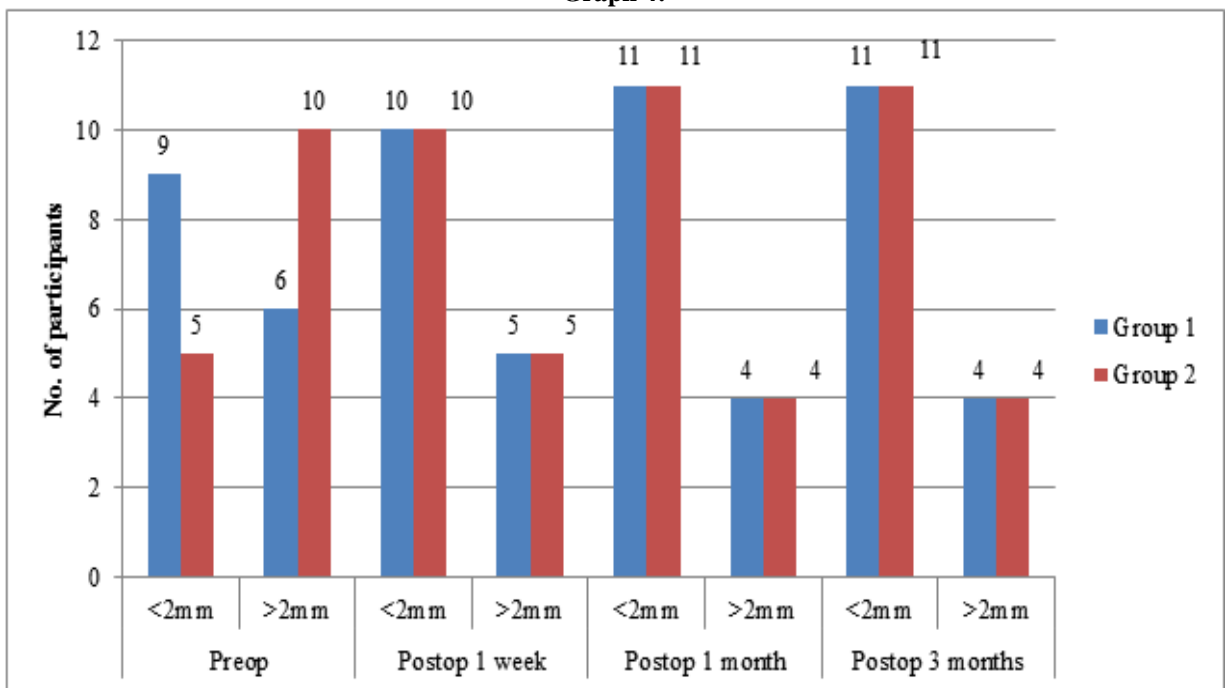
Graph 2:



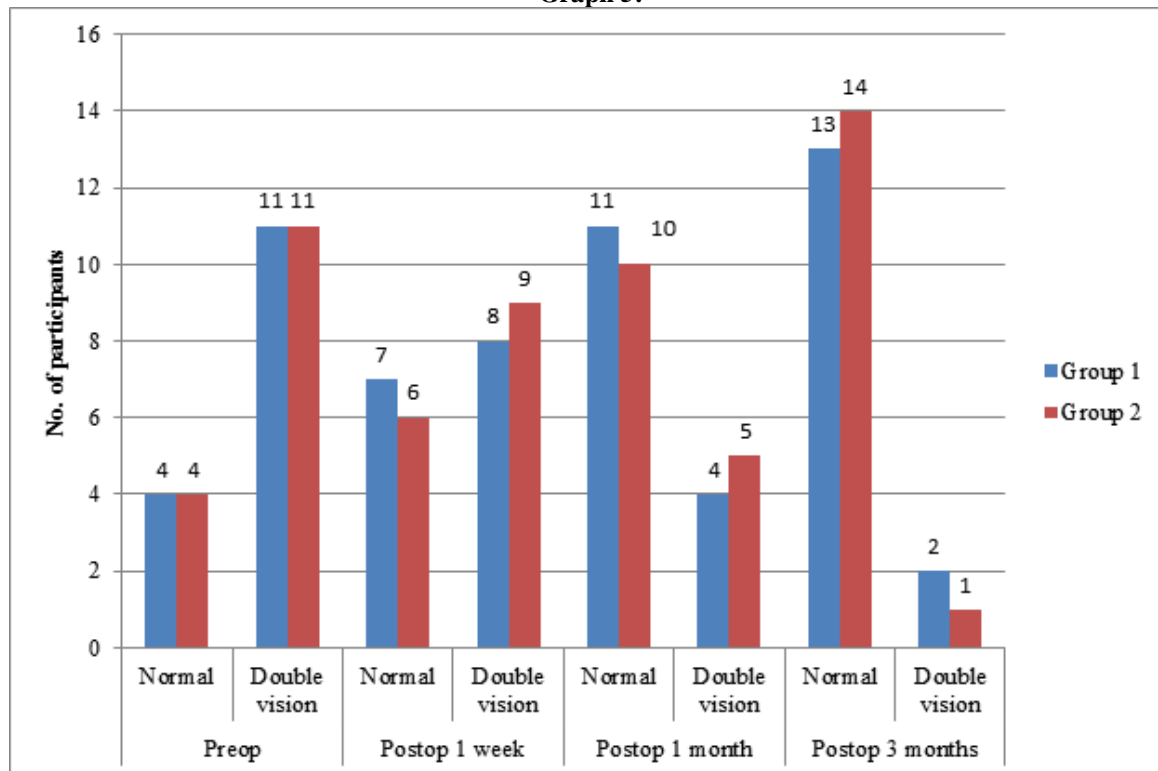
Graph 3:



Graph 4:



Graph 5:



References

- Punjabi SK, Channar KA. Isolated zygomatic bone fracture: management by three point fixation. *Professional Med J* 2016; 23(5):526-30.
- Lee PK, Lee JH, Choi YS, et al. Single transconjunctival incision and two point fixation for the treatment of non-comminuted zygomatic complex fracture. *J Korean Med Sci* 2006;21:1080.
- Kim ST, Go DH, Jung JH, Cha H.E, Woo J.H, Kang G. Comparison of I point fixation with 2 point fixation in treating tripod fractures of zygoma. *J Oral Maxillofac Surg* 2011; 69:2848-2852.
- Zachariades N, Mezitis M, Anagnostopoulos D. Changing trends in the treatment of zygomatic maxillary complex fracture treatment. *Int J Oral and Maxillofacial Surgery* 1998;30(5):380-383.
- Chakranarayan A, Thapliyal GK, Sinha R, Menon SP. Efficacy of two point rigid internal fixation in the management of zygomatic complex fracture. *J Maxillofacial Oral Surg* 2009;8(3):265-269.
- Parashar A, Sharma RK, Makkar S. Rigid internal fixation of zygoma fractures: A comparison of two point and three point fixation. *J Plast Surg* 2007;40(1).
- Zing M Laedrach K, Chowdhury K, Vullemin T, Sulter F, Raveh J. Treatment of 813 zygoma lateral orbital complex fractures. *Arch Otolaryngol Head Neck Surgery* 1991;117(6):11-620.
- Yonehara Y, Hirabayashi S, Ishii H. Treatment of zygomatic fractures without inferior orbital rim fixation. *J Craniofac Surg* 2005;16(3):481-485.
- Holmes KD, Mathew L. Three point alignment of zygomatic fracture with miniplate fixation. *Arch Otolaryngol Head Neck Surg* 1989; 115(8):961-963.
- Ulgesic V, Virag M, Aljinovic N, Macan D. "Evaluation of mandibular fractures". *J of Cranio-Maxillo-Facial Surgery*. 1993;21:251-257.
- Ellis E 3rd, Kittidumkerng W "Analysis of treatment for isolated zygomaticomaxillary complex fractures" *J of Oral and Maxillofacial Surgery*.1996 Apr; 54(4):386-401.
- Kawai T. et al. "Radiographic changes during bone healing after mandibular fractures" *British Journal of Oral and Maxillofacial Surgery* 1997;35:312-318.
- Shumrick, Kersten R, Kulwin. "Criteria for selective management of the Orbital Rim and Floor in Zygomatic Complex and Midface Fractures". *Arch Otolaryngology Head Neck Surgery* 1997;123:378-384.
- Yoshiyuki, Hirabayashi, Shinichi "Treatment of Zygomatic Fractures without Inferior Orbital Rim fixation" *J of Craniofacial surgery*. 2005;16(3):481-485.
- Zhang J, et. al. "Maxillofacial injury severity score: proposal of a new scoring system" *International J of Oral and Maxillofacial Surgery*.2006;35:109-114.
- Parashar A, Sharma RK, Makkar S "Rigid internal fixation of zygoma fractures: A comparison of two-point and three-point fixation" *Indian Journal of Plastic Surgery* 2007;40:18-24.
- Makowski GJ, Joseph E Van S, San A " Evaluation of results with 3 point visualization of zygomaticomaxillary complex fracture" *OOO*, 2013;21:251-257.
- Furst IM, Austin P, Pharoah M. The use of computed tomography to define zygomatic complex position. *J Oral MaxillofacSurg* 2001;59(6):647-54.
- Kovacs AF, Ghahremani M"Minimization of Zygomatic complex fracture Treatment" *International J of Oral and Maxillofacial Surgery*. 2001;30:380-383.
- Gandi LN, Kattimani VS, Gupta AV, Chakravarthi VS, Meka SS. Prospective blind comparative clinical study of two point fixation of zygomatic complex fracture using wire and mini plates. *Head Face Med* 2012;8(7):1-4.
- Covington DS, Wainwright DJ, Teichgraeber JF, Parks DH. Changing patterns in the epidemiology and treatment

- of zygoma fractures: 10-year review. *J Trauma* 1994;37(2):243-248.
22. Chakranarayan A, Thapiyal GK, Sinha R, Suresh MP. Efficacy of two point rigid internal fixation in the management of zygomatic complex fracture. *J Maxillofac Oral Surg* 2009;8(3):265-269.
 23. Ogata H, Sakamoto Y, Kishi K. A new classification of zygomatic fracture featuring zygomaticofrontal suture: injury mechanism and a guide to treatment. *Int J Plast Surg* 2013;2013:1-6.
 24. Kovacs AF, Ghahremani M. Minimization of zygomatic complex fracture treatment. *Int J Oral Maxillofac Surg* 2001;30(5):380-3.
 25. Zachariades N, Mezitis M, Anagnostopoulos D. Changing trends in the treatment of zygomaticomaxillary complex fractures: A 12-year evaluation of methods used. *J Oral and Maxillofac Surg* 1998; 56(10):1152-6.
 26. Yonehara Y, Hirabayashi S, Tachi M, Ishii H. Treatment of zygomatic fractures without inferior orbital rim fixation. *J Craniofac Surg* 2005;16(3):481-5.
 27. Eisele DW, Duckert LG. Single-point stabilization of zygomatic fractures with the minicompression plate. *Arch Otolaryngol Head Neck Surg* 1987;113(3):267-70.
 28. MacLennan WD. Fractures of the malar (zygomatic) bone. *J R Coll Surg Edinb*. 1977; 22(3):187-89.
 29. Melmed EP. Fractures of the zygomatic-malar complex. *S Afr Med J* 1972; 46(19):569-72.
 30. Forouzanfar T, Salentijn E, Peng G, Bergh BV. A 10-year analysis of the "Amsterdam" protocol in the treatment of zygomatic complex fractures. *Journal of Cranio-Maxillo-Facial Surgery* 2013;1-7.