

## Ocular manifestations of systemic lupus erythematosus- A retrospective study

Natasha Radhakrishnan<sup>1</sup>, Gopal S Pillai<sup>2,\*</sup>

<sup>1</sup>Associate Professor, <sup>2</sup>Professor, Dept. of Ophthalmology, Amrita Institute of Medical Sciences, Amrita Vishwa Vidya Peetham, Kochi, Kerala, India

**Corresponding Author:**

Email: gopalspillai@gmail.com

### Abstract

Systemic lupus erythematoses is a multisystem disorder with varied ocular manifestations these often go missed if asymptomatic and some of them can be vision threatening if ignored. This study aims to shed light on the ocular manifestations, incidence and complications so that ophthalmologists can be aware.

**Keywords:** Ocular manifestations, SLE, Systemic lupus erythematoses.

### Introduction

Systemic lupus erythematoses is a complex multisystem disorder that has many ophthalmic manifestations. The ocular features of SLE are protean and range from the common keratoconjunctivitis sicca or dry eye to the relatively rare and vision threatening vasooclusive vasculitis. The ocular manifestations can be a marker of systemic disease activity as well as causing significant morbidity to the patient.

### Aims of the study

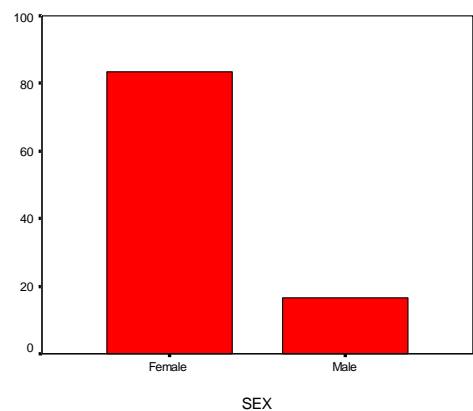
1. To evaluate the prevalence of various ocular manifestations in diagnosed cases of SLE.
2. To study the association between vasooclusive vasculitis and presence of anti-phospholipid antibodies.
3. To study the association between retinal manifestations and presence of lupus nephritis.

### Materials and Methods

100 cases of diagnosed cases of SLE seen in our institute in the period between January 2012 and January 2016 were included in the study. The diagnosis of SLE was essentially clinical and was based on the presence of four or more of the 11 features listed by the American College of Rheumatology classification criteria (ACR/ARA)<sup>(1)</sup> A retrospective cross sectional analysis was done. The electronic medical records data was analysed with respect to visual acuity (snellen acuity), schirmer tests, anterior segment slit lamp examination findings and dilated fundus examination for posterior segment eye manifestations, and neuroophthalmic manifestations. Data regarding presence of lupus nephritis and anti-phospholipid antibodies was also noted. Statistical analysis was done using SPSS version 11 and test for association done with chi square test.

### Results

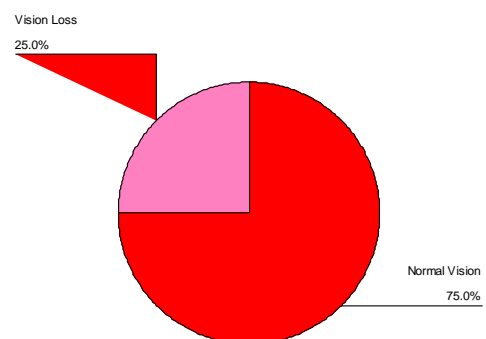
83 females and 17 males were included in the study. (Fig. 1) Age group ranged from 12 years to 55 years with mean age of 32.25 and std deviation 11.013.



**Fig. 1**

5 patients had normal visual acuity of 6/6 both eyes and 25 patients had decreased vision in at least one eye. Of the patients with decreased vision, 16 (16%) had visual acuity between 6/9 to 6/36 and 9 had visual acuity <6/36. (Fig. 2)

Pie chart showing Normal vision and vision loss



**Fig. 2**

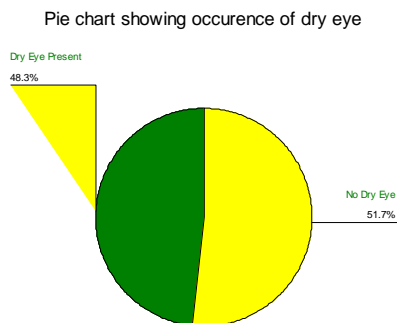


Fig. 3

The most common ocular manifestation was keratoconjunctivitis sicca (schirmer <10mm in 5 mts) which was seen in 48% patients. (Fig. 3) Episcleritis/scleritis was seen in 27 % patients. 8% had cataract which was posterior subcapsular type in all the patients.

Posterior segment manifestations included lupus retinopathy which consisted of cotton wool spots, venous dilatation and tortuosity and vasculitis predominantly arterial. This in various grades was seen in 24% patients. (Fig. 4) The more visually significant vasooclusive vasculitis was seen in 6% patients—these patients had significant ischemia which went onto develop proliferative retinopathy.

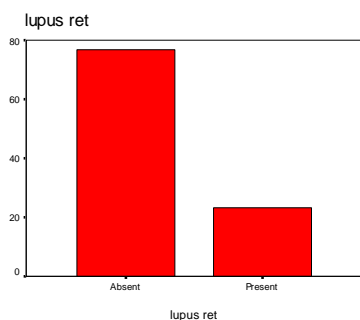


Fig. 4

Neuroophthalmic manifestations included optic neuritis in 2% and cranial nerve palsy in 6% patients. (Fig. 5)

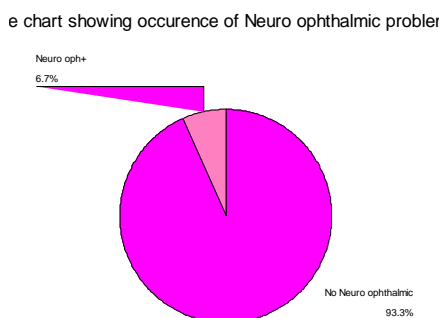


Fig. 5

Antiphospholipid antibody positivity was seen in 8 % patients in the entire group. Association between APLA positivity and vasoocclusive vasculitis was assessed using the chi square test and was found to significant (p<0.001).

45% of the patients had some grade of lupus nephritis. However association between nephropathy and either lupus retinopathy or vaso occlusive vasculitis was not found to be statistically significant.

### Discussion

Ocular manifestations in SLE are quite common and can sometimes be vision threatening. They may also often be the first manifestations of the disease.<sup>(2,3)</sup> SLE can affect any part of the eye and visual pathway. Also, some ocular manifestations can result from the use of some drugs in the treatment of SLE like hydroxychloroquine and steroids.

Foster et al found dry eye syndrome (keratoconjunctivitis sicca) is the most common ocular feature of SLE (around a third of patients) and is often associated with secondary Sjogren’s syndrome.<sup>(5)</sup> We had a very high incidence of 48% of dry eyes making it the most common manifestation in our study.

Orbital masses, periorbital oedema, orbital myositis, panniculitis, acute orbital ischaemia are other orbital manifestations but these are rare.

Episcleritis/scleritis was seen in 27% of our patients. These can be the first signs of the disease.<sup>(6)</sup> Episcleritis presents with mild, irritation and redness with dilatation of the superficial blood vessels. Scleritis is a more painful condition and if not treated adequately can cause loss of vision.<sup>(7)</sup> Anterior uveitis often occurs along with other inflammatory signs.

10% of SLE patients have retinal manifestations. It does not cause any problem when mild but severe disease can result in loss of vision and defective fields. Any such signs should prompt a referral to the ophthalmologist. The retinal signs are a marker for the intensity of systemic inflammation, and may indicate disease activity according to Arevalo et al.<sup>(8,9)</sup> We had a higher incidence 24% and 6% required treatment aggressively. APLA predisposes to vascular occlusions and more ocular morbidity.<sup>(10)</sup> Mild lupus retinopathy consists of cotton-wool spots, perivascular hard exudates, retinal haemorrhages and vascular tortuosity<sup>(11)</sup> later, there may be focal or generalized arteriolar constriction and venous tortuosity. In the severe stage, retinal arterioles get occluded and causes retinal infarction.this is called vaso-occlusive retinopathy or ‘retinal vasculitis’.<sup>(12,13)</sup> 72% of such cases result in proliferative retinopathy along with vitreous haemorrhage, or traction retinal detachment. Our study had 8% APLA positive patients.

Optic nerve disease occurs in around 1% of patients with SLE,<sup>(15)</sup> as found by Georgi et al. Our study had a 2% incidence of optic neuritis and 6% cranial nerve palsies.

**Table 1: Comparison with other studies**

	Ostaneck et al, Poland, 2007 (16)	Yap et al, Singapore, 1998 (17)	Our study
KCS	57.3%	64%	48%
Cataract		10%	8%
Retinopathy	20%	13%	24%
Occlusive vasculopathy		4.3%	6%
Decreased visual acuity	22.6%	10%	25%

There is a paucity of published studies on SLE from our country and most of the comparable studies are from Poland where there is a relatively high incidence of SLE and from Singapore and Japan. Our study had a comparable incidence of dry eye, decreased visual acuity and retinopathy compared to the Polish study by Ostaneck et al. However the study in Singapore by Yap et al had a much higher incidence of dry eyes and lower retinopathy and decreased visual acuity. (Table 1) This could be explained on the basis that being a multi-speciality hospital our department tends to see patients with a higher disease activity index and patients on longterm immunosuppression. The strong association between antiphospholipid antibody positivity and vasoocclusive vasculopathy has been seen in several other studies by Coppetto et al and Jabs et al and many others.<sup>(10,11,18,19)</sup> This was found to be strongly significant in our study. Retinal vascular abnormalities are found to be increased in patients with raised serum creatinine. However this was not found to be a statistically significant association in our study.

The diagnosis of SLE is established if 4 of the 11 American College of Rheumatology criteria are met. Although SLE often has ocular manifestations and is many times the first clinical sign ocular lesions are not included among the 11 diagnostic criteria.<sup>(2)</sup>

Ophthalmic problems maybe an indicator of disease activity, and this has caused it to be part of the British Isles Lupus Assessment Group index of disease activity (BILAG 2004).<sup>(20)</sup>

**Conclusion**

The most common ocular manifestation of SLE is keratoconjunctivitis sicca or dry eyes. The vision threatening manifestation is vasoocclusive vasculitis. There is a strong association of vasoocclusive vasculitis and APLA positivity.

We could not find a significant association of lupus nephritis with retinal vascular involvement.

SLE is a chronic inflammatory, autoimmune multisystem disorder that has significant ocular findings. There is a paucity of studies on the ocular manifestations of this disorder in Indian population. This study is a small step in that direction to fill this gap. However larger studies with better cooperation between departments of rheumatology, internal

medicine and nephrology will be required to elaborate further data on this disorder.

**References**

1. Tan EM, Cohen AS, Fries JF et al. The 1982 revised criteria for classification of systemic lupus erythematosus. *Arthritis Rheum* 1982;25:1271-7.
2. Nguyen QD, Foster CS. Systemic lupus erythematosus and the eye. *Int Ophthalmol Clin* 1998;38:33-60.
3. Peponis V, Kytтарыs VC, Tyradellis C, Vergados I, Sitaras NM. Ocular manifestations of systemic lupus erythematosus: a clinical review. *Lupus* 2006;15:3-12.
4. Read RW. Clinical mini-review: systemic lupus erythematosus and the eye. *Ocul Immunol Inflamm* 2004;12:87-99.
5. Foster CS. Immunosuppressive therapy for external ocular inflammatory disease. *Ophthalmology* 1980;87:140-50.
6. Hakin KN, Watson PG. Systemic associations of scleritis. *Int Ophthalmol Clin* 1991;31:111-29.
7. Gold DH, Morris DA, Henkind P. Ocular findings in systemic lupus erythematosus. *Br J Ophthalmol* 1972;56:800-4.
8. Arevalo JF, Lowder CY, Muci-Mendoza R. Ocular manifestations of systemic lupus erythematosus. *Curr Opin Ophthalmol* 2002;13:404-10.
9. Durrani OM, Gordon C, Murray PI. Primary antiphospholipid antibody syndrome (APS): current concepts. *Surv Ophthalmol* 2002;47:215-38.
10. Coppetto J, Lessel S. Retinopathy in systemic lupus erythematosus. *Arch Ophthalmol* 1977;95:794-7.
11. Jabs DA, Fine SL, Hochberg MC, Newman SA, Heiner GG, Stevens MB. Severe retinal vaso-occlusive disease in systemic lupus erythematosus. *Arch Ophthalmol* 1986;104:558-63.
12. Hall S, Buettner H, Luthra HS. Occlusive retinal vascular disease in systemic lupus erythematosus. *J Rheumatol* 1984;11:846-50.
13. Giorgi D, Pace F, Giorgi A, Bonomo L, Gabrieli CB. Retinopathy in systemic lupus erythematosus: pathogenesis and approach to therapy. *Hum Immunol* 1999;60:688-96.
14. Hochberg MC, Boyd RE, Ahearn JM et al. Systemic lupus erythematosus: a review of clinico-laboratory features and immunogenetic markers in 150 patients with emphasis on demographic subsets. *Medicine* 1985;64:285-95.
15. Jabs DA, Miller NR, Newman SA, Johnson MA, Stevens MB. Optic neuropathy in systemic lupus erythematosus. *Arch Ophthalmol* 1986;104:564-8.
16. Ocular manifestations in patients with systemic lupus erythematosus and antiphospholipid syndrome. *Pol Arch Med Wewn.* 2007;117 Suppl:18-23 Ostaneck L, Modrzejewska M, Bobrowska-Snarska D, Brzosko M.
17. Ophthalmic Manifestations in Asian Patients with Systemic Lupus Erythematosus E Y Yap, K G Au Eong, K Y Fong, H S Howe, M L Boey, W M Cheah, P H Feng *Singapore Med J* 1998; Vol 39 (12):557-559.
18. Ravelli A, Di Fuccia G, Caporali R, Malvezzi F, Montecucco C, Martini A. Severe retinopathy in systemic lupus erythematosus associated with IgG anticardiolipin antibodies. *Acta Paediatr* 1993;82:624-6.
19. Asherson RA, Merry P, Acheson JF, Harris EN, Hughes GR. Antiphospholipid antibodies: a risk factor for occlusive ocular vascular disease in systemic lupus erythematosus and the 'primary' antiphospholipid syndrome. *Ann Rheum Dis* 1989;48:358-61.

20. Isenberg DA, Rahman A, Allen E et al. BILAG 2004. Development and initial validation of an updated version of the British Isles Lupus Assessment Group's disease activity index for patients with systemic lupus erythematosus. *Rheumatology* 2005;44:902–6.