

Secondary renal amyloidosis complicating psoriatic arthropathy

Shruti Chandrakar^{1,*}, Anitha Padmanabhar², Nitin M. Gadgil³

¹Senior Resident, ²Assistant Professor, ³Associate Professor, Dept. of Pathology, Lokmanya Tilak Municipal Medical College, Sion, Mumbai, India

***Corresponding Author:**

Email: shrutchandrakar9388@gmail.com

Abstract

Introduction: Secondary AA amyloidosis is a classical complication of chronic inflammatory conditions like rheumatoid arthritis, ankylosing spondylitis and inflammatory bowel disease or chronic infectious diseases like tuberculosis, bronchiectasis and chronic osteomyelitis. Amyloidosis is an extremely rare complication of psoriatic arthritis and is associated with a poor prognosis.¹⁻³

Materials and Methods: We report a case of a 42 year old male, a known case of psoriasis since 1 year and on methotrexate 15mg /day since 6 month in view of psoriatic arthropathy. Laboratory findings revealed urinary spot protein in the nephrotic range along with hyperlipidemia, hypoproteinemia and albuminuria suggestive of nephrotic syndrome. USG guided renal biopsy revealed renal amyloidosis with congo red positivity showing apple green birefringence. Patient expired within 48 hours after renal biopsy due to pneumonia. Complete autopsy was performed and histopathology showed amyloidosis restricted to the kidneys.

Result: USG guided renal biopsy revealed renal amyloidosis with congo red positivity showing apple green birefringence. Patient expired within 48 hours after renal biopsy due to pneumonia. Complete autopsy was performed and histopathology showed amyloidosis restricted to the kidneys.

Conclusion: Amyloidosis should be considered in patients with long-standing severe psoriasis and psoriatic arthropathy who develop renal symptoms and there can be rapid onset of amyloidosis after the first articular signs. Prognosis is usually poor.

Keywords: Psoriatic nephropathy, Renal amyloid, Secondary amyloidosis.

Received: 29th July, 2017

Accepted: 30th August, 2017

Introduction

Secondary AA amyloidosis is a classical complication of chronic inflammatory conditions like rheumatoid arthritis, ankylosing spondylitis and inflammatory bowel disease or chronic infectious diseases like tuberculosis, bronchiectasis and chronic osteomyelitis.¹⁻³

Secondary renal amyloidosis in psoriatic arthropathy and drug-induced renal lesions secondary to methotrexate are accepted accompaniments of psoriasis.³⁻⁵ Amyloidosis is an extremely rare complication of psoriatic arthritis and is associated with a poor prognosis. We report a case of a 42 year old male patient with psoriatic arthropathy and nephrotic syndrome with secondary amyloidosis.

Materials and Methods

A 42 year old male patient admitted as a previously diagnosed case of psoriatic arthritis. The patient had pain & edema over lower limbs, ankle joint, knee joint and dorsum of the hands since six months which exaggerated since 20 days. Patient was receiving methotrexate 15mg weekly dose since last 6 months for the same.

Besides the arthropathy patient also had dermatological manifestations in the form of scaling and erythematous plaques over both lower & upper extremities.

Result

On clinical examination –patient was normotensive and systemic examination was unremarkable.

Biochemical investigations were as follows: Urinary spot protein 1639.4mg/dl (normal range- 5-25mg/dl), spot creatinine- 155.4mg/dl (normal range 20-370mg/dl), protein & creatinine ratio 10.5 (normal range 22-128). total protein- 4.6g/dl (normal range 6-7.8g/dl), albumin 0.9 (normal range 3.2-4.5g/dl), 24 hour Urinary protein 4 gm/day (normal range-less than 150 mg/day) serum triglyceride 199mg/dl (normal range 10-90mg/dl), serum cholesterol-258mg/dl (normal range 150-250 mg/dl) Blood Urea Nitrogen -26.67mg/dl (normal range 8-23 mg/dl), Creatinine-0.81mg/dl (normal range 0.6-1.2mg/dl).

Random blood sugar-82.9mg/dl (normal range- 70-130mg/dl), Total bilirubin- 0.6 mg/dl (normal range 0.1-1.2 mg/dl), Aspartate transaminase -

2U/L(normal range 8-33U/L), alanine transaminase-9U/L(normal range 4-36U/L), complete blood picture revealed mild anemia with polymorpholeukocytosis, serum sodium 140mEq/L(normal range 136-142 mEq/L),serum potassium-3.4(normal range 3.8-5 mEq/L)

Urine routine microscopy was as follows-5ml, reddish, clear, acidic reaction, albumin +++, sugar -nil, granular casts+, occasional pus cells seen, 2-3 Red Blood Cells 's/HPF.

XRAY chest showed right sided minimal pleural effusion. USG Abdomen revealed fatty liver, bilateral medical renal disease and mild ascites.

A ultrasonograph guided renal biopsy showed renal amyloidosis with congo red positivity showing apple green birefringence. Patient developed high grade fever and breathlessness and died two days after the renal biopsy and a complete autopsy was performed.

At autopsy-External examination revealed erythematous plaques were present throughout upper & lower limbs,with associated edema.

Internal examination revealed bilaterally swollen kidneys, with easily stripped off capsule.

Other organs were unremarkable on gross examination.

On histopathological examination-Kidneys -most of the glomeruli showed mesangial matrix and focal glomerular sclerosis, few showed global sclerosis, tubules showed cloudy changes, interstitium showed focal mononuclear inflammatory infiltrate. There was evidence of amyloidosis which revealed congo red positivity with apple green birefringence.

Other organs like intestine, liver, spleen, heart were unremarkable & showed no evidence of amyloidosis on histopathology. Lung showed features of bronchopneumonia.

Cause of death was ascertained as respiratory failure due to bronchopneumonia with secondary renal amyloidosis in a case of psoriatic arthropathy.

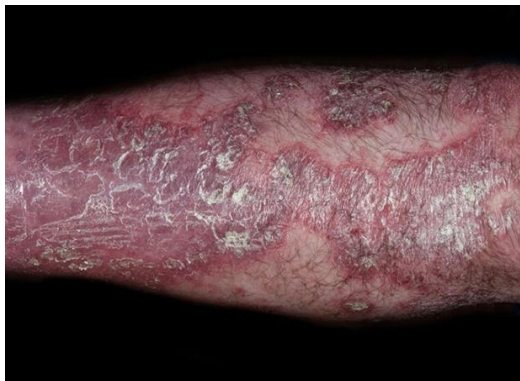

Fig. 1: external examination at autopsy revealed psoriatic scales

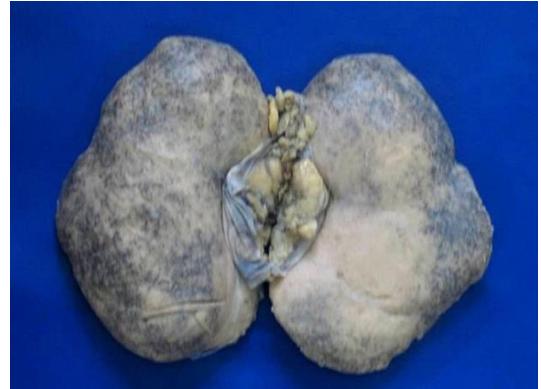

Fig. 2: Gross photograph of large white kidney suggestive of renal amyloidosis

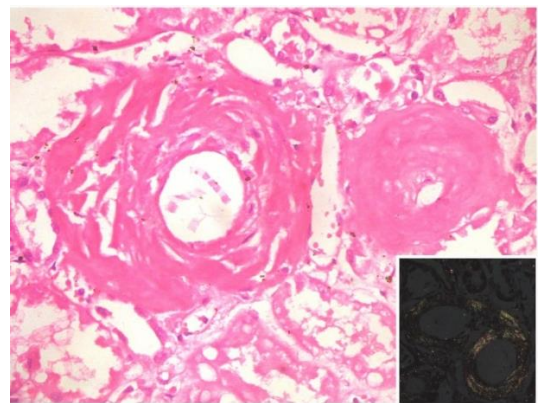


Fig.3: Photomicrograph showing section of kidney showing amyloid deposit in vessel wall.(H & E X400) Inset shows apple green birefringence on polarising microscopy (Congo red X 400)

Discussion

Amyloid is classically divided into primary and secondary types; the former is idiopathic or associated with multiple myeloma and the latter follows a variety of conditions commonly of a chronic inflammatory or malignant nature. These two forms of amyloid differ in chemical composition. In this case there was no clinical or laboratory evidence of multiple myelomatosis; psoriatic arthropathy was present and amyloid was subsequently identified in a renal biopsy before their onset. In view of medical renal disease association between psoriasis and amyloidosis was considered. Amyloidosis has only rarely been diagnosed in association with psoriasis usually as the result of renal involvement.

The patient described in this paper had a long history of psoriasis arthropathy. Qureshi et al and Mackie et al also had similar finding of amyloidosis with renal involvement in long standing psoriasis similar to present study. His

death was caused by renal amyloidosis and vascular amyloid deposits were considered a contributory factor.

Conclusion

The renal biopsy proved amyloidosis which is considered secondary, developed on the basis of psoriatic arthritis. The clinical course and the histologic findings from the renal biopsy point to serious structural disorders of the renal parenchyma which determine the progressing tendency toward chronic renal failure.

References

1. David M, Abraham D, Weinberger A, Feuerman EJ. Generalised pustular psoriasis, psoriatic arthritis and nephrotic syndrome associated with systemic amyloidosis. *Dermatologica*. 1982 Sep;165(3):168-71.
2. Taylor R, Morgan JM, Davie RM. Renal Amyloidosis secondary to psoriatic arthropathy. *Br J Clin Pract*. 1981 Nov-Dec;35(11-12):410-1,414.
3. Ahmed Q, Chung-Park M, Mustafa K, Khan MA. Psoriatic spondyloarthropathy with secondary amyloidosis. *J Rheumatol*. 1996 Jun;23(6):1107-10.
4. Bergis M, Dega H, Planquois V, Benichou O, Dubertret L. [Amyloidosis complicating psoriatic arthritis]. *Ann Dermatol Venereol*. 2003 Nov;130(11):1039-42.
5. Komatsuda A, Wakui H, Ohtani H, Maki N, Nimura T, Takatsu H, Yamaguchi A, Imai H, Sawada K. Amyloid A-type renal amyloidosis in a patient with sarcoidosis: report of a case and review of the literature. *Clin Nephrol*. 2003 Oct;60(4):284-8.
6. Mackie et al. Pustular psoriasis in association with renal amyloidosis. *British Journal of Dermatology*. 1974;90:567.
7. Qureshi et al. Amyloidosis complicating psoriatic arthritis. *British Medical Journal*. 1977;2:302.