

Treatment of metaphyseal distal radius fractures in children by Sauve Kapandji's intrafocal reduction method and K-wiring- A retrospective analysis

Mallanagouda N Patil^{1*}, Satish D Patil²

¹Assistant Professor, ²Professor, Dept. of Orthopaedics, Belagavi Institute of Medical Sciences
Belagavi, Karnataka, India

***Corresponding Author:**

Email: mnpatil@gmail.com

Abstract

Fractures of distal radius in metaphyseal region in paediatric age are one of most common orthopaedic injuries in the paediatric emergency department.^{1,2} The distal radius is considered as most common fracture site in the forearm fractures, accounting for 20–30%.^{3,4} The presence of epiphysis, adjacent to the fracture, poses challenge in managing these fractures by conservative or operative means. There are concerns about the maintenance of reduction in conservative treatment, ability of the bone to completely remodel after malunion, especially fractures in children over the age of 10 years. In this study, the distal radius paediatric metaphyseal fractures, which were grossly displaced and/ or angulated were treated using Sauve Kapandji's reduction maneuver and were fixed with two parallel or cross smooth K wires. This mode of treatment gave satisfactory correction of fracture and maintainance of reduction till the union time. Grossly displaced fractures, children over 10 years, inadequately reduced fractures, the results found to be less than satisfactory. Sauve Kapandji's method of intra focal reduction gives excellent reduction, maintainance of reduction and also predictable and reproducible results in terms of function and cosmesis. Here we are retrospectively studying 20 consecutively treated patients of distal third metaphyseal fractures of radius by using Sauve Kapandji's method of intrafocal reduction and fixation with K wiring at Belagavi Institute of Medical Sciences between Jan 2017 to Dec 2017.

Keywords: Distal radius, Metaphyseal, Sauve-Kapandji's method, Deformity.

Introduction

Fractures of distal radius in metaphyseal region in paediatric age are one of most common orthopaedic injuries in the paediatric emergency department.^{1,2} The distal radius is considered as most common fracture site in the forearm fractures, accounting for 20–30%.^{3,4} These fractures occur at the metaphysis⁵ and their presentation vary in terms of displacement and angulation. The presence of epiphysis, adjacent to the fracture, poses challenge in managing these fractures by conservative or operative means. There are concerns about the maintenance of reduction in conservative treatment, ability of the bone to completely remodel after malunion, especially fractures in children over the age of 10 years.⁶⁻⁸ While addressing these concerns, Sauve Kapandji's method of intra focal pinning, was found to be very useful.⁹

Sauve Kapandji's method of treatment for distal radius is successfully proven method in adults, but rarely used for paediatric (age ≥ 10 yrs) distal metaphyseal fractures. In this study, the distal radius paediatric metaphyseal fractures, which were grossly displaced and/ or angulated were treated using Sauve Kapandji's reduction maneuver and were fixed with two parallel or cross smooth K wires. This mode of treatment gave satisfactory correction of fracture and maintainance of reduction till the union time. Here we are retrospectively studying 20 consecutively treated patients of distal third metaphyseal fractures of radius by using Sauve Kapandji's method of intrafocal reduction and fixation with K wiring at Belagavi Institute of Medical Sciences between Jan 2017

to Dec 2017.

Materials and Methods

20 patients of distal radius metaphyseal fractures in paediatric age reporting to orthopaedic OPD of Belagavi Institute of Medical Sciences were studied. Of the 20 patients 14 were male patients and 6 were female. All the patients were between 10-14 years with average age of 12 yrs. Right radius was involved in 12 patients and 8 had left radius fractures. 14 patients had gross bayoneting and 6 had dorsal tilt.

Inclusion Criteria: Only grossly displaced and/ or angulated (more than 30 degrees), which could not be satisfactorily reduced by an attempt of closed reduction were considered for this method of treatment. All patients were above 10 years of age and open epiphysis in all cases. None of the fractures were extending into physis.

Exclusion Criteria: All the metaphyseal injuries in patients age less than 10 years were not included. Fractures which could be reduced by closed manipulation and un-displaced fractures were excluded from the study.

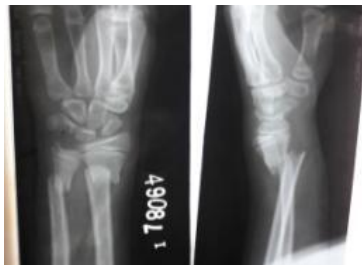Fractures with extension into epiphysis (e.g, type 2 physisal injuries) were also not included.

In this study, there were 20 patients were included. Of which 14 were male and 8 were females. Dominant limb was involved in 11 fractures and 9 fractures were on non-dominant side. 17 fractures were sustained while playing, 5 kids had fracture due to fall from bicycle and remaining 3 were due to self-fall.

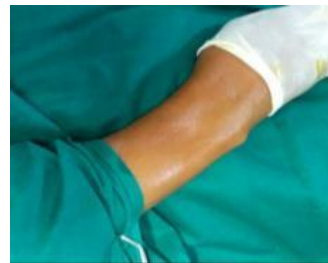Methodology

All patients above 10 years of age with gross displacement or angulation were taken for closed reduction under anaesthesia. Only those which failed closed reduction, with persistent displacement or angulation were considered for Sauve Kapandji's method of treatment. As a continuation of procedure, under image guidance, 2.5 mm K wires was inserted percutaneously into the fracture site. One from dorsal side between diaphysis and dorsally tilted or displaced distal fragment. Additional k wire on lateral side was used in fractures with lateral tilt or displacement. Both wires were simultaneously used as joysticks and fracture was hinged back to position under image intensifier. Reduction was confirmed in both antero-posterior and lateral views. Two parallel or cross K

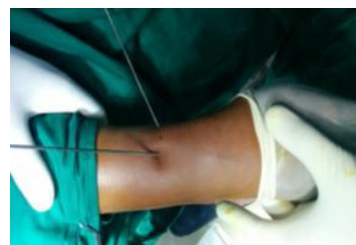wires of size 1.8mm were passed from lateral to medial direction. Position of the wires were checked under C-arm. Patients were initially put in short arm dorsal slab. Postoperative x-rays were taken, immediately after the procedure. All patients received single dose of injectable cefotaxime and were discharged on same day. On 3rd post op day, below elbow cast was applied and a window made at K wire insertion site for regular dressing. Follow up X-rays were taken at 7 days, 4 weeks, 6 weeks and 3 months post operatively. Pin site dressing was done every week. Cast was removed at 4 weeks and wrist mobilization started. At 4 weeks, on evidence of presence of callous, k wires were removed in outpatient department. Average operative time was 15 min.



Pre op X-ray



Clinical deformity



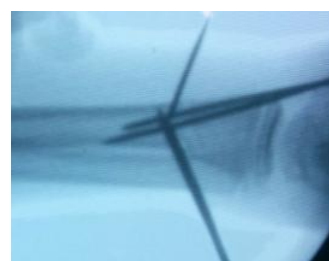Intra focal pinning clinical




C-arm image



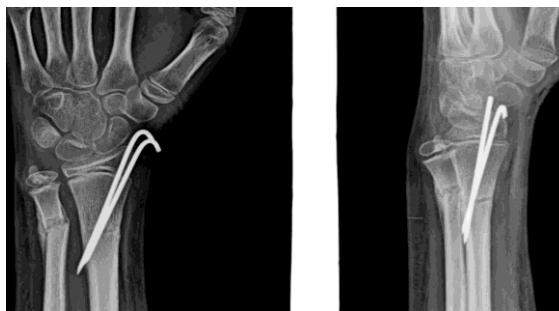Reduction & k wiring



Final AP view



Lateral view



Fracture callous at 3 wks

Results

Of the 20 patients, 18 patients followed up for three months and 2 lost to follow up after 6 weeks. Average time for bridging callous was 4 weeks. It varied from 3 weeks to 6 weeks. All patients were mobilized when x-ray showed signs of callous. On post op X-rays, 15 patients had no residual angulation and 5 had angulation of less than 5° in sagittal or coronal plane. These findings remained same. None of the patients showed any further progression of displacement till fracture healed with k wire in situ. 16 patients underwent wire removal at 4 weeks and 4 underwent wire removal at 6 weeks. Two patients had pin site infection, which settled with cefuroxime (empericay given) for 5 days. All patients had full recovery of functional range of movements.

Discussion

Distal radius metaphyseal fractures in paediatric age are one of most common injuries^{1,2} in paediatric age, accounting for 20-30%.^{3,4} These injuries are commonly managed by closed reduction and cast immobilisation and this is considered standard method of treatment.^{2,6} Some have reported good outcomes with conservative management with few complications or long-term problems;⁷ however, loss of reduction (LOR) rates between 10% and 91% have been reported by many. In general, one third of patients reported with late displacement.^{10,11}

Risk of re-displacement are found to be multifactorial.^{6,10} Some of the factors responsible for re-displacement are; Fracture-related factors such as gross initial displacement or angulation, and increased obliquity of the fracture line,^{10,12,13} residual angulation or displacement, poor casting method even after closed reduction;¹² and loosening of cast either due to reduction in swelling after cast application or muscle atrophy, which may re-displace the fracture.⁵

Widmann et al.¹⁴ found that complete metaphyseal distal radius fractures were at higher risk for LOR, and 50% of these fractures in children over ten years of age, lose initial reduction. In some studies, older patients i.e., 14 years old or more were 4.8 times more likely to lose reduction. Hence while treating older children with reduced potential for remodeling,^{15,8} loss of reduction is an important factor in predicting outcome. In an attempt

to reduce the chances of redisplacement, some recent studies have shown, improved results with percutaneous wiring.^{10,11,16} The aim of this study was to identify those high risk fractures for re-displacement and to formulate an effective method of treatment which can minimise the complications, in terms of loss of reduction and malunion.

Closed reduction and k wiring has been recommended by some, in group of patients who are at higher risk of loss of reduction.^{13,17,18} As persistent deformity can be seen after the plaster removal, among the patient with loss of reduction or inadequately reduced fractures, which doesn't instill confidence among parents. This anxiety can be compounded, if the patient is advised reattempt of procedure after failure of the initial treatment.¹¹ These factors justify closed reduction and k wiring in these high risk groups which have advantage of better maintenance of reduction till the point of fracture healing^{11,16} and fewer follow-up X-rays¹⁹ and a low rate of complications.^{13,18} Long term functional outcome of these fractures with conservative treatment are good, especially in age group less than 10 years.⁷ However for the children older than 10 years and the ones, who have difficult reductions or fractures which couldn't be reduced satisfactorily. In these Sauve kapandjis method of intra-focal reduction with supplementation with parallel/cross k wires, provides predictable outcome, prevents loss of reduction because various factors listed above.^{6,9}

Conclusion

Distal radius metaphyseal injuries are one of the most common fractures. Conventionally these have been treated by closed reduction and cast application with good results. Results among grossly displaced fractures, children over 10 years, inadequately reduced fractures, the results found to be less than satisfactory. Sauve kapandji's method of intra focal reduction gives excellent reduction, maintainance of reduction and also predictable and reproducible results in terms of function and cosmesis. Though a longer study is required to observe long term benefits and complications. This study is limited in assessing the maintenance of reduction till fracture healing. Further, Sauve Kapandji's method can be tried with larger sample size, as it is safe and reliable.

References

Orthop Scand. 1979;50:537–546.

1. Galano GJ, Vitale MA, Kessler MW, Hyman JE, Vitale MG. The most frequent traumatic orthopaedic injuries from a national pediatric inpatient population. *J Pediatr Orthop.* 2005;25:39–44.
2. Pershad J, Williams S, Wan J, Sawyer JR. Pediatric distal radial fractures treated by emergency physicians. *J Emerg Med.* 2009;37:341–344.
3. Bae DS. Pediatric distal radius and forearm fractures. *J Hand Surg Am.* 2008;33:1911–1923.
4. Rodriguez-Merchan EC (2005) Pediatric fractures of the forearm. *Clin Orthop Relat Res* 432:65–72.
5. Pretell Mazzini J, Rodriguez Martin J. Paediatric forearm and distal radius fractures: Risk factors and re-displacement-role of casting indices. *Int Orthop.* 2010;34(3):407–412.
6. Jones K, Weiner DS. The management of forearm fractures in children: A plea for conservatism. *J Pediatr Orthop.* 1999;19:811–815.
7. Do TT, Strub WM, Foad SL, Mehlman CT, Crawford AH. Reduction versus remodeling in pediatric distal forearm fractures: A preliminary cost analysis. *J Pediatr Orthop B.* 2003;12:109–115.
8. Von Laer L, Hasler C ; spontaneous corrections, growth disorders and post-traumatic deformities after fractures in the area of growing skeleton; *Handchir Mikrochir Plast Chir* 2000 jul; 32(4)231-4.
9. Kapandji IA. Internal fixation by double intrafocal plate: Functional treatment of non-articular fractures of the lower end of the radius. *Ann Chir* 1976;30:903-908.
10. Alemdaroglu KB, Iltar S, Cimen O, Uysal M, Alagoz E, Atlıhan D. Risk factors in redisplacement of distal radial fractures in children. *J Bone Joint Surg Am.* 2008;90:1224–1230.
11. Leemput W, Ridder K. Distal metaphyseal radius fractures in children: Reduction with or without pinning. *Acta Orthop Belg.* 2009;75:306–309.
12. Proctor MT, Moore DJ, Paterson JM. Redisplacement after manipulation of distal radial fractures in children. *J Bone Joint Surg Br.* 1993;75:453–454.
13. Zamzam MM, Khoshhal KI. Displaced fracture of the distal radius in children: Factors responsible for redisplacement after closed reduction. *J Bone Joint Surg Br.* 2005;87:841–843.
14. Miller BS, Taylor B, Widmann RF, Bae DS, Snyder BD, Waters PM. Cast immobilization versus percutaneous pin fixation of displaced distal radius fractures in children: A prospective, randomized study. *J Pediatr Orthop.* 2005;25:490–494.
15. Hove LM, Brudvik C. Displaced paediatric fractures of the distal radius. *Arch Orthop Trauma Surg.* 2008;128:55–60.
16. Roth KC, Denk K, Colaris JW, Jaarsma RL; Think twice before re-manipulating distal metaphyseal forearm fractures in children; *Arch Orthop Trauma Surg.* 2014, Dec;134 (12);1699-707.
17. Choi KY, Chan WS, Lam TP, Cheng JC. Percutaneous kirschner-wire pinning for severely displaced distal radial fractures in children. A report of 157 cases. *J Bone Joint Surg Br.* 1995;77:797–801.
18. Gibbons CL, Woods DA, Pailthorpe C, Carr AJ, Worlock P. The management of isolated distal radius fractures in children. *J Pediatr Orthop.* 1994;14:207–210.
19. Friberg KS. Remodelling after distal forearm fractures in children. I. The effect of residual angulation on the spatial orientation of the epiphyseal plates. *Acta*