

Anesthetic considerations in an infant with congenital cystic adenomatoid malformation

Lalit Gupta¹, Bhavna Gupta^{2*}, Anish Gupta³, Rahul Jain⁴

¹Assistant Professor, ^{2,3,4}Senior Resident, ^{1,2}Dept. of Anaesthesia, ^{3,4}Dept. of Surgery, ^{1,2,4}Maulana Azad Medical College, New Delhi, Delhi, ²All India Institute of Medical Sciences, New Delhi, Delhi, India

***Corresponding Author:**

Email: bhavna.kakkar@gmail.com

Received: 13th May, 2017

Accepted: 15th June, 017

Abstract

Congenital cystic adenomatoid malformation (CCAM) is a rare developmental disorder of lower respiratory tract in which child presents with severe respiratory distress, pneumonitis or sepsis. Anesthetic management of such children is challenging owing to hyperinflation or rupture of cystic lesions or iatrogenic pneumothorax with positive pressure ventilation, sudden hemodynamic collapse during induction, excessive bleeding and situation becomes more challenging if child is presenting with sepsis. We report successful management of 42 days old infant with CCAM with pneumonitis and sepsis who underwent lobectomy and was successfully extubated on operating table with meticulous planning and optimum perioperative management. Early extubation is desirable to avoid iatrogenic ventilator induced bronchial stump dehiscence by positive pressure ventilation.

Keywords: Anesthesia considerations, Congenital cystic adenomatoid malformation, Pneumonitis, Sepsis.

Introduction

CCAM is a congenital anomaly of the lung resulting from abnormal fetal lung development. There is increased cell proliferation but decreased apoptosis, resulting in adenomatoid proliferation and cyst formation. The lesion is connected to the airway, but a normal intrapulmonary bronchial system is missing. Blood supply is from the pulmonary circulation. CCAM classifications are based on the cyst size (Type I: cysts 2- 10 cm; Type II: cysts 0.5-2 cm; Type III: microcystic, grossly solid) as well as other histologic features. CCAMs may be diagnosed by prenatal ultrasound and can regress or increase in size. Large CCAMs may be associated with fetal hydrops and demise or with respiratory distress at birth.

Case Report

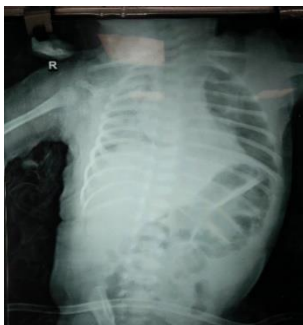

Fig. 1: Chest X RAY-suggestive of loculated radiolucent shadow without pulmonary marking in left middle and lower zone

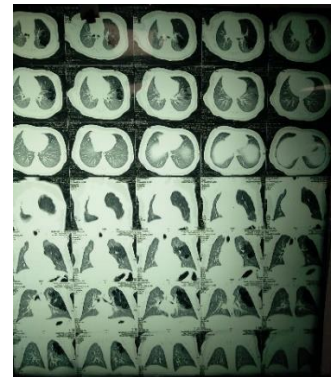


Fig. 2: HRCT chest suggestive of left upper lobe and right middle lobe CCAM

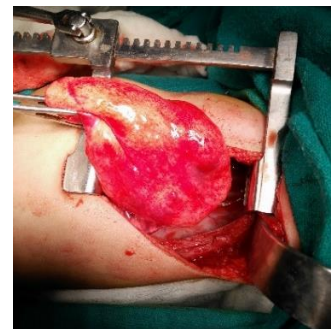

Fig. 3: Intraoperative dissection of CCAM

A three day old male baby weighing 4.2 kg with normal vaginal delivery at home, with no significant antenatal/ perinatal history, presented to pediatric emergency in respiratory distress, respiratory rate varying between 60-70/minute, high grade fever, oxygen saturations ranging between 78-95% and was

admitted in Pediatric Intensive Care Unit. He was discharged after two weeks of conservative management (bronchodilators, antibiotics) but had to be readmitted on day 35 of life, with symptoms suggestive of pneumonia. After evaluation, Chest X ray (Fig. 1) revealed loculated radiolucent shadow in mid and lower zones of left lung and High Resolution CT scan of chest (Fig. 2) showed multiple small cysts in upper lobe of left lung, largest measuring 2cm and a small cyst in right middle lobe, suggestive of congenital cystic adenomatoid malformation type II. Arterial blood gas analysis revealed respiratory acidosis (pH 7.27, pCO₂ 52, pO₂ 52, SpO₂ 84% HCO₃ 24). Child developed pneumonitis and sepsis and was put on high dose inotropic support of Noradrenaline @ 0.3 -0.4mcg/min and broad spectrum antibiotic coverage. Inotropes were gradually weaned over a week as the condition of child stabilized. He was posted for pneumonectomy/lobectomy in view of multiple cysts in left upper lobe on day 42 of life. On examination, child had respiratory rate of 50/min with suprasternal and intercostal recession, reduced air entry in bilateral lungs left > right with no gross congenital anomaly. Investigations revealed hemoglobin 10gm%, TLC 16800/mm³, platelet count 1.2 lakh/microliter, PT 15 seconds INR 1.2. Child's parents were explained about the clinical condition of the baby, high risk consent was taken from them and post-operative bed ventilator was arranged for the same. Inside the theatre, monitoring in form of electrocardiography (ECG), non-invasive blood pressure (NIBP) and pulse-oximeter was established. Arterial oxygen saturation in room air was 87%, HR 180/min, BP 68/34 mm Hg. Rapid sequence induction was done via pre-oxygenation with 100% O₂ for 4-5 minutes, intravenous injection fentanyl 8micrograms, injection thiopentone 15 mg, and deepened with sevoflurane induction 2-8%, maintaining the child on spontaneous mode of ventilation. Child was intubated with ETT 3.5 fixed at 9cm, and handed over to surgeons with left side up for left lobectomy. Anesthetic management continued with sevoflurane 2% vol, muscle relaxation was achieved with 0.5mg/kg atracurium after the chest was open, avoiding high peak airway pressure. Nitrous oxide was added after the lobe was isolated and clamped and branches of pulmonary artery and vein were ligated and divided. The emphysematous left upper lobe was excised (Fig. 3) and collapsed right and left lower lobes were allowed to expand. Child maintained haemodynamic stability throughout the procedure without any inotropic requirement. Total blood loss was 20 ml, total intravenous fluid given intraoperatively was 150ml (taking in account third space loss, blood loss, and insensible losses) for three hour duration of surgery. Adequate acid base balance in arterial gas monitoring and pain relief enabled for patient's extubation at the end of procedure. Adequate analgesia was ensured with intercostal nerve block given by surgeons under direct

vision, fentanyl 2-4micrograms every 45 minutes and 30 mg intravenous paracetamol. This provided good respiratory mechanics and early post-operative recovery with hemodynamic stability. At the completion of surgery, chest physiotherapy was given and endotracheal tube suction was done to remove any blood clot/secretions. Postoperatively chest radiograph was repeated in the evening, which revealed expanded left lung. Child was sent to pediatric high dependency unit for monitoring, was sent to pediatric ward after 24 hours, and discharged home after 5 days.

Discussion

Congenital cystic adenomatoid malformation (CCAM) or Congenital pulmonary airway malformation (CPAM) is a rare bronchopulmonary hamartomatous lesion comprising of cystic and adenomatous elements arising from tracheal, bronchial, bronchiolar or alveolar tissues.¹⁻³ Cystic intrapulmonary mass communicates with the airway but does not participate in gas exchange and may cause pulmonary infections, mediastinal shift, and pulmonary hypoplasia of remaining lung tissue. Natural history of CCAM ranges between spontaneous regressions of cyst to neonatal death secondary to pulmonary hypoplasia. Associated malformations include esophageal atresia, tracheo-esophageal fistula, renal agenesis, intestinal atresia, other pulmonary malformations, diaphragmatic, cardiac, nervous system and bony anomalies.³⁻⁵ Most common symptomatology in early infancy is respiratory distress (tachypnea, nasal flaring, intercostal retractions) or later as recurrent lower respiratory tract infections or sepsis, and some severely affected children might have pneumothorax owing to ball valve hyperinflation and overt respiratory failure. Joosten *et al.* have suggested that one should wait till pneumonitis is resolved with selective endobronchial intubation and spontaneous deflation of the hyper-expanded lung, thereby improving the pulmonary mechanics, cardiovascular function and resorption of interstitial air.⁶ On the other hand, waiting for the pneumonia to resolve may increase chances of compression atelectasis. This is due to residual pulmonary abnormalities such as pneumatoceles that can lead to localized areas of bronchial and alveolar necrosis. In ventilated infants with underlying bronchopulmonary dysplasia, these intra-pulmonary air pockets can collect large quantities of air that may evolve into either a localized lung hyperinflation or diffuse interstitial emphysema. Standard ASA monitoring with arterial catheter and central line is required if extensive blood loss and resection is expected. Inhalational induction may be delayed in these infants owing to lung pathology and intravenous induction should be preferred with minimal positive pressure ventilation or preferably deep sedated spontaneously breathing patient so as to prevent cyst from distension.⁴ Lignocaine 1-2 mg/kg, thiopentone 3-5 mg/kg, fentanyl 11-

2microgram/kg, increments of sevoflurane are recommended prior to intubation to facilitate tracheal tube placement without hemodynamic/respiratory compromise. The necessity of one lung ventilation (OLV) should be discussed with the pediatric surgical team. OLV improves surgical access, minimizes trauma to the residual normal lung and protects contralateral lung contamination. This is challenging in an infant but can be done by means of Double Lumen Tube, endobronchial intubation, selective main stem intubation or bronchial blockers or surgical retraction. After discussion with the surgeons, we decided to use normal ETT as they used lung retraction for isolation. Until thoracotomy has been done, child should be maintained on spontaneous mode of ventilation with sevoflurane in air/oxygen mixture with occasional manual assistance with minimal airway pressure. Nitrous oxide should be avoided and can be supplemented after cyst has been removed and muscle relaxation can be provided after chest and pleural are opened, and avoiding high peak airway pressure.⁵ Child should preferably be kept on Jackson Rees circuit in hand so as to know the bag compliance at various time points of surgery, Bag compliance correlate well with the steps of surgery and one can find increase in resistance on retraction of lungs by surgeons. Surgeons may be asked to release lung retraction in case bag is too tight or patient is not getting ventilated. Anesthesiologists must be vigilant with respect to endotracheal suctioning, as in many cases surgeons don't ask for one lung ventilation and spillage can occur from the operative side into endotracheal tube and cause blockade of the tube. Due to the same reason, a thorough ETT suctioning should be done in lateral decubitus position at the end of surgery and before the patient is turned supine. Thoracic epidural could not be placed in our patient owing to component of sepsis and coagulopathy and pain relief was achieved by intercostal nerve blockade at the site of incision and two segments above and below it. Early extubation is desirable to avoid iatrogenic ventilator induced bronchial stump dehiscence by positive pressure ventilation.

Conclusion

Anaesthetic intravenous induction should be preferred with minimal positive pressure ventilation or preferably deep sedated spontaneously breathing patient however; if IPPV is necessary, gentle ventilation or pressure controlled ventilation with a pressure limit of 20 cm of H₂O should be carried out until thoracotomy. A standby surgical team should be available during induction of anesthesia and nitrous oxide should be avoided till lobectomy is performed. Pain relief should be adequate by means of intravenous opioids and regional anaesthesia. Early extubation is desirable in these kids.

References

1. Chiluveru SA, Dave NM, Dias RJ, Garasia MB. Congenital pulmonary airway malformation with atrial septal defect and pulmonary hypertension for lobectomy-anesthetic considerations. *Ann Card Anaesth* 2016;19:372-4.
2. Gornall AS, Budd JL, Draper ES, et al. Congenital cystic adenomatoid malformation: accuracy of prenatal diagnosis, prevalence and outcome in a general population. *Prenat Diagn* 2003;23:997-1002.
3. Hammer GB. Pediatric thoracic anesthesia. *Anesthesiol Clin North America* 2002; 20: 153-80
4. Ahmed H, Al-Salem, Yaw Adu-Gyamfi. Congenital lobar Emphysema. *Can J Anaesth* 1990;37:377-9.
5. Ryckman FC, Rosenkrantz JG. Thoracic surgical problems in infancy and childhood. *Surg Clin NA* 1985;65:1423-54.
6. Joosten KF, Hazelzet JA, Tiddens HA, Hazebroek FW, Dzoljic-Danilovic G, Neijens HJ, et al. Staphylococcal pneumonia in childhood: Will early surgical intervention lower mortality. *Pediatr Pulmonol* 1995;20:83-8.