

Correction of scissor-bite using a removable orthodontic appliance

Ravi Bhandari^{1,*}, Shivangi Sharma², Ansar Juhi³

^{1,2}Senior Lecturer, ³Reader, Dept. of Orthodontics, Institute of Dental sciences, Bareilly, Uttar Pradesh, India

***Corresponding Author:**

Email: dr.ravi10@gmail.com

Abstract

Scissor bites is a less often encountered situation in a clinical operatory but the treatment can be challenging for a clinician. Many treatment modalities for the scissor bite are available some of which includes cross elastics, transpalatal arches. The present article describes the treatment of posterior scissor bite using a removable orthodontic appliance.

Keywords: Scissor bite, Removable appliance, Orthodontic bracket.

Introduction

Scissor bite is defined as a transversal discrepancy posteriorly in the maxilla where the palatine surface of the maxillary teeth is found in connection with the vestibular surface of the lower teeth.¹ Scissor bite can be classified as complete or incomplete. Incomplete scissor bite can be further grouped into unilateral and bilateral scissor bite.¹

Scissor bite in the posterior segment is a less frequent encountered situation in routine orthodontic practice. The treatment of scissor bite can be particularly challenging for the clinician. Several treatment modalities have been given for the correction of scissor bite, some of which includes: intermaxillary cross-elastic,² multi-bracket appliance, 2D lingual attachments, transpalatal appliance with intramaxillary elastics^{3, 4} and lingual arch appliance with intramaxillary elastics.⁵

This article describes a novel approach for the treatment of scissor bite in a 14 year old patient by using a removable orthodontic appliance.

Case Report

A 14 year old patient came to the operatory with the chief complaint of buccally placed tooth in relation to maxillary right posterior tooth region (Fig. 1 a,b,c). Due to the scissor bite, the patient was having difficulty in chewing food as the tooth was being a constant source of trauma into the cheek region. The patient was having irregularly placed teeth in upper and lower arches, but was not seeking orthodontic treatment for irregular teeth and was only concerned about the tooth in scissor bite as it was traumatizing the buccal mucosa.

The scissor bite that was present in the patient was dento-alveolar type and since the patient was not willing for fixed orthodontic treatment, the correction of the scissor bite was planned to be done by using a removable orthodontic appliance.

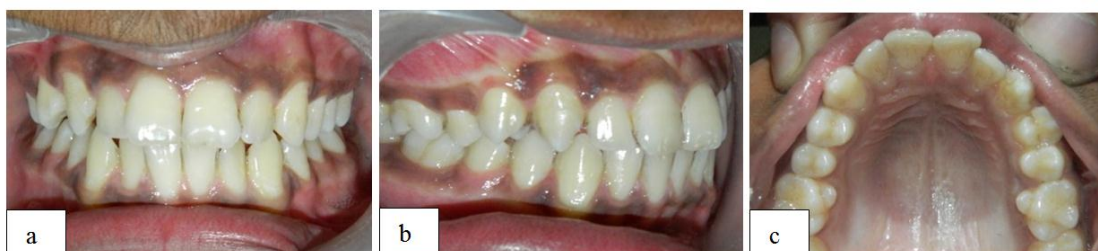

Fig 1: Pre-treatment photograph showing scissor bite irt 14 a) Front view b) Right lateral view c) Occlusal view

Appliance Design and Use

The appliance consists of a removable acrylic plate that was placed in the maxillary arch. The acrylic plate was stabilized with the help of Adam's clasp on both right and left first molars, with additional retention given by the two pin head clasps in relation to 24, 25 to avoid separation of acrylic plate against palatally directed forces (Fig 2a).

The tooth in scissor bite was the maxillary first premolar on the right side. A hook was fabricated with a 23 gauge wire and was placed in the acrylic plate during the time of acrylization of the appliance. The function of the hook was to serve as a source of attachment to an elastomeric chain to bring about the palatal movement of the premolar tooth.

An MBT (premolar) bracket (3M Gemini .022 slot metal bracket) was placed on labial aspect of 14 (Fig 2b). The palatal movement of the premolar tooth was

brought about by placing palatally directed forces with the help of an elastomeric chain. The elastomeric chain was first engaged to the palatal hook present in the acrylic plate, and it was then encircled around the tooth to be moved i.e. maxillary right first premolar tooth, the e-chain was again attached to the hook that was placed in the acrylic plate. A rectangular portion of the acrylic was removed from the palatal side of 14 so as to provide space for the palatal movement of the premolar tooth (Fig 2c).

The patient was recalled after a period of 3 weeks. The elastomeric chains was changed following the same pattern described above. The total treatment lasted for about two months and the scissor bite was completely corrected in this period of time. After a period of two months the tooth was placed into normal occlusion and the acrylic plate was removed (Fig 3 a,b).

A retention plate was given to the patient which comprises of labial bow extending to the first molar tooth (Fig 4 a,b).

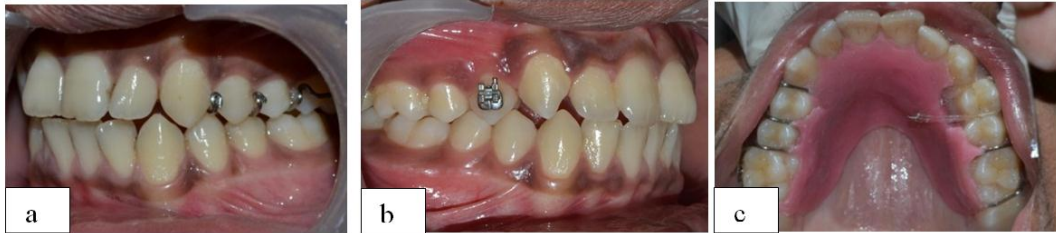

Fig 2: Appliance design a) Left lateral view showing retentive components of appliance b) Right lateral view of the patient showing bonded bracket i.r.t 14 c) Occlusal view with rectangular portion of acrylic trimmed from first premolar region

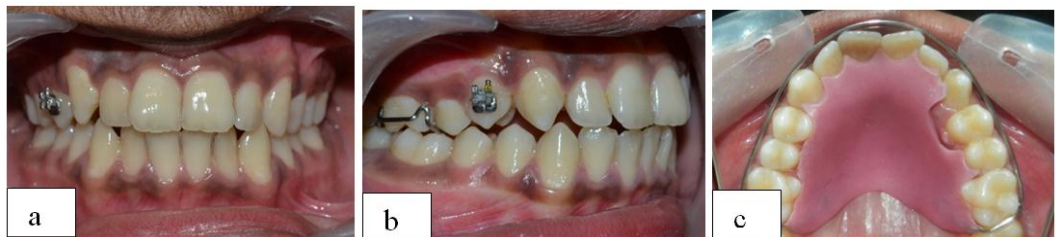

Fig 3: Photograph of the patient after 2 months of active appliance therapy a) Front view b) Right buccal view. c) Occlusal view

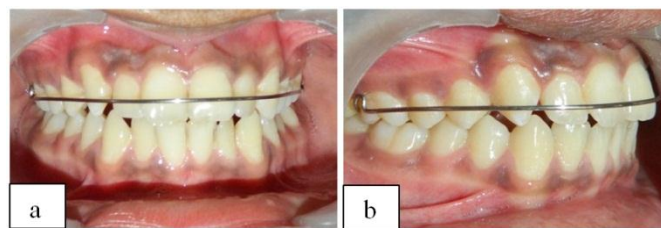


Fig 4: Photographs of the patient with retainer appliance a) Front view b) Right buccal view

Discussion

The orthodontic appliance described here is a simple and practical method of correction of teeth in scissor bite without using complicated mechanics. Its advantages include simple appliance design, patient comfort, reduced chair time, and cost-effectiveness.

References

1. Milton E. Gellin. Treatment and retention of a mandibular arch telescoped within the maxillary arch: case report. AAPD guidelines, Pediatric Dentistry: May/June, 1991 ~ Volume 13, Number 3.167-169.
2. Proffit WR, Fields JR. Contemporary Orthodontics. 3rd ed. St Louis, Mo: Mosby;1999.
3. Kucher G, Weiland FJ. Goal-oriented positioning of upper second molars using the palatal intrusion technique. Am J Orthod Dentofacial Orthop. 1996;110:466-468.
4. Nakamura S, Miyajima K, Nagahara K, Yokoi Y. Correction of single-tooth crossbite. J Clin Orthod. 1995;29:257-262.
5. Lim KF. Correction of posterior single-tooth cross bite. J Clin Orthod. 1996;30:276.