

The autologous blood become gold standard procedure in pterygium surgery: An observational study

Talluri Jeeva Ratnam^{1,*}, Vijetha P²

¹Assistant Professor, ²Associate Professor, ¹Dept. of Ophthalmology, ²Dept. of Physiology, ESIC Medical College, Sanathnagar, Hyderabad, Mallareddy Co-Ed Medical College, Suraram, Medchal, Secunderabad, Hyderabad, India

***Corresponding Author:**

Email: drjeevatalluri@gmail.com

Abstract

Introduction: Degenerative pterygium causes visual impairment due to astigmatism and blockade of visual axis. As pterygium cannot be treated medically, surgical excision of pterygium is the only way. Simple excision can be done but it is associated highest recurrence rate. Hence the standard method of preventing the recurrence after pterygium excision is Limbal conjunctival Auto Graft (LCAG). Adherence of the Auto graft to the excisional site is done by overlaying the auto graft upon the sclera either with sutures or glue routinely. However to address suture and fibrin related complications the concept of Autologous Blood came up. The current study taken up to find out whether autologous blood has become standard technique in treatment of degenerative pterygium.

Aim: To assess the efficacy of Autologous blood in the adherence of the LCAG.

Purpose: To know whether leaving the Autologous blood on the scleral bed can be made as a standard procedure in Pterygium surgery.

Materials and Methods: 30 patients with the degenerative pterygium grown beyond the limbus were taken for the study. Patients with bleeding disorders, recurrent pterygium, ocular surface disorders, minimal pterygia and pregnancy were excluded. Pterygium was excised leaving the patient's own blood on the excised area with minimal cautery and LCAG is placed on the bare sclera, and then pad bandage applied. Post operatively eyes were examined whether LCAG is well adhered or not. All the patients were followed for minimum of 6 weeks.

Results: All eyes (100%) showed excellent adherence throughout the post operative period. None of the eyes lost the graft.

Conclusion: The autologous blood excellent replacement for sutures and donor fibrin. Autologous blood is simple adjuvant of choice and has become gold standard in Pterygium surgery.

Keywords: Autologous blood, Adherence, Fibrin, Graft, Pterygium.

Introduction

Fibro vascular proliferation and elastotic degeneration of the subconjunctival tissue is defined as pterygium. Pterygium is caused by varied etiology, among them the most acceptable cause is UV-B exposure under the sun.¹ There are certain countries which are exposed more to UV-B exposure in the latitude 30⁰ north south of equator² Hong kong is situated at 20⁰ latitude north of equator, said to have higher rate of pterygium though it is not situated in 30⁰ north south of equator.³ This sort of pterygium is known as degenerative or primary pterygium. Secondary or inflammatory pterygium is caused by trauma or secondary to inflammation.

Pterygium causes visual impairment by changing the curvature of the cornea which results in astigmatism. Early degenerative pterygium can also cause the blurring of vision due to astigmatism. Primary or degenerative pterygium is graded into grade 0 to 4. Grade 0 indicates stage of pinguecula. Grade 1 is early pterygium which did not cross the limbus. Grade 2 is pterygium that is on the limbus. Grade 3 is pterygium which crossed limbus and grown on cornea and not upto papillary area. Grade 4 is pterygium which is crossing the pupil area. Patients will experience foreign body sensation, dryness and head ache. Dryness is due to tear film instability. Head ache is caused by the

uncorrected astigmatism which was induced by the pterygium. Chronic degenerative pterygium can cause visual axis blockade by passing the across the pupillary area of cornea. At this stage removal of pterygium will leave significant corneal opacity. This opacity causes permanent visual impairment. In rare cases pterygium can cause conjunctival carcinoma, sarcoma, conjunctival cyst and myxoma. Hence one must address the pterygium in a simple but standard way.

Mainstay of treatment of pterygium is surgical approach. There are several surgical approaches and adjuvant usage in treating pterygium. Simple excision with bare sclera technique has 24-89% of recurrences.⁴ Natural barrier in preventing the conjunctiva growing on to the cornea is limbus stem cell epithelium.⁵ This raised the concept of replacing limbal stem cell epithelium after the pterygium excision and many studies have proven this,⁶⁻⁹ however limbal conjunctival autograft also has recurrence rate from 1.9% to 4%^{10,11} to adhere the conjunctival autograft on to the sclera by sutures and fibrin glue. Fibrin glue has potential danger of spreading parvovirus B-19 infection and prion infection¹²⁻¹⁴ recurrence rate for pterygium excision along with limbal conjunctival autograft with suture technique is high (12%). Also it takes longer time to heal and there is granuloma formation. Suture related giant papillary conjunctivitis and post op discomfort are

the other complications with suture technique¹⁵⁻¹⁷ fibrin based adhesives have biological and biodegradable properties and can be used with amniotic membrane or limbal conjunctival autograft and causes less inflammation. Hence it stands superior to that of suture technique¹⁸ fibrin glue used in other procedures to close the pterygium such as strabismus surgery, glaucoma surgery and vitreoretinal surgery.¹⁹⁻²¹

In order to prevent suture related complications and fibrin glue related complications the present study is taken up by utilizing patients own blood at the recipient scleral bed as the autologous blood is safe. The autograft using the normal physiological blood clot of patients own blood acts as bioadhesive is as equally effective as with commercial fibrin glue adhesive.^{22, 23}

Clotting final pathway²³

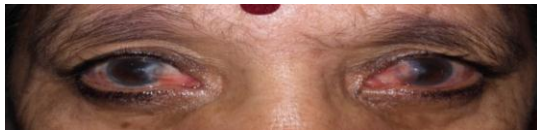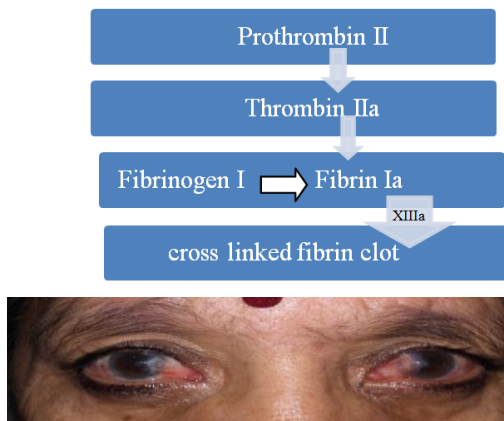


Fig. 1: Advanced bilateral degenerative pterygium

Materials and Methods

The present observational study was conducted from May to November 2015 at Narayana medical college, Nellore who were admitted with Primary or degenerative pterygium that did not have previous pterygium excision or trauma. All the patients were taken written consent prior to the surgery. This study had got the ethical committee clearance.

All patients were examined for visual acuity, intraocular pressure, anterior segment examination by slit lamp bio microscope and dilated fundus examination with +90 D lens. Our exclusion criteria were recurrent pterygium, ocular surface infection, pregnancy and minimal pterygia (stage 0) and bleeding disorders.

Peribulbar anaesthesia is given to achieve akinesia and precise excision of pterygium, graft and replacement of graft on recipient bed. Pterygium cap is demarcated with crescent blade and cap was pulled out along with the head with colibri forceps. Plane is maintained throughout the dissection 4-6mm away from the limbus. Minimal bipolar cautery is applied to the

bleeding points as the bare sclera. Care is taken not to damage the medial rectus. Limbal conjunctival graft is harvested from superior bulbar conjunctiva exceeding 1mm onto the limbus. Then graft is placed on the bare sclera slightly larger than the recipient bed. Graft is kept for 30 seconds and irrigation was not allowed in this period. However corneal drying was prevented by wetting the cornea with normal saline drop by drop. Neosporine eye ointment was placed onto the graft and inner canthus. Subconjunctival dexamethasone and gentamicin was given at inferior bulbar conjunctiva. Eye is closed and pad and bandage applied.

After 24 hours pad and bandage was carefully opened and looked for subconjunctival haemorrhage, graft displacement, graft edema and graft loss.

Results

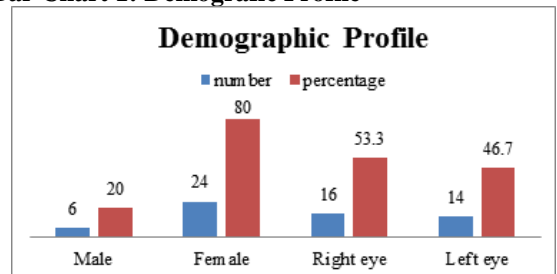
Total 30 patients were recruited for the study. There were 24 female and 6 male patients (80% and 20% respectively). Mean age group was in Male was 47years and female was 48.5 years

Demographic profile is given in the Table.1 and the same is depicted in the bar chart.

Table1: Demographic profile

Category	Number	Percentage (%)
Male	6	20
Female	24	80
Right eye	16	53.3
Left eye	14	46.7

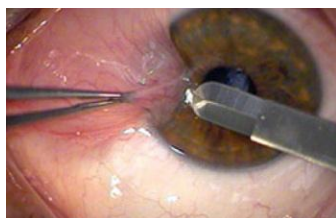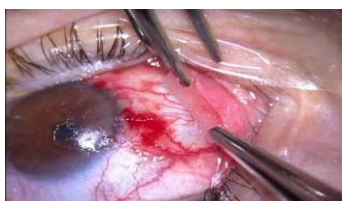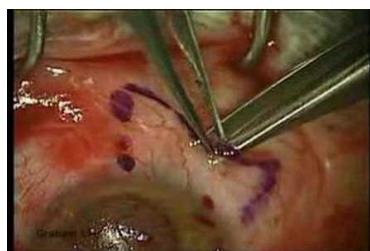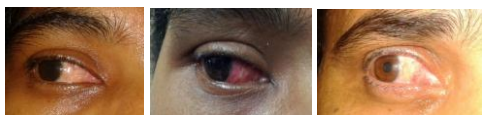
Bar Chart 1: Demographic Profile



All the patients were seen at 1st Post operative day (POD), 1week POD, & 6week POD. There was 100% follow up present. Since our aim was strictly confined to observation of the limbal conjunctival autograft adherence to the scleral bed without fibrin glue and sutures, we did not study the recurrence rate. The post operative complications are given in the table2. None of the patents had loss of graft (100%) noted till the end of 6 weeks.

Table 2: Post-operative complications

Complication	1 st POD	POD 1week	POD 6weeks
Edema of graft	All patients(30)	3 % (30%)	nil
Graft displacement	Slight (1mm) displacement in 2 Patients (6.7%)	Covered by conjunctival growth	nil
Inadequate graft size	2mm less in size (3.3%) in 1 patient	Covered by conjunctival growth	nil
Sub-conjunctival hemorrhage (SCH)*	3 patients (10%)	SCH reduced in size	Total absorption of hemorrhage
Corneal ED on excised area	All patients	Defect is healed	No stain positive area
Conjunctival granuloma	nil	nil	nil
Loss of graft	Nil	nil	nil

**Fig. 2: Pterygium Excision****Fig. 3: Post excisional sclera bed****Fig. 4: Procuring Autograft****Fig. 5:**

Discussion

Time tested and gold standard method for the treatment till today is Pterygium excision and conjunctival autograft transplantation.²⁴ Changes in the methods of adherence are the 'advancement' occurred in past few years. Graft adherence was the initial method and was associated with suture irritation and visualization. To avoid suture related complication

fibrin glue was used and has given better surgical outcome than graft adhered with sutures.^{25, 26} However fibrin glue has the danger of transmission of parvo virus 19, Prion and HPV B12 infections.¹³ In order to address this fibrin glue related complications, autologous blood is used in two different studies.^{22, 23} Abraham Kurian et al found similar results. The autologous fibrin was used from the patient's blood and done in tertiary care hospital and is expensive. We did our study to know effectiveness of autologous blood in pasting the graft on the scleral bed leaving the patient's blood on the sclera bed in camp patients who are socio economically poor. This technique is rapid, inexpensive and simple. Hence was made as standard surgery for pterygium in our camp patients and non patients also. Owing to its simplicity of the procedure our trainee surgeons also found ease. This method can be done on massive load of patients who come under national programme for prevention of blindness program. Our results shown at the end of 6weeks, there was no graft loss in all the patients (0%) comparable to Abraham Kurian et al in which 3 eyes had graft loss out of 100 eyes (3.1%) in their study. The limitation of the current study is whether this procedure is also suitable to the patients with recurrent pterygium.

Conclusion

The autologous blood is compatible bio-adherent and is the excellent replacement for sutures and donor fibrin. It is cost effective, quick and easy technique. Autologous blood is definitely the adjuvant of choice and has become gold standard in pterygium surgery.

References

1. Moran DJ, Hallows FC. Pterygium and uv radiation: A positive correlation. *Br J ophthalmol* 1984 ; 68:343-6.
2. Cameron M E, Springfield I L, Charles C Thomas 1965. Pterygium throughout the world.
3. Karukonda S R, Thompson H W, Beuramen R W et al. Cell cycle kinetics in pterygium at 3 latitudes *Br J ophthalmol* 1995;79:313 -17.
4. Jeros P A, DeLuise V P. Pinguecula and pterygium. *Surv ophthalmol* 1988; 33:41-9.

5. Tseng S C. concept and application of limbal stem cells. *Eye* 1989;3:141-57.
6. Muthlu F M, Sobaci G, Tatar T et al. A comparative study of recurrent pterygium surgery. limbal conjunctival autograft transplantaion vs mitomycin C with conjunctival flap. *Ophthalmology* 1999;106:817-21.
7. A I Fayed M F. Limbal vs conjunctival autograft transplantation for advanced and recurrent pterygium. *Ophthalmology* 2002;109:1752-5.
8. Gris O, Guell J L, Del Campo Z. Limbal conjunctival autograft transplantation for the treatment of recurrent pterygium. *Ophthalmology* 2000;107:270-3.
9. Rao S K, Lakha T, Mukesh B N et al. Conjunctival limbal autograft for primary recurrent pterygia: Technique and results. *Indian J ophthalmol* 1998;46:203-9.
10. A Karalezli, C Kucukurdonmez, Y A Akova et al. Fibrin glue vs conjunctival autograft in pterygium surgery : A prospective comparative study. *Br J Ophthalmol* 2008;92:1206-10.
11. A L Young, GYS Leung, AKK Wong et al. A randomized trial comparing 0.02% mitomycin C and limbal conjunctival autograft after excision of primary pterygium. *Br J Ophthalmol* 2004;88:995-7.
12. Korangi G, Seregard S. A no suture small incision approach to pterygium surgery. *Br J Ophthalmol* 2005;89:911-14.
13. L S Alvaranga. Comments on using fibrin glue in pterygium surgery. *Br J ophrthalmol* 2005;89:392.
14. Hino M, Ishiko O, Honda K et al. Transmission of symptoms of parvovirus B -19 infection by fibrin sealant used during surgery. *Br J Haemato* 2000;108:194-5.
15. Hirst L W. The treatment of pterygium. *Surv ophthalmol* 2003;48:145-80.
16. Ang L P, Chua J L, Tan D T. Current concepts and techniques in pterygium treatment. *curr opinion ophthalmol* 2007;18:308-13.
17. Starck T, Kenyon K R, Serrano F. Conjunctival autograft for primary and recurrent pterygia: surgical technique and problem management. *Cornea* 1991;10:196-202.
18. Chan S M, Boisjoly H. Advances in the use of adhesives in ophthalmology. *Curr opin ophthalmol* 2004;15:305-10.
19. Biendner B, Rosenthal G. Conjunctival closure in strabismus surgery: vicryl vs fibrin glue. *Ophthalmic surg lasers* 1996;27:967.
20. Kajirawa K. Repair of a leaking bleb with fibrin glue. *Am J ophthalmol* 1990;109:599-601.
21. Menteus R, Stalmaus P. Comparison of fibrin glue and sutures for conjunctival closure in pars plana vitrectomy. *Am J Ophthalmol* 2007;144:128-31.
22. Malik KP, Goel R, Gupta A, et al. Efficacy of sutureless and glue free limbal conjunctival autograft for primary pterygium surgery. *Nepalese J Ophthamol* 2012 July-Dec, Vol 4(20), PP: 230-5.
23. Abraham Kurian, Iodine Reghunandan, KGR Nair. Autologous blood Vs fibrin glue for conjunctival autograft adherence in sutureless pterygium surgery: A randomized control trial. *Br J Ophthalmol* 2015; 99:4464-470.
24. Kenyon KR, Wagoner MD, Hettiger ME. Conunctival autograft tansplantation for advanced and recurren perygium. *Ophthalmology* 1985; 92:1461-70.
25. Koranyi G, Seregard S, Kopp ED. The cut and paste method for primary pterygium surgery: Long term follow up. *Acta Ohthalmol Scand* 2005;83:298-301.
26. Ashok S, Hans R, Aditi G et al. Sutureless and Glue free verses sutures for Limbal conjunctival autografting in Primary pterygium surgery: A prospective comparative study. *Journal of Clinical and Diagnostic Research*. 2015 Nov, Vol-9(11):NC06-NC09.