

Oral propranolol in the treatment of infantile eyelid haemangioma

Riffat Rashid^{1*}, Nazmul Haque Robi², Sadia Sultana³, Syeed Mehbub Ul Kadir⁴

^{1,3,4}Consultant, ²Senior Consultant, Dept. of Oculoplasty, ¹⁻³Ispahani Islamia Eye Institute and Hospital (IEI&H), Dhaka, Bangladesh, ⁴Sheikh Fazilatunnesa Mujib Eye Hospital & Training Institute, Dhaka, Bangladesh

***Corresponding Author:**

Email: drriffatrashid@gmail.com

Abstract

Introduction: Capillary haemangiomas or infantile haemangioma of the eyelid are the most common tumors of infancy. Infantile haemangioma appears soon after birth. Tumors that involving the periorbital area require treatment.

Objectives: To evaluate the rate of regression by size and to evaluate color change of infantile eyelid haemangioma treated with oral propranolol.

Methods: The prospective study was carried out in the department of Oculoplasty, Ispahani Islamia Eye Institute and hospital during the period of January 01, 2013 to September 30, 2017. We included all patients of 1 months to 60 months, clinically diagnosed infantile eyelid haemangioma of either sex attended in the out-patient department during the study period with relative indication for treatment. The exclusion criteria were: haemangioma with presenting life-threatening condition, cardiovascular disorders contraindicating propranolol use, family history of bronchial asthma, or recent/repeated outbreak of wheezing, low birth weight newborns and previously treated with intralesional Triamcinolone. Patients were treated by oral Propranolol: 2 mg/ kg /day. Follow-up visits were initially scheduled after 2 and 4 weeks of therapy and then monthly for six months.

Results: This study included a total of 93 patients with infantile eyelid haemangioma. The age of the patients in the study group ranged from 1 months to 42 months. Male 36 and female 57. Right eye involved in 40 patients and left eye 53. After 6 months of treatment, overall color clearance was seen in all patients, 70(75%) had an excellent response. After 6 months of treatment, overall regression of size was seen in all patients. In 75(80%) patient had an excellent response.

Conclusion: Propranolol has been found clinically effective and also cost-effective in the treatment of infantile eyelid haemangioma. It also demonstrated better tolerance with minimal adverse effects.

Keywords: Capillary haemangioma, Intralesional triamcinolone, Propranolol, Periorbital.

Introduction

Infantile capillary haemangioma is considered a hamartoma and represents one of the most common benign vascular tumour in children.^{3,8,10,11} This lesion may noticed at birth as a reddish spot (30-35%) or develops a few weeks after birth⁵ that enlarges during first months of life, and then maintains its size or involutes (50%) at fifth year of age.¹⁰ The female to male ratio is 3:1.⁷ Eyelid haemangiomas have a predilection for the upper lid⁶ and may extends to orbit.^{4,7} Sometimes eyelid haemangiomas are associated with haemangiomas on other parts of the body⁶ which may cause significant functional and cosmetic deformity.³ The lesion typically involute before the end of the first decade, so treatment is usually not required.^{2,8} Treatment is indicated when obstruction of visual axis or astigmatism causing amblyopia, exposure keratitis secondary to proptosis, optic nerve compression, ulceration, bleeding and facial disfigurement present.^{1,3,9} Most common treatment options are intralesional or systemic steroids, interferon alpha, vincristine, laser therapy or surgical excision.^{1,5,9,15} Oral propranolol, a non-selective β -blocker is now considered as highly promising agent for the treatment of capillary haemangioma which inhibit vascular proliferation.^{3,5,8} The aim of this study is to assess the use of oral propranolol in the treatment of Infantile hemangioma, quantifying its effectiveness and safety under continuous monitoring.

Methods

The prospective study was carried out in the department of Oculoplasty, Ispahani Islamia Eye Institute and hospital during the period of January 01, 2013 to September 30, 2017. Prior to commencement of this, it was approved by the ethical review committee of institute and the objectives of the study, the nature of the disease, the investigations, treatment modalities and potential complications regarding propranolol were explained to the patients' parents. An informed written consent was also taken. We included all patients of 1 months to 60 months, clinically diagnosed infantile eyelid haemangioma of either sex attended in the out-patient department during the study period with relative indication for treatment. The exclusion criteria were: haemangioma with presenting life-threatening condition, cardiovascular disorders contraindicating propranolol use, family history of bronchial asthma, or recent/repeated outbreak of wheezing, low birth weight newborns and previously treated with intralesional Triamcinolone.

Demographic and clinical data include age, sex, location and size of the lesions. All the children underwent a complete ophthalmic examination before treatment started. Random blood sugar, measurement of blood pressure and Echocardiogram were done in every patient before starting the treatment. Body weight was measured in every patient to adjust the dose of

propranolol. Photograph was taken periodically to assess the change of size and colour of the lesion.

Patients were treated by oral Propranolol: 2 mg/ kg /day, in two divided doses and continued for six months, if there were no adverse effects. Follow-up visits were initially scheduled after 2 and 4 weeks of therapy and then monthly for six months. The dosage of propranolol was adjusted to the weight of the patient. In each follow up pulse, blood pressure, percentage of regression (of size), color change was recorded.

Results

This study initially included a total of 97 patients with infantile hemangioma in eyelids, face and orbit. 4 patients were excluded due to congenital heart defect. So, finally 93 patients were included. This study included a total of 93 patients with infantile eyelid haemangioma. The age of the patients in the study group ranged from 1 months to 42 months with mean age 5.8 months. Male 36(39%) and female 57(61%). Right eyes were involved in 40(43%) patients and left eyes 53(57%). Among them 5(5%) patients had associated orbital lesion and 6(6%) patients had

associated facial lesion. After 6 months of treatment, overall color clearance was seen in all patients, 70(75%) had an excellent response. After 6 months of treatment, overall regression of size of the tumour was seen in all patients. In 75(80%) patient had an excellent response. 8(9%) patients showed slow response after 6 months of propranolol therapy. Later they need additional intralesional Triamcinolone injection. None of our patients showed any sign of recurrence.

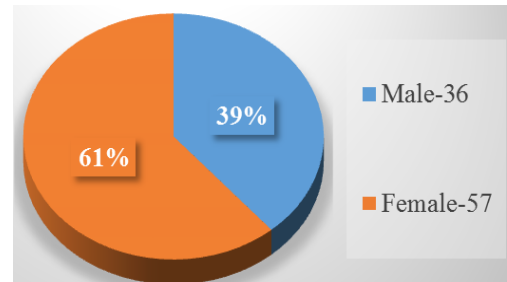


Fig. 1: Gender distribution

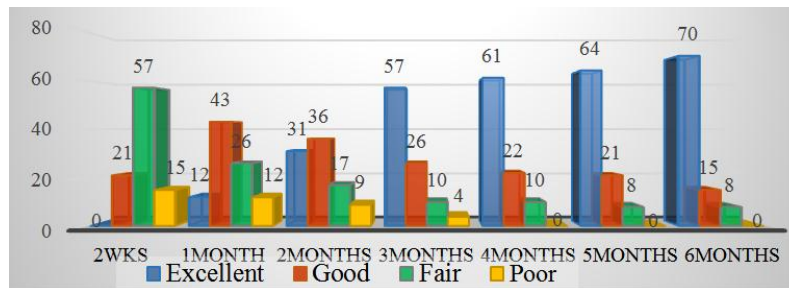


Fig. 2: Results of colour change according to the follow up time

Table 1: Percentage of Regression of Size according to the follow up time

Result	Excellent	Good	Fair	Poor
Follow up Time	N (%)	N (%)	N (%)	N (%)
14days	-	67(72%)	18(19%)	8(9%)
1 month	25(27%)	48(52%)	15(16%)	5(5%)
2 months	55(59%)	25(27%)	10(11%)	3(3%)
3 months	66(71%)	19(20%)	8(9%)	-
4 months	66(71%)	19(20%)	8(9%)	-
5 months	70(75%)	15(16%)	8(9%)	-
6 months	75(80%)	10(11%)	8(9%)	-

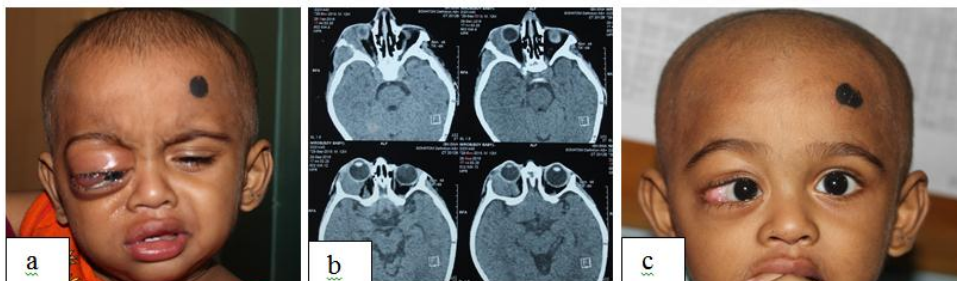


Fig. 3: a) Periocular and orbital infantile haemangioma, Fig. 3: b) CT scan shows retro and lateral orbital lesion, Fig. 3: c) Regression of the lesion after 3 months of treatment

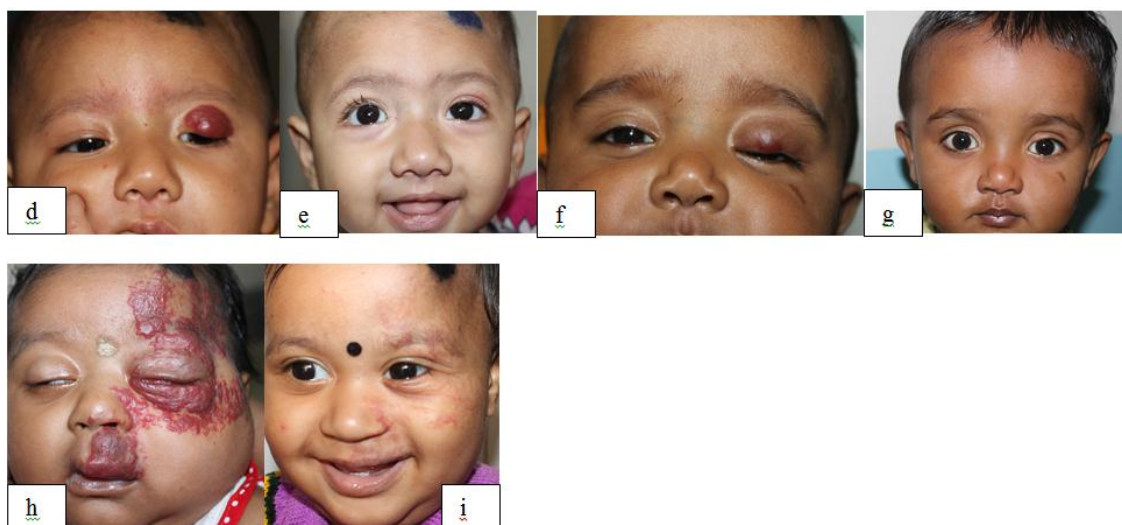

Fig. 4 d-i: Before and after 6 months of treatment

Discussion

Capillary haemangioma develops soon after birth but undergo rapid and intermittent growth throughout the first year of life. Tumour involving periorbital area and face require treatment.¹² Leaute-Labreze in 2008, incidentally found that oral propranolol has an excellent role in treatment of infantile haemangioma, while they were treating pediatric cardiac patients.^{5,8,14} Since then Systemic propranolol is a new treatment modality for infantile haemangioma. In our study, age of the patient ranged from 1-42 months (mean 5.8 months). Vassallo P et al (2012) in their study, showed age ranged from 1-72 months, mean 20.85 months. In another study, the median age was 4 months.⁸ Hernandez JA et al, showed mean age of 9 months.¹⁶ As capillary haemangioma appears soon after birth, most of the patient present early. Out of 93 patients, 36(39%) were male and 57(61%) were female, in this study. Koka K et al, showed out of 21 patients, 18(85%) were female. Aletaha M et al (2012), in their study reported 3 cases of female of eyelid capillary haemangioma. Hernandez JA et al, showed 75% female and 25% male. Capillary haemangioma is more common in female. In this study, right eye was involved in 40 patients, and left eye 53. Among them orbital lesion was present in 5(5%) patients and facial in 6(6%). Koka K et al, also found proptosis due to orbital mass in 7 (33%), and facial lesion in 2 (1%) patients, out of 21. Among 3 patients, 1 had massive lesion over eye, face and ear in another study.¹ Spiteri Cornish K et al (2011), showed 11 cases out of 100 had an orbital extension. Computerized tomography was performed in selected cases.³ Orbital and facial involvement is common in all the study. Regression started with colour change from intense red to lighter purple-blue, with softening of the lesion.⁵ After 6 months of treatment, colour change of the lesion was seen in all patients, 70(75%) had an excellent response, in this study. It was observed after 2 weeks of

starting of propranolol. Koka K et al, showed one third of their patients had improvement within a week. The first visible and measureable response to treatment was observed within 48 hours of initiating treatment in superficial cases. Lesion size decreased to half of its original size after 2 months.¹ Onset of clinical response varies in different study, may be depending upon the size of the capillary haemangioma. Spiteri Cornish K et al (2011), in a review study on oral propranolol treatment of periocular infantile haemangioma discussed that, complete resolution occurred in 96% of cases. Which is 80% in our study and others were slow in regression. Awadein A et al (2011), showed 42% of patients had excellent response. Literatures showed, recurrence of 15% of cases in one study,³ but there was no recurrence in other study like ours.^{1,8} Some minor adverse effects of propranolol were documented like bradycardia, hypotension, hypoglycemia and bronchospasm in 26 patients, out of 100 in a study.³ As we included selective cases, we had not found those.

Conclusion

Propranolol has been found clinically effective, safe and also cost-effective in the treatment of infantile eyelid haemangioma. It also demonstrated well tolerance with minimal adverse effects.

Large multicenter and long term study may confirm these results.

Conflict of Interest: The authors declare no conflict of interest in this article.

References

1. Aletaha M, Salour H, Begheri A, Raffati N, Amouhashemi N. Oral Propranolol for treatment of Pediatric Capillary Hemangioma. *J Ophthalmic Vis Res* 2012;7(2):130-3.
2. Albert DM, Miller JW (eds.) 2008, 'Pathology of the lids' in *Principles and Practice of Ophthalmology*, 3rd edn.

- Elsevier, Canada, pp. 3737-51.
3. Spiteri Cornish K, Reddy AR. The use of propranolol in the management of periocular capillary hemangioma-a systematic review. *Eye* 2011;25:1277-83.
 4. Garg A, Alio JL. (eds.) 2010, 'Orbital Disorders: Vascular Abnormalities' in *Surgical Techniques in Ophthalmology Oculoplasty and Reconstructive Surgery*, 1st edn. Jaypee, New Delhi, India, pp 164-67.
 5. Awadein A, Fakhry MA. Evaluation of intralesional propranolol for periocular capillary hemangioma. *Clinical Ophthalmology* 2011;5:1135-40.
 6. Foster JA, Carter KD, Durairaj VD et al. (eds.) 2016, 'Orbital Neoplasms and Malformations' in *Orbit, Eyelid, and Lacrimal System*, American Academy of ophthalmology, United States of America, pp 67-101.
 7. Kanski JJ. (eds.) 2007, 'Eyelids' in *Clinical Ophthalmology*, 6th edn. Elsevier, China, pp 93-149.
 8. Koka K, Mukherjee B, Agarkar S. Effect of oral propranolol on periocular Capillary Hemangiomas of infancy. *Pediatrics and Neonatology* (2017), <https://doi.org/10.1016/j.pedneo.2017.11.021>.
 9. Drolet BA, Frommelt PC, Chamlin SL et al. Initiation and Use of Propranolol for Infantile Hemangioma: Report of a Consensus Conference. *Pediatrics* 2013;131:128-40.
 10. Moreiras JVP, Prada MC. (eds.) 2004, 'Infantile Capillary Hemangioma' in *Orbit*, vol 1 1st edn. Highlights of Ophthalmology, Panama, pp 223-242.
 11. Shields JA, Shields CL. (eds) 2008, 'Vascular Tumors of the Eyelids' in *Eyelid, Conjunctival, and Orbital Tumors*, 2nd edn. Lippincott Williams & Wilkins, Philadelphia, pp 131-157.
 12. Haque MM, Ferdous KMN, Saha BK, Paul SK, Islam MK. Oral Propranolol and Prednisolone in the Treatment of Infantile Haemangioma: A Comparative Study. *Chattagram Maa-O-Shishu Hospital Medical College Journal* 2014;13(1):26-31.
 13. Vassallo P, Forte R, Mezza AD, Magli A. Treatment of Infantile Capillary Hemangioma of the Eyelid with Systemic Propranolol. *American Journal of Ophthalmology* 2012. DOI: <https://doi.org/10.1016/j.ajo.2012.06.021>.
 14. Bang GM, Setabutr P. Periocular Capillary Hemangiomas: Indications and Options for treatment. *Middle East Afr J Ophthalmol* 2010;17(2):121-28.
 15. Guo S, Ni N. Topical Treatment for Capillary Hemangioma of the Eyelid Using β - Blocker Solution. *Arch Ophthalmol* 2010;128(2):255-6.
 16. Hernandez JA, Chia A, Seah LL. Periocular capillary hemangioma: management practices in recent years. *Clin Ophthalmol* 2013;7:1227-32.