

Bilateral ectropion in collodion baby - Three case reports

Ruma Das¹, Jayanta Kumar Das^{2,*}, Saurabh Deshmukh³, Richa Shrivastava⁴, Krati Gupta⁵

¹Professor and Head, ²Senior Consultant, ³Resident, ⁴Fellow, ⁵Resident, ^{1,3,5}Dept. of Ophthalmology, ^{2,4}Dept. of Ophthalmic Plastic and Reconstructive Surgery Services, ¹Tezpur Medical College, Assam, ²⁻⁵Sri Sankaradeva Nethralaya, Guwahati, Assam, India

***Corresponding Author:**

Email: jk2269929@yahoo.co.in

Abstract

The term 'Collodion baby' is used for the new-borns who are born in a parchment like membrane which is shiny, taut, waxy and appears like an extra layer of skin that has a collodion-like quality covering the whole body. It is not a specific diagnosis or disorder but rather a descriptive term. It is found in some forms of congenital ichthyosis. This membrane is shed around 2 weeks from birth. On shedding of membrane dry rough scaly skin like that of fish is visible. Other findings seen in our cases include ectropion and flattening of the nasal bridge. Neonates require careful monitoring and appropriate supportive treatment to decrease morbidity and mortality related to the disorder. We report here three rare cases of collodion baby with congenital ectropion.

Keywords: Collodion baby, Lamellar ichthyosis, Ectropion.

Introduction

The term 'Collodion baby' is used for the new-borns who are born in a parchment like membrane which is shiny, taut, waxy and appears like an extra layer of skin that has a collodion-like quality covering the whole body. Collodion baby is rather a phenotype than a disease entity. This term was introduced in 1892.¹ These newborns have diffuse epidermal hyperkeratinization, skin erythema, loss of hair, deep cutaneous fissures, and eclabium.² They are particularly prone to exposure keratopathy as a sequela to severe congenital ectropion which may further progress to vision threatening infectious keratitis. We report here three collodion babies who presented with severe ectropion that resolved with timely conservative management with local ocular treatment.

Case 1

A one-day-old neonate, informant being the mother presented with chief complaints of inability to close eyes due to eversion of both upper and lower lids since birth (Fig. 1). Neonate was born to a 26-year-old primigravida from a non-consanguineous marriage, at full term. Antenatal and intrapartum period was uneventful. There was no history of birth trauma, exposure to radiation and any significant drug intake by mother during the period of gestation. On examination, baby was covered by a shiny taut membrane all over the body. There was ectropion of both upper and lower eyelids with conjunctival congestion. There was also flattening of nasal bridge. Corneal was clear and pupil reacting to light.

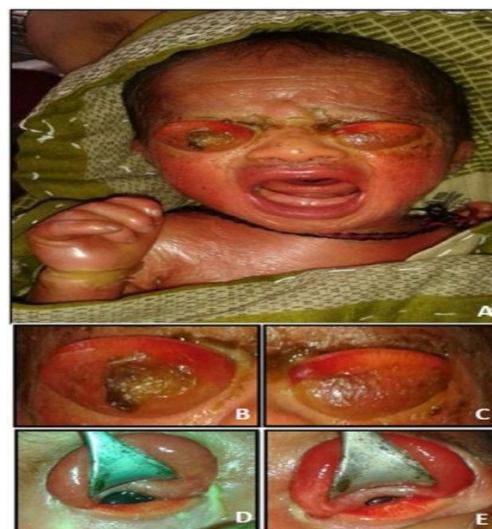

Fig. 1: (A, B, C) Clinical photograph showing severe ectropion with organized scab over tarsal conjunctiva of both upper eyelids with madarosis and eclabium. There is also presence of periorcular scabs with cutaneous hyperemia with scab over the right wrist area. (D, E) retraction of the lids showing clear cornea

Case 2

A one-day-old neonate, informant being the parents presented with chief complaints of swelling of both eyes and eversion of both upper lids with crusting and dryness over everted lids (Fig. 2). The baby was born of a non-consanguineous marriage. There was no history of birth trauma, exposure to radiation and any significant drug intake by mother during the period of gestation. On examination baby was found to be covered in collodion membrane, ectropion of both upper lids with gross lid edema. Conjunctival chemosis, keratinisation of the upper palpebral conjunctiva and secondary infection was present. Cornea was clear.

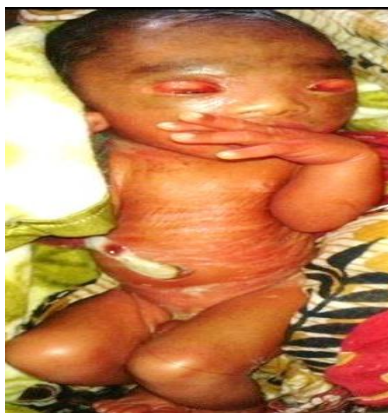

Fig. 2: Clinical photograph showing severe bilateral ectropion with loss of eyelashes and diffuse hyperemia. The skin appears shiny with a membrane like covering over it

Case 3

A four-day-old neonate, informant being the mother presented with chief complaint of redness and inability to close the eyes completely since birth (Fig. 3). The child was born at term by normal vaginal delivery. There was no history of consanguinity or similar illness in the siblings. Ocular examination revealed loss of eyelashes with a crusted membrane over the palpebral conjunctiva and periocular skin. There was also conjunctival chemosis.

All three neonates were examined after instillation of 0.5% proparacaine anaesthesia, showing normal cornea, reacting pupil with normal posterior segment. The scabs over the conjunctiva were gently removed under topical anaesthesia and the treatment started in the form of hourly instillation of 0.5% carboxymethyl cellulose eye drop in both the eyes to keep the cornea and the conjunctiva hydrated along with instillation of tobramycin 0.3% eye ointment in both eyes and massage over the eyelids with the ointment 3 times a day. Wet saline gauze was used to cover the eyes. Frequent follow ups were done. After 1 month, condition improved and ectropion resolved by itself (Fig. 4).

Skin biopsy in both cases confirmed the diagnosis of lamellar ichthyosis. (Fig. 5).

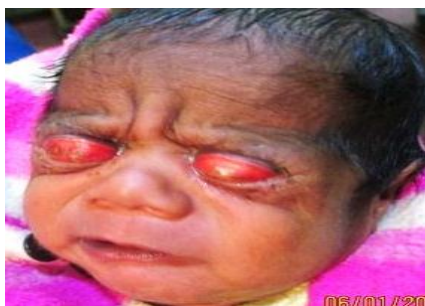

Fig. 3: Clinical photograph showing severe eversion of both upper eyelids with loss of eyelashes and formation of scab over it

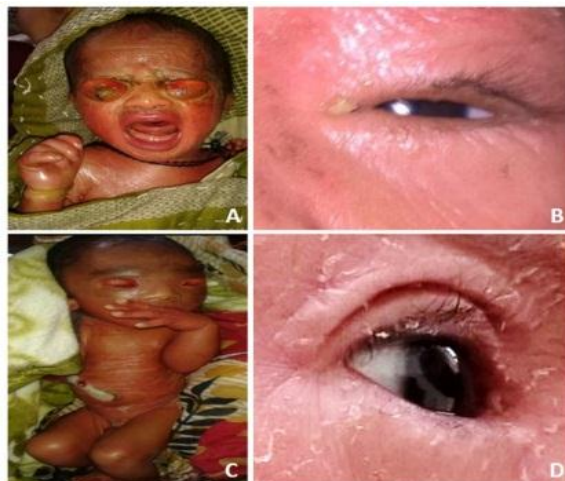

Fig. 4: (A, B) Pre and post treatment photographs of first case at 1 month showing significant correction of ectropion with regrowth of the eyelashes. (C, D) Pre and post treatment photographs of second case at 1 month showing significant improvement in ectropion with reappearance of the eyelashes

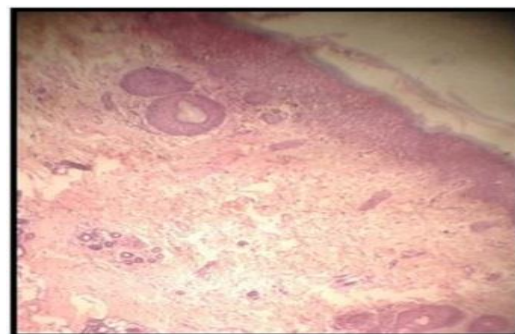


Fig. 5: Hematoxylin and eosin stain section of the skin showing a thickened layer of compact orthohyperkeratosis overlying a diminished granular layer, focal parakeratosis with blunting of the rete ridges. Minimal changes in the dermis noted

Financial Support: None

Conflicting Interests: None

Discussion

Collodion baby is a term given to a neonate born covered in a shiny taut membrane all over the body, which gradually sheds off and mostly develops into lamellar ichthyosis. Ichthyosis is a condition in which skin tends to dry excessively and there is increased formation of epidermal scales. There are four main types of ichthyosis, ichthyosis vulgaris, sex linked recessive, lamellar ichthyosis and epidermolytic hyperkeratosis. Lamellar ichthyosis is the rarest of them all with an incidence of less than 1 in 300000.³ It has autosomal recessive inheritance. There is a defect on chromosome 14q11 causing transglutaminase-1 (TG) defect.⁴ TG is necessary for the formation of cross links between the cells of stratum corneum of the skin.^{4,5}

Consanguinity is seen in about eight percent of these cases. Male to female ratio is 2:1. Of all the neonates affected twenty-five percent are the ones who are born premature and in fifty one percent the siblings are affected.⁶ Ocular manifestations include exposure keratitis developing secondary to cicatricial ectropion, blepharitis, absence of the Meibomian gland, trichiasis and absence of lacrimal puncta. Ectropion of both upper and lower lids have been documented.⁶

To prevent the dreaded complication of exposure keratopathy, surgical correction of congenital ectropion with skin grafting has been successfully performed.⁷ Other surgical procedures like with mucous membrane grafting for skin and eyelid-inverting sutures have also been described in literature.⁸ Oral acitretin has also been tried in the treatment with promising results.⁹ Prompt treatment with copious lubrication and massage can avert the need for the surgical intervention. This case series however emphasizes the importance of early diagnosis and prompt conservative treatment could give optimum results without the need for the surgical intervention. Parents, why biopsy.

References

1. Hallopeau H, Watelet R. Sur une forme atténuee de la maladie dite ichthyose foetale. *Ann Dermatol Syphiligr* 1884;3:149-152.
2. Prasad RS, Pejaver RK, Hassan A, al Dusari S, Wooldridge MA. Management and follow-up of harlequin siblings. *Br J Dermatol*. 1994;130:650-3.
3. Jvn-Mo Yong, Kwang-Sung AHN et al. Novel mutation of TGI gene in lamellar ichthyosis. *J Invest Dermatol* 2001;117:214.
4. Russal LJ, Digiovanna JJ et al. Mutations in the gene for TGI in autosomal recessive lamellar ichthyosis. *Nat Genet* 1995;9:279-83.
5. DiGiovanna JJ, Robinson-Boston L. Ichthyosis: etiology, diagnosis and management. *Am J Clin Dermatol* 2003;4:81-95.
6. Boparai MS, Dash RG, Sohi BK. Lamellar ichthyosis (collodion baby) with severe bilateral ectropion. *Indian J Ophthalmol* 1988;36:140-1.
7. Culican SM, Custer PL. Repair of cicatricial ectropion in an infant with harlequin ichthyosis using engineered human skin. *Am J Ophthalmol*. 2002;134:442-3.
8. Sigurdsson H, Baldursson BT. Inverting sutures with systemic retinoids and lubrication can correct ectropion in ichthyosis. *Ophthal Plast Reconstr Surg*. 2016;32:e112-e113.
9. Singh M, Severe ectropion in lamellar ichthyosis managed medically with oral acitretin.