

Hypohidrotic ectodermal dysplasia – A case report

Shaul Hameed^{1,*}, Laxmikanth Chatra², Prashanth Shenoy³

¹Lecturer, ²Senior Professor & HOD, ³Senior Professor, Dept. of Oral and Radiology, Yenepoya Dental College, Deralakatte, Mangalore, Karnataka, India

***Corresponding Author:**

Email: shahulomr@gmail.com

Abstract

Ectodermal dysplasia is a hereditary disorder characterized by developmental dystrophies involving the ectodermal derivatives characterized by triad of signs comprising sparse hair, missing or abnormal teeth and inability to sweat. Ectodermal dysplasia may be divided into the Hypohidrotic form (x-linked recessive) and the Hydrotic form (Autosomal inherited). Here we present a case of a 34 years male with Hypohidrotic ectodermal dysplasia with partial anodontia of maxillary arch and complete anodontia of mandibular arch.

Keyword: Hydrotic, Ectodermal Dysplasia, Hypohidrosis.

Introduction

Ectodermal dysplasia is the term used to describe a group of rare, inherited disorders involving the dysplasia of tissues of ectodermal origin—primarily the nail, teeth and skin, and occasionally the dysplasia of mesodermally derived tissues.¹ The condition is seen in approximately 1 of 100,000 live births.^{1,2} Ectodermal dysplasia classified into Hypohidrotic form (x-linked recessive) and Hydrotic form (Autosomal inherited). Hypohidrotic Ectodermal dysplasia also called as Christ-Siemens Touraine syndrome is the more common and is characterized by a triad of signs comprising sparse hair (hypotrichosis), missing or abnormal teeth (anodontia or hypodontia), and an inability to sweat due to lack of sweat glands (anhidrosis or hypohidrosis).^{3,4} Hypodontia, in turn, causes reduced alveolar bone growth and lack of development of the alveolar ridges which often appear clinically to be extremely narrow and concave lingually. Teeth, if present, are often conically shaped, may be malformed and widely spaced. Other symptoms seen are saddle nose, prominent lips, linear wrinkles and hyperpigmentation around the eyes and also atopy, mild facial dysmorphic features and increased susceptibility to respiratory infections, this phenotype is seen in its full form only in affected males.^{5,6} Here we report a case with a typical clinical presentation of Hypohidrotic ectodermal dysplasia of a 34 year old Indian man.

Case Report

A 34 year old male patient reported to the dental clinics with a complaint of missing many teeth in the upper arch and missing all the teeth in the lower arch since childhood. On detailed history he reported that presence of 3 teeth in the deciduous dentition in the upper front teeth region which got exfoliated at the age of 8 years, the permanent teeth erupted at the age of 10 years which were conical shaped and he visited a dentist for the same and root canal treatment and full

crown restoration of all the teeth were carried out, he also reported decreased sweating, heat intolerance, decreased salivation, decreased lacrimal gland secretion, His parents were Non consanguineous marriage and No history of similar problem in the siblings were reported.

On general physical examination we noticed short stature, sparse body hairs, hypotrichosis, hypohidrosis. On extra oral examination revealed prominent forehead, saddle nose, reduced lower facial height, few scalp hair, missing eyelashes and eyebrows and protuberant lips were noted. (Fig. 1)

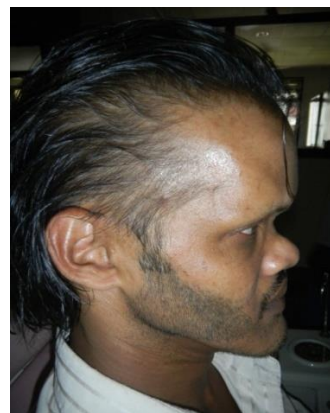


Fig. 1: Patient face showing prominent forehead, saddle nose, reduced lower facial height, few scalp hair, missing eyelashes and eyebrows and protuberant lips

The intra-oral examination revealed missing many teeth in the maxillary arch with a shallow palate and absence of all the mandibular teeth and the edentulous alveolar ridges were reduced in height and width. The mandibular ridge were knife edged and oral mucosa had a dry appearance and enlarged tongue were noted. (Fig. 2)

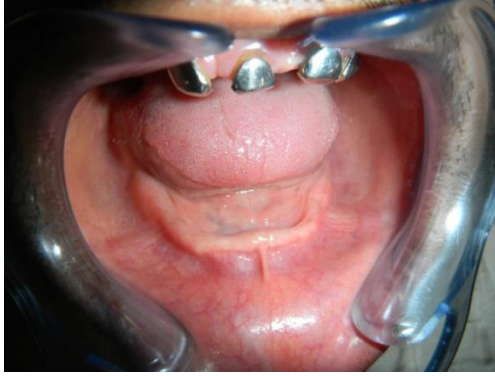

Fig. 2: Partial anodontia of maxillary teeth and complete anodontia of mandibular teeth

Radiographic examination revealed presence of maxillary canines, central incisors and maxillary left first molar, absence of rest of the teeth in the maxillary arch and absence of all the teeth in the mandibular arch, and decreased alveolar ridge height in the edentulous areas. (Fig. 3)

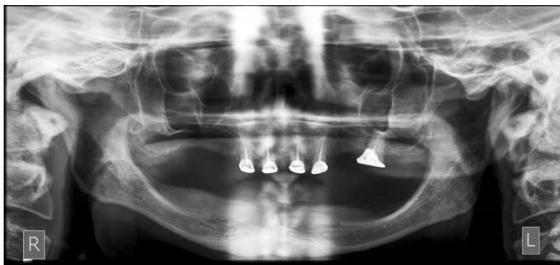


Fig. 3: Panoramic radiograph showing missing many teeth in the maxillary arch complete absence of teeth in mandibular arch

Based on the above history, clinical examination and radiographic interpretation we diagnosed it as Hypohidrotic ectodermal dysplasia with partial anodontia of maxillary arch and complete anodontia of mandibular arch. The patient was referred for prosthodontics for the need full.

Discussion

Ectodermal dysplasia is a very rare condition occurring in an estimated one per 100 000 live births.^{1,2} It can be associated with early morbidity and mortality.⁷ The disease was first described by Thurnman in 1843.⁸ It embraces a long series of abnormalities whose common denominator is a morphological alteration of ectoderm derived organs and tissues.⁹ Structures most commonly involved are the eccrine glands resulting in hypohidrosis or anhidrosis, the wispy hair, the teeth which are fewer in number and conical in shape and the nails.¹⁰ The most characteristic findings in man are the reduced number and abnormal shape of teeth, delay in eruption of teeth is often the first step in the diagnosis, our case also exhibited the same reduced number of

teeth, conical shaped teeth and delayed eruption of permanent teeth at the age.

The men have an easily recognizable faces, also referred to as an 'old man' faces. Our case also had a similar faces with prominent forehead. The reduced number of sweat glands and scalp and body hair are sparse, with lack of eyebrows and eye lashes. Our case exhibited all the above features.

Conclusion

The most frequent prosthetic treatment for the dental management of ectodermal dysplasia is removable prosthesis. Since alveolar bone development is dependent on the presence of teeth in the the jaw, the patient with ectodermal dysplasia have little or no bone ridge upon which to construt dentures; therefore, restoring the function and appearance is more challenging. In our case he underwent root canal treatment of his upper teeth to conserve the teeth present for the the further fixed partial denture may be Follow-up by a multidisciplinary team involving pedodontist, orthodontists, prosthodontists and oral-maxillofacial surgery specialists is advocated to be the most appropriate approach in such cases to plan for the future treatment.

References

1. Dhanrajani PJ, Jiffy AO. Management of Ectodermal Dysplasia. A Literature Review. *Dental Update* 1998;25:73-5.
2. Kupietzky K, Milton H. Hypohidrotic ectodermal dysplasia: Prosthetic managment of Hypohidrotic ectodermal dysplasia. *Quintessence Int* 1995; 26:285-91.
3. Richard AS, Karin V, Gerard K, Caries B, Kournjiarn J. Placement of an endosseous implant in a growing child with ectodermal dysplasia. *Oral Surg, Oral Med, Oral Pathol* 1993; 75:669-73.
4. Shaw RM. Prosthetic management of Hypohidrotic Ectodermal dysplasia with anodontia. Case report. *Aust Dent J* 1990;35;113-6.
5. Piegno MA, Blackrnan RB, Cronin RJ, Cavazos E. Prosthodontic management of ectodermal dysplasia: A review of the literature. *J Prosthet Dent* 1996;76:541-5.
6. Tanner BA. Psychological aspects of Hypohidrotic ectodermal dysplasia. *Birth Defects* 1988; 24~263-75. 8. Nowak AJ. Dental treatment for patients with ectodermal dysplasias. *Birth Defects* 1988;24:243-52.
7. Clarke A, Phillips DIM, Brown R, Harper PS. Clinical aspects of X linked hypohidrotic ectodermal dysplasia. *Arch Dis Child* 1987; 62:989-96.
8. Thumman J. Two cases in which the skin hair and teeth were imperfectly developed. *Proceedings of the Royal Medical and Chirurgical Society* 1848;71:71-81.
9. Civitelli R, McAlister W, Teitelbaum S, Whyte M. Central osteosclerosis with ectodermal dysplasia: clinical, laboratory, radiologic, and histopathologic characterization with review of the literature. *JBone Miner Res* 1989;6:863-75.
10. Ruprecht A, Chaney SA, Shokeir MHK. Ectodermal dysplasia associated with cleft palate and lobster claw deformity of hands and feet. *J Can Dent Assoc* 1986;2:147-50.