

Comparative study between fine needle aspiration cytology and histopathology in the diagnosis of breast lump

Chetan K B^{1*}, Sreenivas N²

¹MBBS Student, ²Professor, Department of Pathology, Mysore Medical College and Research Institute Karnataka, India

***Corresponding Author:**

Email: chetankbc2@gmail.com

Abstract

Aims and Objectives: 1. To compare the results of fine needle aspiration cytology (FNAC) and histopathological study of biopsy in detecting breast cancer in suspicious breast lumps in outpatient setting.; 2. To study the accuracy of FNAC in diagnosing various breast lumps.; 3. To know whether the cancer patients can be managed based on FNAC diagnosis alone without histological study.

Methodology: It was a hospital based retrospective study carried out from the data retrieved from the Dept. of Pathology of Mysore Medical College, Mysore in a period from August 2016 – September 2016.

Period of Study: 2 months, **Sample Size:** 50 patients.

Results: In the present study, FNAC had sensitivity of 50%, specificity of 100%, positive predictive value of 100%, negative predictive value of 88.37%. In this case FNAC is highly specific with maximum positive predictive value.

Conclusion: Benign neoplasms of the breast are more common than malignant one. The present study shows FNAC correlation with histopathology with high specificity and maximum positive predictive value. The sensitivity of FNAC is less compared to biopsy. However, FNAC can be used as an indicative diagnosis (one stop) for breast cancer examination in outpatient setting. Accuracy of FNAC enables to proceed with surgery or not. It bridges the gap between clinical evaluation and final surgical pathological diagnosis in majority of cases. It enables the clinician to obtain a diagnosis in high percentage of cases with minimal expenditure of time, and money and often to avoid unnecessary surgery.

Keywords: Fine needle aspiration cytology, Sensitivity, Specificity, Diagnostic accuracy.

Introduction

Worldwide breast cancer is the leading type of cancer in women accounting for 25% of all cases.¹ In 2012, it resulted in 1.68 million cases and 5,22,000 deaths. It is more common in developed countries² and is more than 100 times more common in women than in men.^{3,4}

Most type of breast cancers are easy to diagnose by microscopic analysis of a sample or a biopsy of the affected area of the breast. Also they are types of breast cancer that require specialized lab exams.

Here are some screening tests in the handling of suspicious lesions of breast cancer.

1. Fine Needle Aspiration Cytology (FNAC).
2. Histopathological study of biopsy.

The sensitivity and specificity of FNAC and biopsy as a diagnostic tool of breast cancer is actually a controversial subject of discussion.

Despite the wide use of FNAC for palpable breast masses, it has not achieved improvement in the pre-surgical decision-making and management process by both surgeon and the oncologist.⁵

Due to development in patient education and screening programs, there is marked increase in the detection of tumours and use of FNAC procedure. However many surgeons are reluctant to accept FNAC reports as basis for definitive diagnosis.⁶

FNAC reports still have percentage of uncertainty, also lack important information about the histopathological type, grade, receptors and intrinsic behaviour of the tumour. All of this information is of

great importance for correct preoperative evaluation by both surgeon and oncologists.⁷ The biopsy of palpable breast based on histological study of tissue specimen can provide all the reliable information to guide the surgeon and the oncologist for ideal modern therapeutic strategy in surgical decision making.⁸

This study helps us to compare the results of FNAC and biopsy in detection of breast lesion pathology.

Materials and Methods

Study Design: It was a hospital based retrospective study carried out from the data retrieved from the Dept. Of Pathology of Mysore Medical College, Mysore in a period from August 2016–September 2016.

Source of Data: Female patients with c/o palpable breast lump attending the surgery department referred to department of pathology for FNAC and histopathology of palpable breast lumps in Mysore Medical College and K. R. Hospital, Mysore.

Period of Study: 2 months

Sample Size: 50 patients

Inclusion Criteria: All female patients with unknown primary diagnosis of palpable breast mass/lumps undergoing FNAC followed by excision biopsy/lumpectomies or mastectomy.

Exclusion Criteria: 1. Non-palpable breast sample 2. Palpable breast masses in males 3. Patients who underwent FNAC but did not undergo subsequent histopathological diagnosis.

Clinical Methods: Procedure of FNAC: The skin above the area to be biopsied is swabbed with an antiseptic solution and draped with sterile surgical towels. The skin, underlying fat, and muscle may be numbed with a local anesthetic, although this is often not necessary with superficial masses. After locating the mass for biopsy, using x-rays or palpation, a special needle of very fine diameter is passed into the mass. The needle may be inserted and withdrawn several times. There are many reasons for this:

1. One needle may be used as a guide, with the other needles placed along it to achieve a more precise position.
2. Sometimes, several passes may be needed to obtain enough cells for the intricate tests which the cytopathologists perform.

After the needles are placed into the mass, cells are withdrawn by aspiration with a syringe and spread on a glass slide. The patient's vital signs are taken again, and the patient is removed to an observation area for about 3 to 5 hours.

All the slides will be reviewed and their diagnosis made. FNAC diagnoses will be compared with histopathology in cases which undergo surgical excision and thus its diagnostic accuracy will be determined.

Ethical Clearance : Ethical committee approval was taken before the study.

Results

The present study comprises of 50 cases of breast lumps which were evaluated by clinical examination, fine needle aspiration cytology (FNAC). The study was conducted over a period of 2 months from 1st August 2016 to 30th September 2016 in the Department of Pathology, Mysore Medical College and Research Institute, Mysore. All the cases were subsequently evaluated histopathologically. The following observations were made.

Distribution of cases according to age

Table 1 : Age distribution of patients with benign and malignant breast lump

Age group(years)	No. of cases	Percentage
10 – 20	15	30
21 – 30	12	24
31 – 40	7	14
41 – 50	8	16
51 – 60	6	12
61 – 70	2	4
Total	50	100

The age of patients ranged from 16 to 65 years, with a mean age of 33.5 years. The maximum number of lesions were seen in the age group of 10-20 years (30%), followed by 21-30 years (24%) and 41-50 years (16%). The least number of cases were seen in patients of age group 61-70 years (4%).

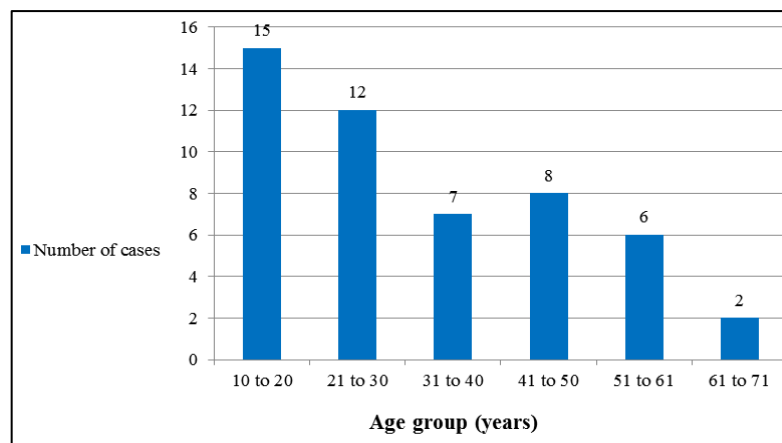


Fig. 1: Age distribution patients with Benign and malignant breast lump

Distribution of cases according to the side of affected breast

Table 2 : Distribution of breast lumps according to the side of affected breast

Side	No. of cases	Percentage
Right breast	22	44
Left breast	26	52
Bilateral	2	4
Total	50	100

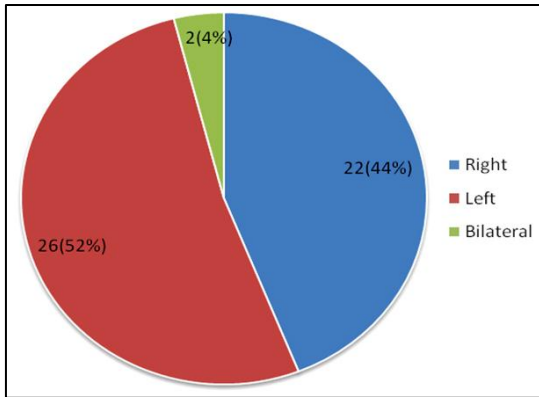


Fig. 2 : Distribution of breast lumps according to the side of affected breast

Among the 50 cases of breast lumps, it was observed that left breast was more commonly involved comprising of 26 cases (52%). Right breast was involved in 22 cases (44%) and bilateral involvement was seen in only 2 cases (4%).

Distribution of Cases According to the Involvement of Quadrant: In the study group, there were 4 cases where multiple quadrants were involved in each patient. Three patients had lumps in upper outer and upper inner quadrant of the same breast, one case presented with

involvement of upper outer and central quadrant. One case presented with lumps in upper inner quadrant of both the breasts. One case presented with lumps in upper outer quadrant of one breast and upper inner quadrant of another breast.

Table 3 : Distribution of breast lumps according to the quadrant of involvement

Quadrant involved	No. of cases	Percentage
Upper outer	28	50
Upper inner	17	30.36
Lower outer	3	5.36
Lower inner	6	10.71
Central	2	3.57
Total	56	100

The upper outer quadrant was seen to be the most common quadrant of involvement with 28 cases (50%). The next common quadrants to be involved were upper inner (30.36%) and lower inner (10.71%). The least number of cases occurred in central quadrant (3.57%).

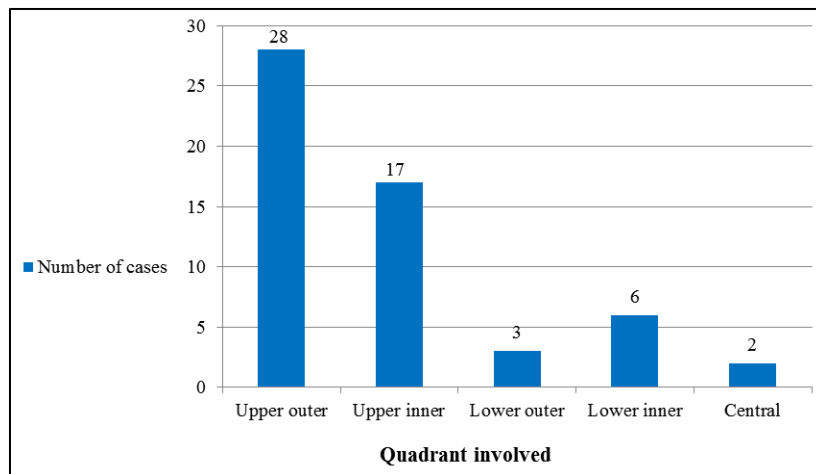


Fig. 3 : Distribution of breast lumps according to the quadrant of involvement

Distribution of cases based on FNAC diagnosis

Table 4 : Distribution of cases based on FNAC

FNAC diagnosis (UK category)	No. of cases	Percentage
C1	2	4
C2	38	76
C3	5	10
C4	1	2
C5	4	8
Total	50	100

FNAC of 50 cases revealed 38 cases in category C2, 4 cases in category C5, 5 cases of category C3 and 1 case of category C4. Only 2 cases were in C1 category i.e. the aspirate was brownish fluid was inadequate for opinion. Out of these two inadequate smears, on histopathology, one was ductal carcinoma in situ and other was infiltrating ductal carcinoma. the inadequacy rate for FNAC in this study was 4%.

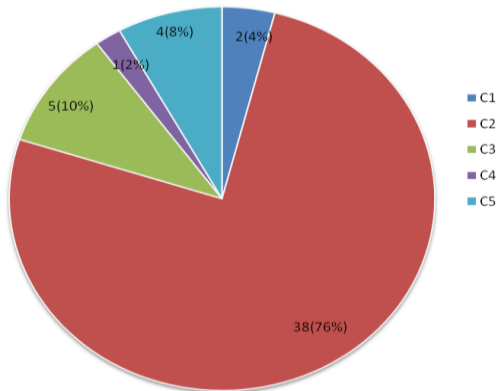


Fig. 4 : Distribution of cases based on FNAC

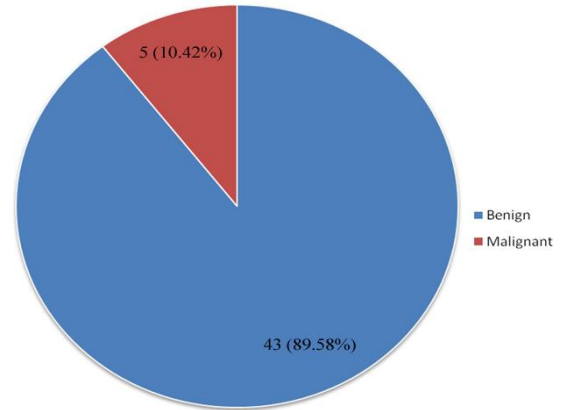


Fig. 5 : Distribution of benign and malignant lesions based on FNAC

Table 5: Distribution of Benign and malignant lesions based on FNAC

Lesions	No. of cases	Percentage
Benign	43	89.58
malignant	5	10.42
Total	48	100

Out of the 48 cases which were opined on FNAC, 43 cases were benign and 5 were malignant. benign lesions were those which were of categories C2 or C3 and lesions which were under C4 or C5 categories were considered malignant.

Distribution of cases based on histopathology

Table 6 : Distribution of cases based on histopathology

Histopathological Diagnosis	No. of cases	Percentage
Fibroadenoma	27	54
Fibrocystic Change	4	8
Fibroadenoma with Fibrocystic Change	5	10
Borderline Phyllodes	1	2
Adenosis with myoepithelial hyperplasia	1	2
Ductal Carcinoma insitu	1	2
Mucinous Carcinoma	1	2
Infiltrating Ductal Carcinoma	10	20
Total	50	100

On histopathology, Fibroadenoma was diagnosed in 27 cases, 10 cases were of Infiltrating ductal carcinoma, 5 cases were Fibroadenoma with Fibrocystic change and 4 cases were Fibrocystic change. There were one case of Borderline phyllodes, Adenosis with myoepithelial hyperplasia, Ductal Carcinoma insitu, Mucinous Carcinoma.

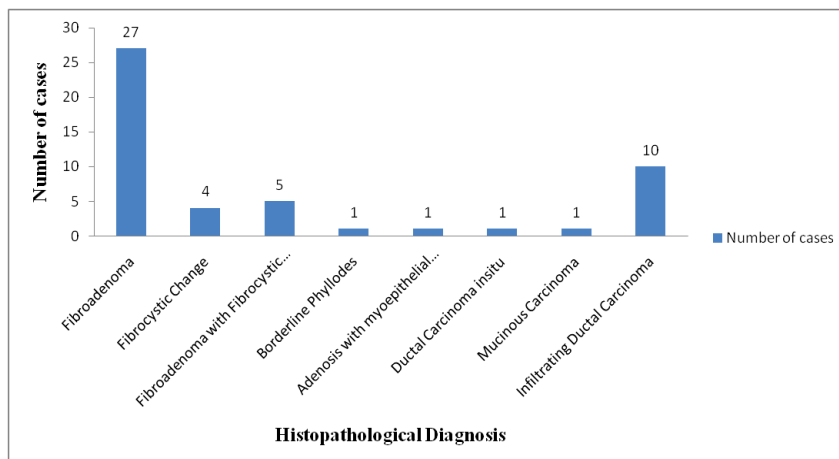
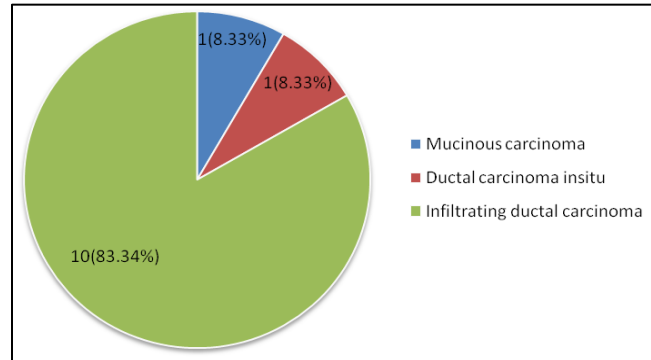


Fig. 6 : Distribution of cases based on histopathology

Table 7 : Distribution of various malignant neoplasms of breast

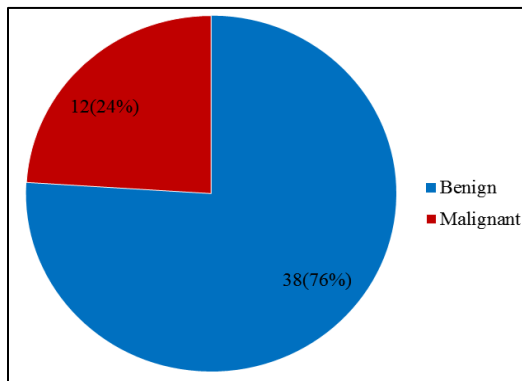
Malignant neoplasms	No. of cases	Percentage
Mucinous carcinoma	1	8.33
Ductal carcinoma insitu	1	8.33
Infiltrating ductal carcinoma	10	83.34
Total	12	100

**Fig. 7: Distribution of various malignant neoplasms of breast**

Among the 12 cases of malignant neoplasms of breast, 10 cases were infiltrating ductal carcinoma, 1 case each of mucinous carcinoma and ductal carcinoma insitu.

Table 8 : Distribution of benign and malignant lesions based on histopathology

Lesions	No. of cases	Percentage
Benign	38	76
Malignant	12	24
Total	50	100

**Fig. 8 : Distribution of benign and malignant lesions based on Histopathology****Table 9 : Comparison of FNAC diagnosis with histopathology**

FNAC diagnosis	Histopathologic Diagnosis		Total
	Benign	Malignant	
Benign	38(79.2%)	5(10.4%)	43(89.6%)
Malignant	0	5(10.4%)	5(10.4%)
Total	38(79.2%)	10(20.8%)	48(100%)

*Aspirates in two cases were inadequate for diagnosis on FNAC

The association between FNAC diagnosis and Histopathology was analysed using Fisher's Exact Test. The two-sided P value is 0.0001, considered extremely significant. The row/ column association is statistically significant. The FNAC diagnosis was compared with histopathological diagnosis (Gold standard). The following test parameters for FNAC diagnosis was analysed.

Variable	Value	95 % confidence interval
Sensitivity	0.5000	0.1871 to 0.8129
Specificity	1.000	0.9075 to 1.000
Positive Predictive Value	1.000	0.4783 to 1.000
Negative Predictive Value	0.8837	0.7491 to 0.9611

From this table we can conclude that FNAC for diagnosis breast malignancy has high specificity of 1 (100%) and relatively low sensitivity of 0.5 (50%). It also has high positive predictive value 1 (100%) and negative predictive value 0.88 (88.37%). Hence FNAC can be used as diagnostic test for the diagnosis of breast malignancy.

Discussion

The present study is of 50 cases of breast neoplasms, all of which were evaluated by FNAC and histopathology.

Distribution Pattern According to Age

Table 10 : Comparison of age distribution in different studies

Study group	Paramesh et al. ^[18]	Khan A et al. ^[19]	Touhid Uddin Rupom et al. ^[20]	Ghosh A et al. ^[30]	Shagufta T. Mufti et al. ^[31]	Present study
Age range (years)	17 – 82	15 – 70	20 – 80	16 – 72	16 – 80	16 – 65
Mean Age	38.6	41.43 ± 13.421	43.2	35.2	37.26	33.5

The age range in the present study was from 16 to 65 years with a mean age of 33.5 years. The maximum number of neoplasms were seen in the age group of 10 – 20 years (30%).

Distribution pattern according to the side of affected breast

Table 11 : Comparison of distribution pattern according to the side of affected breast

Side	Dr. Kiran Kumar P.S et al. ^[14]	Kamal Malukani et al. ^[15]	Present study
Right (%)	45.3	46.5	44
Left (%)	52.0	43.5	52
Bilateral (%)	2.7	10	4

In the present study, majority of lumps (52%) were situated in the left breast. This observation was also found similar in other studies.

Distribution pattern according to the quadrant involved

In the present study, majority of lumps (50%) were situated in the upper outer quadrant of the breast. This observation was also found by other studies.

Kamal Malukani et al.^[15] in a study of 200 cases where 20 cases had bilateral breast lumps, found that 107 lumps (48.64%) were found in upper outer quadrant.

Distribution pattern of various breast neoplasms

Table 12: Comparison of distribution pattern of various breast neoplasms in different studies

Studies	Paramesh et al. ^[18]	Adnan Khan et al. ^[19]	Khalid Usman et al. ^[40]	Aslam S, Hameed S, et al. ^[41]	Present study
Total no. of cases	55	74	200	56	50
Benign	33(60%)	24(32.43%)	147(73.5%)	31(55.36%)	38 (76%)
Malignant	22(40%)	50(67.57%)	53(26.5%)	25(46.64%)	12 (24%)

Out of 50 cases of breast neoplasms, 38 (76%) cases were benign, and 12(24%) cases were malignant.

These observations were similar to the findings in most of the studies.

Role of inadequacy of FNAC in breast neoplasms

Table 13 : Comparison of inadequacy rate of FNAC in various studies

Studies	Inadequacy rate(%)
Paramesh et al. ^[9]	4%
Kasonde Bowa et al. ^[18]	7%
Randa ZA Khair et al. ^[19]	13%
Present study	4%

In the present study, 2 out of 50 cases of breast lumps who underwent FNAC were inadequate for any definite opinion. This gives an inadequacy rate of 4% for FNAC. This value was observed similar in different studies.

Efficacy of various diagnostic modalities for breast neoplasms

Table 14 : Comparison of the efficacy of the various diagnostic modalities in different studies

Studies	FNAC			
	Sensitivity (%)	Specificity (%)	Positive Predictive Value (%)	Negative Predictive Value (%)
Paramesh et al. ^[18]	95.45	100	100	97.06
Ghosh A et al. ^[30]	90.2	100	100	87.5
Khalid Usman et al. ^[40]	85.96	88.81	75.38	94.07
Present Study	50	100	100	88.37

In the present study, FNAC had sensitivity of 50 %, specificity of 100%, Positive predictive value of 100%, Negative predictive value of 88.37%. In this case FNAC is highly specific with maximum Positive predictive value.

Conclusion

Benign neoplasms of the breast are more common than malignant one. The present study shows FNAC correlation with histopathology with high specificity and maximum positive predictive value. The sensitivity of FNAC is less compared to biopsy. However, FNAC can be used as an indicative diagnosis (one stop) for breast cancer examination in outpatient setting. Accuracy of FNAC enables to proceed with surgery or not. It bridges the gap between clinical evaluation and final surgical pathological diagnosis in majority of cases. It enables the clinician to obtain a diagnosis in high percentage of cases with minimal expenditure of time, and money and often to avoid unnecessary surgery.

Biopsy is superior to FNAC in confirming breast cancer in suspicious lumps and it is able to give definitive histology of lesions.

Triple assessment approach including clinical, cytology and mammography would be the ideal approach for women with suspicious breast lump.

Assessment of FNAC alone would not be sufficient for the division of treatment as FNAC reports still have percentage of uncertainty, also lack important information about the histopathological type, grade, receptors and intrinsic behaviour of the tumour.

References

- World cancer report 2014, World health organisation 2014. PP. Chapter 1.1 ISBN 92-832-0429-1.
- World cancer report 2014, World health organisation 2014. PP. Chapter 5.2 ISBN 92-832-0419-1.
- World cancer report, International Agency for research on cancer 2008. Retrieved 26 February 2011.
- Male Breast cancer Treatment National cancer institute 2014. Retrieved 29 June 2014.
- Masood S, Frykberg ER, McLellan GL et al. Prospective evaluation of radiologically directed fine needle aspiration biopsy of non-palpable breast lesions. *Cancer* 1990;66:1480.
- Page DL, Johnson JE, Dupont WD. Probabilistic approach to the reporting of fine needle aspiration cytology of the breast. *Cancer Cytopathol* 1997;81:6-9.
- Florentine BT, Cobb CT, Frankel K et al. Core needle biopsy: a useful adjunct to fine needle aspiration patients with palpable breast cancer. *Cancer Pathology* 1997;81:33-9.
- Pinder SE, Elston CW, Ellis IO. The role of preoperative diagnosis in breast cancer. *Histopathology* 1996;28:563-6.
- Paramesh, Angshuman Saha, TM Kariappa. Correlation of fine needle aspiration cytology and histopathology in palpable breast lesions in 100 patients of KVG Medical College & Hospital, Sullia, Karnataka. *International Journal of Applied Research* 2015; 1(8): 422-427.
- Khan A, Jamali R, Jan M, Tasneem M. Correlation of Fine Needle Aspiration Cytology and Histopathology Diagnosis in the Evaluation of Breast Lumps. *Int J Med Students*. 2014 Mar-Jun;2(2):40-3.
- Touhid Uddin Rupom, Tamanna Choudhury, Sultana Gulshana Banu. Study of Fine Needle Aspiration Cytology of Breast Lump: Correlation of Cytologically Malignant Cases with Their Histological Findings. *BSMMU J* 2011; 4(2):60-64.
- Ghosh A, Ghartimagar D, Sathian B, Narasimhan R, Talwar OP. Fine needle aspiration cytology in breast lump – its

- cytological spectrum and statistical correlation with histopathology. *Ind J Comm Health*, 25(4); 451 – 459.
13. Shagufta T. Mufti and Ali S .Sawan. Comparative Study between Breast Cytology and Histology in Saudi Females. *JKAU: Med. Sci.*, Vol. 18 No. 1, pp: 37-55.
 14. Dr. Kiran Kumar P.S & Dr. Mahesh. G.S. Clinical Profile and Correlation between FNAC and Histopathology of Breast Lumps in a Teaching Hospital. *Global Journal of Human-Social Science: I Surgeries and Cardiovascular System* Volume 14 Issue 2 Version 1.0 Year 2014:9-12.
 15. Kamal Malukani, Garima Malpani, Gaurav Malpani, Amit V. Varma, Prashant S. Yeshwante. Diagnostic Accuracy of Fine Needle Aspiration Cytology in Benign and Malignant Breast Lesions. *Indian Journal of Pathology and Oncology*, April-June 2016;3(2);145-151 146.
 16. Khalid Usman, Bushra Nisar, Muhammad Sajid, Diagnostic Accuracy of Fine Needle Aspiration Cytology in a Breast Lump Using Histopathology as Gold Standard. *P J M H S* Vol. 9, NO. 1, JAN – MAR 2015:191-193.
 17. Shazia Aslam, Sadia Hameed, Tariq Afzal, Arif Hussain. Correlation of FNAC and histological diagnosis in the evaluation of breast lumps. *JUMDC* Vol. 3, Issue 2, Jul-Dec 2012:1-7.
 18. Kasonde Bowa, Jim Jewel, Victor Mudenda. Fine needle aspiration cytology in the investigation of breast lumps at the University Teaching Hospital in Lusaka, Zambia. *Tropical Doctor* 2008 Oct;38:245-7.
 19. Randa ZA Khair, Mohamed T Musa MI, Yahia Al-Tayeb Al-Arabi. Evaluation of cytopathology in diagnosing breast cancer in Khartou. *Khartoum Medical Journal* 2009;2(1):169-71.