

Case report on orthodontic treatment of a unique case of bilateral maxillary canine impaction, one buccal and another palatal

Poonam Majumder^{1,*}, Abhishek Singh², Manoj Sharma³, Heeralal Chokotiya⁴, Mahasweta Das Gupta⁵

¹Private Practitioner, Dept. of Orthodontics, Private Practice, Agra, Uttar Pradesh, ²Dental Surgeon, S.N.M. District Hospital, Firozabad, Uttar Pradesh, ³Medical Officer, Govt. of Rajasthan, ⁴Senior Lecturer, Dept. of Orthodontics, Mansarovar Dental College, Bhopal, Madhya Pradesh, ⁵Post Graduate Student, Regional Dental College, Guwahati, Assam, India

***Corresponding Author:**

Email: majumderpoonam87@gmail.com

Abstract

The maxillary permanent canine is second only to the third molar in frequency of impaction, with a prevalence of approximately 2 per cent of the population; the palatal canine impaction being 85% of the impacted canines. The orthodontist treating patients with palatally impacted canines usually strives to build a complex treatment plan, based on uncomplicated and biological orthodontic and surgical techniques. The aim of the present case report is to demonstrate the potential of the orthodontic treatment of impacted canine with fixed appliance and open surgical technique for stimulation of physiological eruption of palatally impacted canine. This is a case of 12 year old female patient with maxillary bilateral canine impaction, the right maxillary canine was impacted palatally and the left canine buccally respectively, being treated by surgical exposure and fixed orthodontic therapy.

Keywords: Impacted canine, Orthodontically guided eruption.

Introduction

After mandibular third molars, the maxillary canines are the second most commonly impacted teeth,¹ with palatal impactions prevailing over buccal impactions.^{2,3} Treatment approaches are aimed at the canines' correct occlusion, as well as function and esthetics of the dentition and can be divided into preventive and surgical.

The causes can be classified into 4 distinct groupings: local hard tissue obstruction, local pathology, departure from or disturbance of the normal development of the incisors, and hereditary or genetic factors.⁴ If orthodontic treatment is not started, there is always a risk of retention and also of resorption of the roots of the permanent incisors.

The most common treatment procedure in children and adolescents is surgical exposure followed by

orthodontic appliance treatment, where, as a rule, the primary canines are left in place until the orthodontist has moved the impacted tooth to this region.

Various surgical techniques for exposing palatally impacted canines exist: 1. technique of open eruption; 2. Technique of closed eruption; 3. Open eruption through a window; 4. Tunnel extrusion, etc.

Case Report

Diagnosis: A 12 year-old girl was referred to the orthodontic clinic for the unaesthetic appearance of her unerupted maxillary anterior teeth. The clinical examination revealed an Angle Class I molar relationship, a buccally positioned maxillary left canine high on the vestibule and the right canines were not seen in the arch.

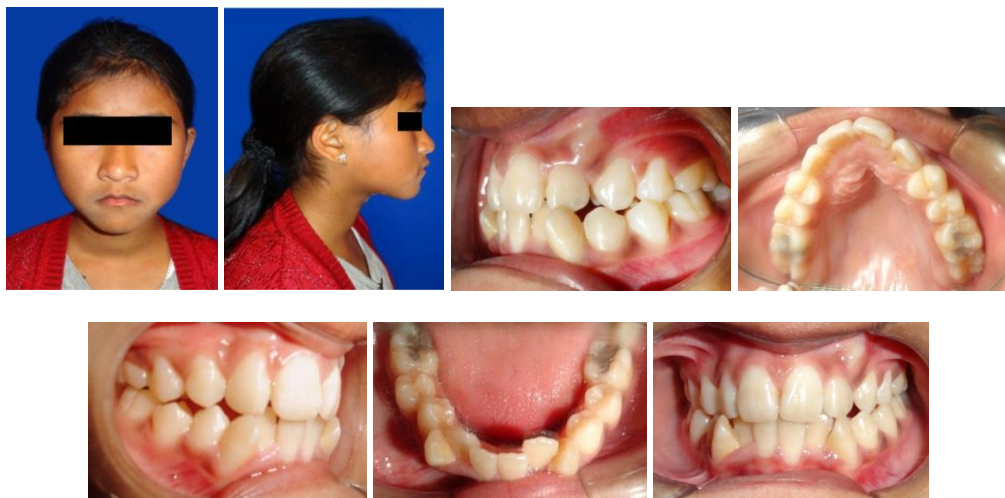

Fig. 1: Pretreatment photographs of the patient

On clinical examination a bulge was seen in the right anterior palatal side. Mandibular teeth were crowded with the canines lying buccally out of the arch.

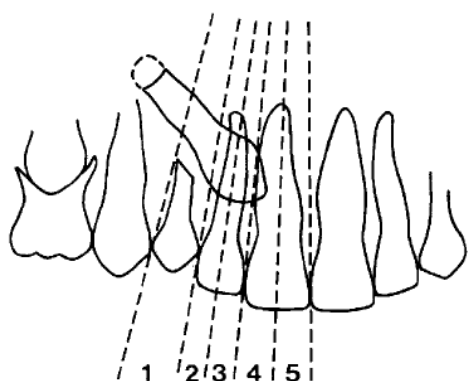
The radiological examination showed that the right permanent canine was impacted palatally (Fig. 2). They

were almost horizontally positioned, the incisal tip of the left canine being at the level of apex of the left central incisor, while the right canine was located approximately at the middle third of the root of the right lateral incisor.

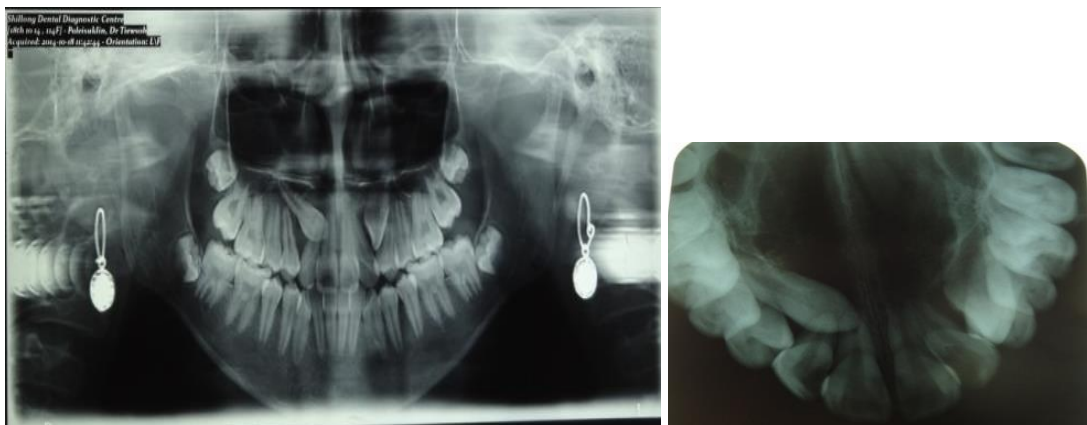

Fig. 2: Pre treatment OPG and occlusal radiograph

According to Ericson and Kurol's classification³ the medial displacement of the crown of the canine in relation to the long axis of the lateral incisor was grade IV impaction for tooth # 13.



Sector	1	2	3	4	5
--------	---	---	---	---	---

Fig. 3: Sector classification by Ericson & Kurol

Extraction of tooth 34,44 followed by 14,24 was decided because there was no space in the arch to align the impacted teeth in the maxillary arch and the crowded lower arch. Eruption of the left canine in the ectopic buccal position followed the extraction.

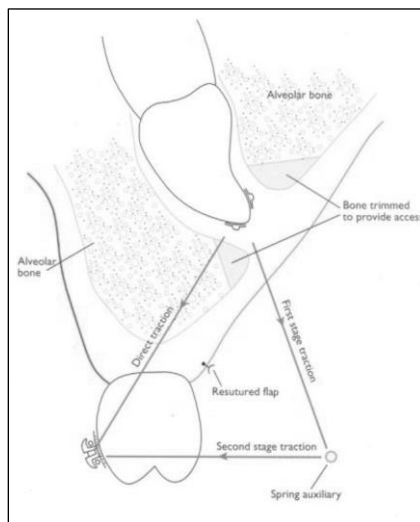


Fig. 4: Two stage traction

It was decided to undergo Two Stage traction because of its advantages like prevention of rotation and impingement of the rotated teeth with the adjacent teeth, better periodontal prognosis.

Treatment Progress: Bonding is done in the upper and lower arch with 0.022 MBT versatile plus (TP Ortho).

Leveling and alignment of teeth in the upper and lower dental arch by means of fixed appliance with 0.014, 0.016, 0.018, 0.017x0.025 Niti archwire sequence. Standard procedure for surgical uncovering and autonomous eruption was followed for all teeth:

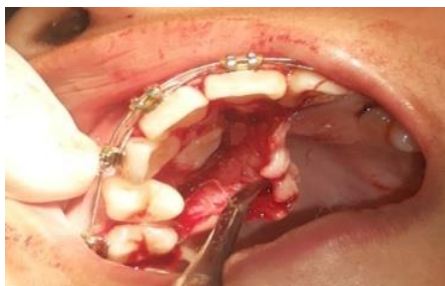

Fig. 5: Surgical exposure of the palatally placed canine

Incision of palatal mucosa and periosteum apically to the gingival sulcus on premolars and ipsilateral incisors, and then following the midline; elevation of a mucoperiosteal flap; removal of bone overlying the canine's crown from its tip down to the level of the cemento-enamel junction by means of a curette or a hand piece and bur (in deeply situated teeth); curettage of the follicle at the periphery of the dental crown;

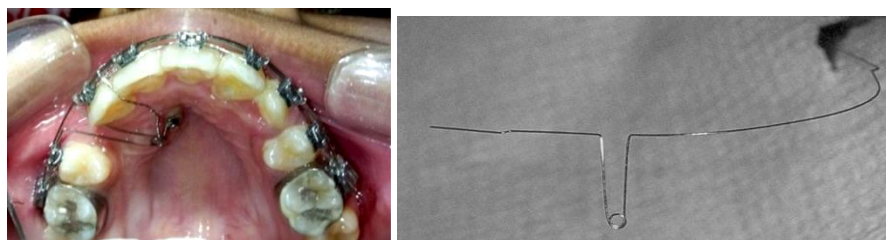


Fig. 6: Light auxiliary labial archwire fabricated and applied

Over the next six months, the progress of canine eruption was evaluated monthly. No complications were observed at the surgical site, and the gingiva remained healthy.

Once the canine had erupted in the occlusal direction sufficiently, the MBT bracket was bonded on the labial surface and the lateral movement of the canine was started with a 0.014 Niti auxiliary archwire along with the 0.017x0.025ss base archwire.

Discussion

The etiology of palatally displaced canine is obscure. Several etiological factors have been suggested,⁶⁻⁸ including arch dimension, mesiodistal width (MD-width) of teeth, tooth morphology, tooth size-arch length relationship, rate of root resorption of deciduous teeth, trauma of the deciduous tooth bud, disturbances in tooth eruption sequence, availability of space in the arch, rotation of tooth buds, and premature root closure.

With regard to arch dimension, some studies reported an association between maxillary excess and palatally displaced canine (PDC) and other studies reported an association between PDC and maxillary transverse deficiency,⁹ while still other studies¹⁰ reported no difference in arch width and controls.

repositioning of the flap; creating a small fenestration in the flap over the crown; suturing the flap.

Bonding of a lingual button on tooth 13 and movement of the canine laterally towards the arch started. First the vertical eruption was initiated using light auxiliary labial archwire (Kornhauser et al, 1996) made along with a stable 0.017 x 0.025 stainless steel base archwire which is fabricated as follows:

1. Fabricated using 0.014" round stainless steel wire.
2. Auxiliary consists of vertical loop with a small terminal helix in the area of the impacted tooth.
3. Auxiliary tied piggyback style into all brackets with the main archwire.
4. Extremities slotted into a spare tube on molars.
5. Vertical loops activated by pressing it palatally across the canine space and attaching to pigtail.
6. Useful for bilateral impactions.
7. Without base archwire it extrudes adjacent teeth/alters occlusal plane and moves teeth buccally.

Crowding was reported only in a minority of PDC subjects. On the other hand, several studies¹¹ reported excess dental arch space in subjects with PDC.

In the present case the large mesiodistal diameter of the maxillary anteriors along with the narrow maxillary archform apparently contributed to the bilateral displacement of canine i.e. one palatally and othe buccally. As palatally impacted canines seldom erupt without surgical intervention¹² the conventional treatment for these teeth usually includes surgical exposure followed by orthodontic traction. With severe palatal impactions, surgical intervention usually requires palatal reflection followed by removal of the bone overlying the canine crown. Only enough bone is removed to place an orthodontic attachment on the tooth. The surgical caveat is that the cemento-enamel junction of the impacted tooth not be exposed. Exposure of the cemento-enamel junction has shown to cause excessive loss of alveolar supporting bone. No bone removal was however required in the present case, the tooth being erupted through a small window through the overlying attached gingival tissue of the palate in order to preserve the attached gingiva of the canine.

At the end of treatment, the palatally impacted maxillary right canine was positioned into proper alignment, resulting in a pleasing smile. (Fig. 7) Radiographically, the right canine displayed proper root

inclination and the incisors remained stable at the end of treatment. The duration of the traction was 11 months which elapsed between the application of the traction, the eruption of the cusp and alignment of the

impacted canine. Total treatment time was 18 months. For retention, a lingual bonded retainer from canine to canine was placed in the upper and lower anteriors.

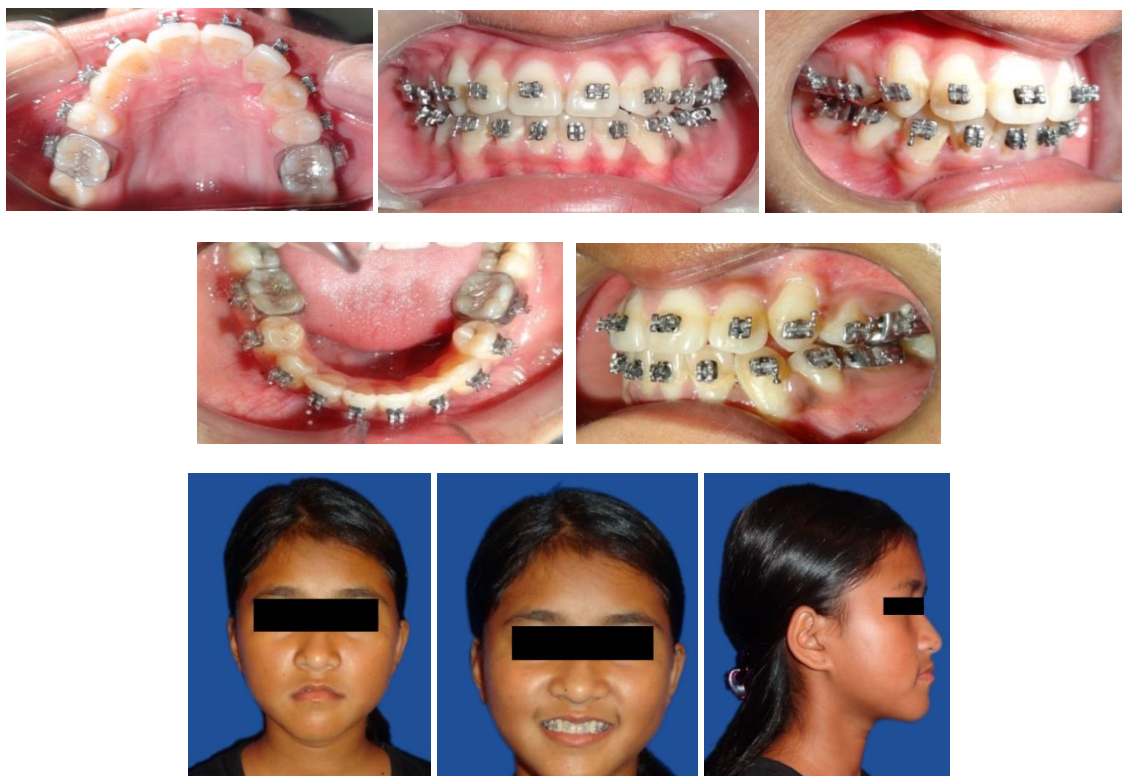

Fig. 7: Post treatment intraoral and extraoral photograph

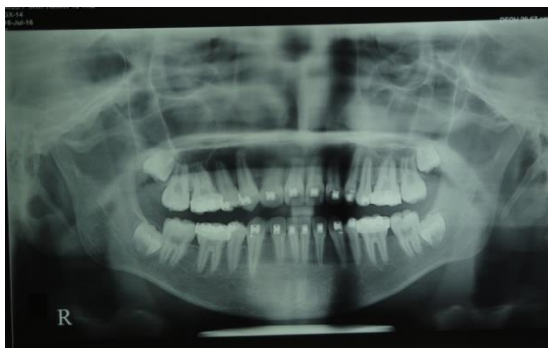

Fig. 8: Post treatment OPG

References

1. Moyers RE: Handbook of Orthodontics 4th ed. Chicago, IL, Year book Medical Publisher 1988.
2. Becker A., Smith P, Behar R. The incidence of anomalous maxillary lateral incisors in relation to palatally-displaced cuspids. *Angle Orthod.* 1981 Jan;51(1):24-29.
3. Ericson S, Kuroi J. Radiographic examination of ectopically erupting maxillary canines. *Am J Orthod Dentofacial Orthop* 1987 Jun;91(6):483-492. doi:10.1016/0889-5406(87)90005-9.
4. Adrian Becker and Stella Chaushu. Etiology of maxillary canine impaction: A review. *Am J Orthod Dentofacial Orthop* 2015;148:557-67.
5. Kokich VG, Mathew DS. Impacted teeth: Orthodontic and surgical considerations. In: McNamara Jr, editor. *Orthodontics and dentofacial orthopedics*. Ann Arbor (Mich): Needham Press;2001:395-422.
6. Bishara S. Impacted maxillary canines: a review. *Am J Orthod Dentofacial Orthop.* 1992;101:159-171.
7. Peck S, Peck L, Kataja M. Concomitant occurrence of canine malposition and tooth agenesis: evidence of orofacial genetic fields. *Am J Orthod Dentofacial Orthop.* 2002;122: 608-613.
8. Naser D, Abu Alhaija E, Al-Khateeb S. Dental age assessment in patients with maxillary canine displacement. *Am J Orthod Dentofacial Orthop.* 2011;140:848-855.
9. McConnell T, Hoffman D, Forbes D, Jensen E, Wientraub N. Maxillary canine impaction in patients with transverse maxillary deficiency. *J Dent Child.* 1996;63:190-195.
10. Langberg B, Peck S. Adequacy of maxillary dental arch width in patients with palatally displaced canines. *Am J Orthod Dentofacial Orthop.* 2000;118:220-223.
11. Jacoby H. The etiology of maxillary canine impactions. *Am J Orthod.* 1983;84:125-132.
12. Zilberman Y, Cohen B, Becker A. Familial trends in palatal canines, anomalous lateral incisors, and related phenomena. *Eur J Orthod.* 1990;12:135-139.
13. Jacoby H. The etiology of maxillary canine impactions. *Am J Orthod.* 1983;84:125-132.