

Hearing outcome between stapes graft assembly and stapes cartilage graft assembly in chronic otitis media active squamous disease

Anuj Shah^{1,*}, Rupa Parikh², Vikram Patel³

¹Senior Resident, ²Professor & HOD, ³Assistant Professor, Dept. of ENT, ^{1,3}GMERS Medical College, Vasad, Gujarat, ²Surat Municipal Institute of Medical Education and Research, Surat, Gujarat, India

***Corresponding Author:**

Email: anujshah.1989@gmail.com

Abstract

Introduction: The cholesteatoma is a sac lined by keratinizing stratified squamous epithelium in the middle ear cleft with continuous desquamated epithelium arranged like onion skin layers. It is also known as the non-malignant bone destroying disease of the middle ear cleft. Our study aims to compare the hearing outcome in these active squamous cases after doing stapes-cartilage-graft assembly and stapes-graft assembly in patients undergoing reconstruction in canal wall down mastoidectomy with type III tympanoplasty.

Materials and Method: Total number of 50 patients with chronic otitis media active squamous disease, who had undergone different types of ossicular chain reconstruction by type III tympanoplasty with canal wall down mastoidectomy between January 2017 and September 2017, were enrolled in the study. Post-operative hearing gain were evaluated by pure tone audiometry at 6 months after surgery.

Results: In terms of air-bone gap, stapes cartilage graft assembly patients have more improvement in hearing than patients with stapes graft assembly. We found 11.2 DB improvement with stapes-cartilage-graft assembly as compared to 5.76 DB in stapes-graft assembly.

Conclusion: Canal wall down mastoidectomy with type III tympanoplasty, stapes-cartilage-graft assembly technique have more hearing improvement than stapes graft assembly technique.

Keywords: Chronic Otitis Media active squamous type, Mastoidectomy, Stapes-Cartilage-Graft Assembly, Stapes Graft Assembly.

Introduction

Chronic Otitis Media squamous disease, previously known as the attic-antral type usually presents with marginal perforation having cholesteatoma which is the hallmark of this condition and also considered as the complication producing element.^{1,2} The cholesteatoma is a sac lined by keratinizing stratified squamous epithelium in the middle ear cleft with continuous desquamated epithelium arranged like onion skin layers. It is also known as the non-malignant bone destroying disease of the middle ear cleft.³

Canal wall down (CWD) and canal wall up (CWU) mastoidectomy represent two surgical methods to middle ear cleft pathology. Canal wall down mastoidectomy with tympanoplasty which has lower rates of recurrence and fewer surgical procedures are needed. Canal wall up mastoidectomy with tympanoplasty does not require substantial anatomical modifications, require less postoperative care but has higher rates of recurrence or residual disease.⁴

This study was undertaken to compare the hearing outcome in Stapes-Graft assembly and Stapes-Cartilage-Graft assembly for ossicular chain reconstruction after CWD mastoidectomy.

Materials and Method

The present study was a retrospective longitudinal observational study carried out at the Department of ENT & Head & Neck Surgery in our institute for a

duration of 9 months, from January 2017 to September 2017.

Patients with chronic otitis media active squamous disease involving the middle ear and mastoid who needed a canal wall down mastoidectomy with tympanoplasty were considered for this study.

Patients with poor cochlear reserve or history of trauma to the ear or temporal bone or those suffering from complications of otitis media were excluded from this study. Patients who were advised revision surgery also not considered as also those who refused to participate in this study.

50 patients with squamous chronic otitis media, undergoing canal wall down mastoidectomy with tympanoplasty, who came for regular follow-up were included in this study. Out of the cases studied 28 were male and 22 were female.

Twenty five patients underwent type III tympanoplasty with stapes graft assembly technique. Rest twenty five patients had type III tympanoplasty with stapes cartilage graft assembly technique. In these patients cartilages were harvested from tragal cartilage. Adequate size of meatoplasty was performed routinely in all cases.

Objective assessment of hearing improvement was done at sixth post-operative month. Postoperative hearing assessment was documented by performing pure tone audiometry on each postoperative follow-up. A digital audiometer was used in all the cases. Air-bone

gap was calculated from air conduction and bone conduction thresholds of pure tone audiometry at 500 Hz, 1000 Hz, 2000 Hz & 4000 Hz determined at each follow-up. Postoperative hearing gain was calculated from pure tone audiometry before the operation and 6 months of the follow up examination. Mean differences in threshold were calculated for air and bone conduction or air-bone gap (ABG).

Statistical analysis

Statistical analysis was performed by using paired t test.

Results

In this study total numbers of 50 patients were selected. The male: female ratio was 1.2:1. The patients mostly belonged to low socioeconomic status. In 20

patients disease was in left ear, in 23 patients it was in right ear and in 7 patients it was bilateral.

Amongst the findings of tympanic membrane, In 21 patients it was postero-superior quadrant (PSQ) cholesteatoma, in 23 patients it was attic cholesteatoma and in 6 patients it was both attic & PSQ type. Ear discharge was the presenting symptom in most of the patients. Cholesteatoma was the most common pathology found amongst the operated ears (76.7%). While both cholesteatoma and granulations were seen in 16.7% of the cases. Rest patients had granulation tissue alone.

The average of air conduction and bone conduction thresholds, both preoperatively and postoperatively, along with air-bone gap were calculated. (Table I and Fig. 1)

Table I: Pre-op and post-op hearing levels of both the groups

Air conduction pure tone average (AC PTA), bone conduction pure tone average (BC PTA), air bone gap (ABG) and ABG gain before and 6 months after surgery in dB Group A: Stapes Temporalis fascia graft (TFG) assembly Group B: stapes Cartilage Graft assembly		
	Group A	Group B
AC PTA pre-op	48.83	48
AC PTA post-op	48.9	38.83
BC PTA pre-op	9.08	7.16
BC PTA post-op	16.58	11.36
ABG pre-op	39.74	45
ABG post-op	32.31	27.46
ABG Gain	7.43	17.53

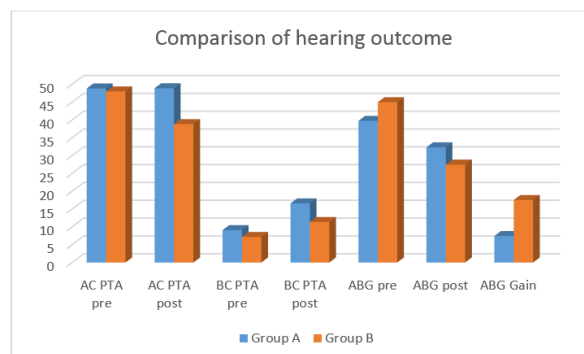


Fig. 1: Pre and post operative data on the hearing status of both the groups

We found significant statistical outcome after comparing both the groups and so stapes-cartilage-graft assembly is far more superior than only stapes-graft assembly. (Table II)

Table II: Hearing gain comparison

		Pre Operative ABG(dB)	Post Operative ABG(dB)	Hearing Gain(dB)	P Value
Group A	Mean				
	Standard Deviation	9.66	12.97		
	Minimum	19	13.5		

	Maximum	55	52.5		
Group B	Mean	36.79	25.07	11.72	0.0001
	Standard Deviation	16.13051	13.7927		
	Minimum	15	10		
	Maximum	63.75	42		

Discussion

Chronic otitis media is a chronic infection or inflammation of the middle ear and mastoid. It is accompanied by otorrhea and hearing loss. Treatment objectives include eradication of infection and restoration of tympanic membrane and hearing. Achieving all of these parameters in COM patients is difficult and controversial.^{5,6} Although ear surgery has been developing quite fast in the last 20-30 years, the choice of most appropriate surgical procedure is not clear in some patients with COM. Hearing results are affected by many parameters like current otorrhea, perforation type, ossicular status, granulation tissue or cholesteatoma in the middle ear.

Canal wall up mastoidectomy or CWD mastoidectomy techniques were preferred for eradication of disease according to these changing conditions, with advantages and disadvantages of each technique.⁷⁻⁹ Many prefer open cavity techniques over other techniques for common cholesteatoma, it has been stated in several studies that long-term hearing results in closed techniques are at least as successful as open techniques in treating cholesteatoma. Although recurrence has been more associated with closed cavity techniques, this risk cannot be eliminated entirely by open cavity techniques.¹⁰

Chang and Chen said they obtained better hearing results in patients with an intact stapes suprastructure.¹¹ De Corso et al. reported that the status of middle ear mucosa and presence or absence of stapes suprastructure are the most important factors for the successful restoration of postoperative hearing.¹²

Umit et al. reported that an ideal material is characterized by high biocompatibility, easy manipulation with minimal operation time and also high stability without extrusion or displacement.¹³

Conclusion

Canal wall down mastoidectomy with type III tympanoplasty, stapes-cartilage-graft assembly technique have more hearing improvement than stapes graft assembly technique.

References

- Hameed A, Ahmad M, Amjad M, Shakeel A, Rizvi A. Ossicular defects in cholesteatomatous chronic suppurative otitis media. *Pak Postgraduate Med J* 1998;9:35-7.
- O'Leary S, Veldman JE. Revision surgery for chronic otitis media: recurrent residual disease and hearing. *J laryngol Otol* 2002;116(12):996-1000.
- Cheema KM, Maqbool M, Hameed A. Surgical management of chronic suppurative otitis media. *Ann* 1998;4:23-4.
- Barry E Hirsch. Ossicular chain reconstruction. In: Operative otolaryngology Head and Neck surgery. (1edn). Philadelphia. W.B. Saunders company. 1997:1262-79.
- Sanna M, Zini C, Scandellari R, Jemmi G. Residual and recurrent cholesteatoma in closed tympanoplasty. *Am J Otol* 1984;5:277-82.
- Incesulu A. Chronic suppurative otitis media. *Turkiye Klinikleri J Surg Med Sci* 2005;1:66-70.
- Kartush JM. Ossicular chain reconstruction. Capitulum to malleus. *Otolaryngol Clin North Am* 1994;27:689-715.
- Austin DF. Reporting results in tympanoplasty. *Am J Otol* 1985;6:85-8.
- Becvarovski Z, Kartush JM. Smoking and tympanoplasty: implications for prognosis and the Middle Ear Risk Index (MERI). *Laryngoscope* 2001;111:1806-11.
- Cook JA, Krishnan S, Fagan PA. Hearing results following modified radical versus canal-up mastoidectomy. *Ann Otol Rhinol Laryngol* 1996;105:379-83.
- Chang CC, Chen MK. Canal-wall-down tympanoplasty with mastoidectomy for advanced cholesteatoma. *J Otolaryngol* 2000;29:270-3.
- De Corso E, Marchese MR, Sergi B, Rigante M, Paludetti G. Role of ossiculoplasty in canal wall down tympanoplasty for middle-ear cholesteatoma: hearing results. *J Laryngol Otol* 2007;121:324-8.
- Umit T, Ozgur Y, Bilgehan G, Volkan SA, Sezim SA. Results of primary ossiculoplasty and prognostic factors in canal wall-down tympanoplasty. *J Craniofac Surg* 2010;21:407-10.