

Cytomegalovirus retinitis in post HAART era in the north eastern India

Rajkumari Vidyarani Devi^{1,*}, Kamson Anthony², Meirenbam Ranjana³, Rajkumar Victor⁴

¹Associate Professor, ²Assistant Professor, ^{3,4}Senior Resident, Dept. of Ophthalmology, Jawaharlal Nehru Institute of Medical Sciences, Imphal, Manipur, India

***Corresponding Author:**

Email: drvidya777@gmail.com

Abstract

Context: HIV prevalence in India is estimated at 0.26% in 2015 with 0.30% among males and at 0.22% among females. Manipur being the highest estimated adult HIV prevalence among all states/UTs (1.15%) in India, Cytomegalovirus (CMV) retinitis and its consequent blindness is still a major challenge demanding early diagnosis and treatment.

Aims: Prevalence of CMV retinitis between the groups of AIDS patients according to their different levels of CD4 T lymphocyte counts

Settings and Design: Retrospective, descriptive study.

Materials and Methods: A total of 682 HIV patients with mean age of 33 years were evaluated. CD4 count and treatment status including best corrected visual acuity and examination of anterior and posterior segment by slit lamp biomicroscope, IDO and fundus photography were done. Confirmed cases of CMV retinitis was excluded from other HIV retinopathy.

Statistical Analysis Used: by using Chi (χ^2) square test and simple Statistical tools

Results: Of the 682 person examined CMV retinitis was diagnosed in 24 patients, of which 20 patients were on ART. Prevalence of CMV retinitis in the study was 3.51%. Three cases (2.6%) of CMV retinitis out of 122 patients were observed within CD4 count between 100-299 cells/ μ l. Nine cases (7.6%) of CMV retinitis were observed out of 71 patients with CD4 count between 50-99 cell/ μ l. 12 cases (11.2%) of CMV retinitis was diagnosed out of 107 patients with CD4 count < 50 cells/ μ l. Bilateral CMV retinitis was seen in four patients (0.6%). Optic neuritis was seen in one patient.

Conclusions: Prevalence of CMV Retinitis is common in patients with CD4+ T lymphocytes < 50 cells/ μ l. Ocular symptoms and poor visual acuity may be misleading as sole criteria indicates the presence of CMV retinitis and advocate a systemic screening of all HIV patients with CD4 count < 100 cells/ μ l to detect the ocular changes due to CMV retinitis for early prevention from severe visual impairment.

Keywords: HIV/AIDS, Cytomegalovirus retinitis, CD 4 T lymphocyte, HAART.

Introduction

According to India HIV Estimation 2015 report, the prevalence of HIV/AIDS among adult (15-49 years) in India is estimated at 0.26% (0.22%-0.32%) in 2015 with 0.30% among males and at 0.22% among females.¹

Manipur is a tiny state in the north eastern India bordering Myanmar and lie between 23.83 degree and 25.68 degree north latitude and 93.03 degree and 94.78 degree east, longitude. It has the highest estimated adult HIV prevalence among all states/UTs (1.15%) in India followed by Mizoram (0.80%) and Nagaland (0.78%). Though declining trends in adult HIV prevalence are sustained in all of the high prevalence States.¹

The pattern of HIV transmission in Manipur was initially through sharing of needles and syringes among injecting drug users (IDUs).² Further more and more female sex partners of IDUs are infected with HIV leading to an increase spread of HIV among women with an estimated 80% or more of the women acquired HIV infection from their husbands.³

Ever since the first report on the ocular manifestations of AIDS by Holland *et al* in 1983, subsequent studies have described several HIV/AIDS related conditions in the eye and the orbit.^[4] Of the spectrum of opportunistic ocular infection, Cytomegalovirus (CMV) retinitis is the leading cause of blindness in HIV/AIDS patients.⁵

CMV (Human Herpesvirus-5) is a large genomic virus of herpesviruses family which causes influenza-like symptom in immunocompetent individuals and remains latent. However in immunocompromised patients such as HIV/AIDS it causes non-traumatic granulomatous infection and retinitis potentially leading to visual loss.⁵ Studies have indicated the high prevalence of CMV retinitis among individuals with CD4+ T lymphocytes counts less than 100 cells/ μ l.⁶

There are variation in the incidence of CMV retinitis (2 - 20%, India) relating to varied ART regimes, health care access and genetic make-up in developing south east Asian countries.^{7,8} Also, there are limited epidemiological report on the incidence of CMV retinitis in this part of the country with high burden of HIV/AIDS.

In this retrospective study, 24 CMV retinitis patients out of 682 HIV infected patients admitted and referred from other centers to our institute were analyzed for the spectrum of CMV retinitis including the prevalence, relationship between CMV retinitis and CD4+ T lymphocyte counts.

Materials and Methods

The Study was conducted at department of ophthalmology, Jawaharlal Nehru Institute of Medical Sciences (JNIMS), Imphal from June 2013 - July 2016.

A total of 682 patients with HIV/AIDS patient who were referred to our Outpatient Department from ART centre at JNIMS, Hospitalized patients and other centers were included in this study. The patients were evaluated for CD4+ T Lymphocytes cell count and treatment status. A complete ophthalmological examination including refraction with best corrected visual acuity, examination of anterior segment by slit lamp biomicroscope, detail funduscopy was done using Indirect Ophthalmoscopy and 90D biomicroscope and standard 45 degree fundus photo was also recorded for the patients with posterior segment findings. The diagnosis of CMV retinitis was confirmed with typical ophthalmoscopic appearance of retinopathy that is yellow-white lesions with granular border or arciform retinal lesion with or without haemorrhage along the vessels.

We have excluded HIV retinopathy, toxoplasmosis retinitis, acute retinal necrosis, progressive outer retinal necrosis etc and all the cases were confirmed by two ophthalmological units.

Statistical Analysis

Statistical analysis were conducted to established the prevalence of CMV retinitis between the groups of HIV/AIDS patients according to their different levels of CD4+ T lymphocyte counts by using Chi(χ^2) square test. P values less than <0.05 is considered significant.

Results

Out of the 682 patients, 321 patients were females, 361 patients were male and four transgenders patients. The mean age of the study population was 33 year with majority of them belongs to the age group of 30-50 years. Twenty-four patients were diagnosed with CMV retinitis. Of the 24 patients, 20 patients were on ART. The duration of ART treatment ranges from 2 months to 11 years.

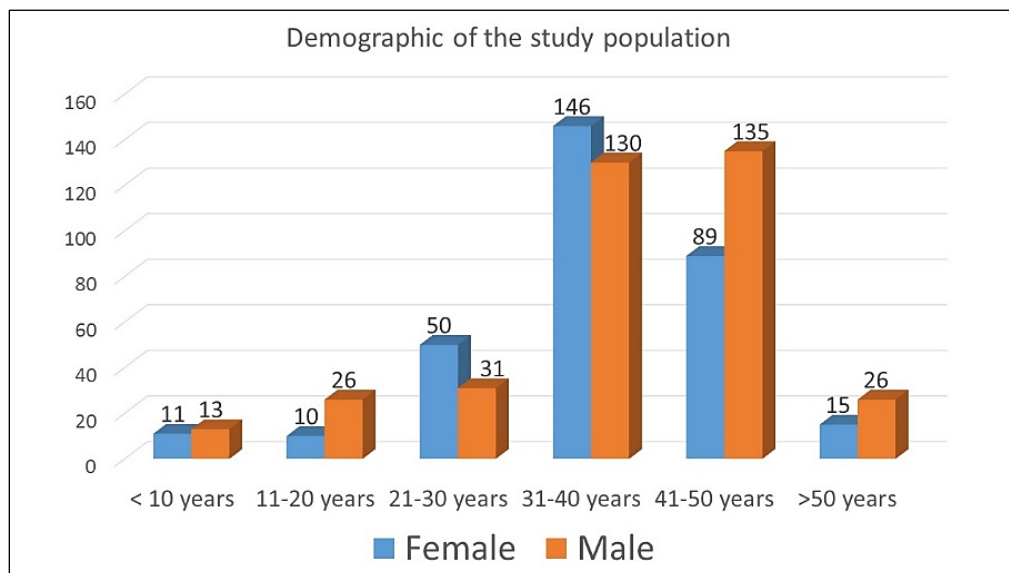


Fig. 1: Demographic of the study population

The prevalence of CMV retinitis in this study was 3.51% (24/682). No CMV retinitis was observed in patients with CD4 count of >300 cells/ μ l. Three (2.6%) CMV retinitis out of 122 patients was seen in patient with CD4 count between 100-299 cells/ μ l. Nine (7.6%) CMV retinitis were observed out of 71 patients with CD4 count between 50-99 cells/ μ l. Twelve (11.2%) CMV retinitis out of 107 patients was seen with CD4 T

lymphocyte count below 50 cells/ μ l. Bilateral CMV retinitis was seen in four patients (0.6%). Fulminating type of CMV retinitis was seen in majority of the patients followed by granular and frosted angitis type. Optic neuritis with infiltration around the optic disc was observed in one patient. 115 patients had CD4 count between 300-499 cells/ μ l and 267 patients had CD4 count above 500 cells/ μ l. Visual acuity of one patient could not be trace back due to data lost.

Table 1: The prevalence of CMV retinitis with different levels of the CD4 T lymphocyte counts

CMV Retinitis	CD4+T Cell count (cell/ μ l)					Total no.	P Value
	<50	50-99	100-299	300-499	>500		
With cmv retinitis	12	9	3	0	0	24	<0.001
No cmv retinitis	95	62	119	115	267	658	

Table 2: CD4 count, duration of ART, Best visual acuity at diagnosis, treatment

S. No	Sex	Age	CD4 count (date)	Start of ART	D.O.E	Retinal pathology	VA	Treatment (D.O.T)
1(BE)	M	23	15 (11-03-13)	2.5yrs	28-02-13	CMV(BE)	3m/CF@1m	Valgan (28-02-13)
2	F	38	38 (08-02-14)	5yrs	11-02-14	CMV(LE)	6/36	Valgan (11-02-14)
3	F	28	55 (08-01-14)	5.5yrs	05-05-14	CMV + VITRITIS(RE)	HM	Valgan (18-06-14)
4	F	43	82 (14-02-14)	1yr	16-02-15	CMV(LE)	4/60	Valgan (16-02-15)
5	M	34	28 (03-11-14)	nil	11-03-15	CMV(LE)	6/60	ART+Valg (18-03-15)
6	M	30	159 (20-03-15)	1.5Yrs	30-04-15	CMV(LE)	6/12	Valgan (30-04-15)
7	M	35	21 (28-04-15)	6Months	29-04-15	CMV(LE)	6/24	Valgan (29-04-15)
8	M	27	67 (02-03-15)	3months	06-05-15	CMV+VITRITIS	Pl+	Valgan (06-05-15)
9	F	28	94 (18-01-15)	7yrs	18-06-15	CMV(RE)	5/60	Valgan (18-06-15)
10	M	39	131 (10-01-15)	3yrs	10-06-15	CMV(RE)	CF@1m	Valgan (10-06-15)
11	F	22	33 (12-05-15)	3yrs	11-06-15	CMV(RE)	4/60	Valgan (11-06-15)
12(BE)	M	47	58 (03-06-13)	Nil	12-06-15	CMV(LE)	CF@3m	ART+Valg (12-06-15)
13	F	30	35 (29-01-14)	1yr	03-07-15	CMV(LE)	6/60	Valgan (03-07-15)
14	M	31	129 (31-08-15)	2.5yrs	30-09-15	CMV(RE)	6/36	Valgan (30-09-15)
15(BE)	M	40	56 (06-10-15)	Nil	08-10-15	CMV(LE)	5/60	ART+Valg (08-10-15)
16	F	40	48 (26-09-15)	1yr	01-12-15	CMV(LE)	6/24	Valgan (01-12-15)
17	F	32	05 (14-05-16)	3.5yrs	26-01-16	CMV(LE)	NA	Valgan (26-01-16)
18	F	40	125 (08-01-16)	2yrs	08-02-16	CMV(RE)	CF@3m	Valgan (08-02-16)
19	M	40	61 (28-01-16)	5yrs	11-02-16	CMV(RE)	6/60	Valgan (11-02-16)
20	M	43	68 (31-08-15)	1yr	17-02-16	CMV(RE)	5/60	Valgan (17-02-16)
21	F	35	46 (07-10-16)	4yrs	09-02-16	CMV(RE)	6/60	Valgan (09-02-16)
22	M	16	27 (05-04-16)	11yrs	05-04-16	CMV+VITR	HM	Valgan (05-04-16)
23	M	34	05 (11-02-16)	2month	06-04-16	CMV(RE)	CF@1m	Valgan (06-04-16)
24(BE)	M	43	06 (31-05-16)	Nil	16-6-16	CMV+ON	PL-	ART+Valg (16-06-16)

Note: BE: Bilateral Eye, LE: Left Eye, RE: Right Eye, CF@1m: Counting Finger at one Meter, HM: hand movement, PL: Perception of Light. D.O.E: Date of examination. D.O.T: Date of Examination, VA visual Acuity. NA : Not available

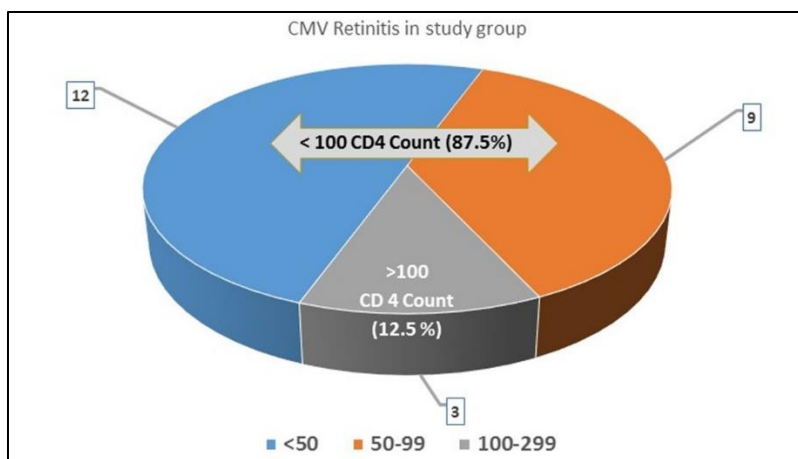


Fig. 2: Prevalence below and above 100 CD4 cell count

Discussion

The prevalence of CMV retinitis has declined over the last 5 years as ART has become more widely available and the immune status of patients progressively improved. Previous study by the same author in relation to ocular manifestation in HIV/AIDS, the CMV retinitis was reported 13.8% (12/87) with 8 cases (9.2%) in CD4 Count 51-199 cells/ μ l and 4 cases (4.6%) in CD4 count less than 50 cells/ μ l.⁹

Studies recommend systemic screening of CMV retinitis in patients with a CD 4 count of < 100 cells/ μ l and mandatory screening practice of patients with absolute CD4 count of <50 cells/ mm^2 or less at the time of diagnosis with or without ocular symptoms aiming at preventing severe visual loss in early stages.^{6,10,11}

Yingna liu et al found 15.5% (16/103) patients under CD4 count under 100 cells/ μ l with CMV retinitis, 9 patients reported ocular symptom beforehand similar to present study with 12 patients with ocular symptoms and with 9 patients with visual acuity of worse than Counting Finger in the worse seeing eye (78%, 7/9 had CD4 count <100 of which 4 had level less than 50 count and 22%, 2/9 had CD4 count more than 100 counts).⁶

Geographically more closure country than mainland India is the Myanmar where notably high prevalence of CMV retinitis (24% CMV retinitis, 211/891) was identified stressing the importance of routine CMV retinitis screening.¹² lack of awareness, limited facilities in remoted areas (more than 70% of state) and associated social stigma are all contributing to the huge submerged ice berg phenomenon in these geographically isolated these part of India.

CMV retinitis remains the most common manifestation of HIV in mainland studies and also its high prevalence suggest implementation of an effective screening procedure in this region and recommend an improvised strategy to increase the more likely hood of a screening procedure.^{13,7} Lai et al noted that CD4 count less than 100 cell/ mm^3 (χ^2 -test, $p=0.013$) was significantly associated with ocular symptoms.¹⁴ However Morjaria et al in their study emphasized that a

CD4 count lower than 50 cells/ mm^3 as the single most important risk factor for the development of CMV retinitis, with a hazard ratio of 136 (95% confidence interval, 30–605) and an incidence rate of 3.89/100 person-years.¹⁵

In the present study Bilateral CMV retinitis was noted in four patients (0.6%) interestingly all the four had not started Antiretroviral therapy (ART) at the time of diagnosis. Chen C et al in a comparative study noted that number of cases with both eye involvement was more in case of CMV retinitis group (bilateral eye case, 53.66% CMVR) than cases with microvascular retinopathy (MVR) (single eye case, 55.77%).¹⁶ The raw proportion of bilateral cases of CMV retinitis in various studies was reported as 42.9% (95% CI, 38.9%–47.0%).¹⁷

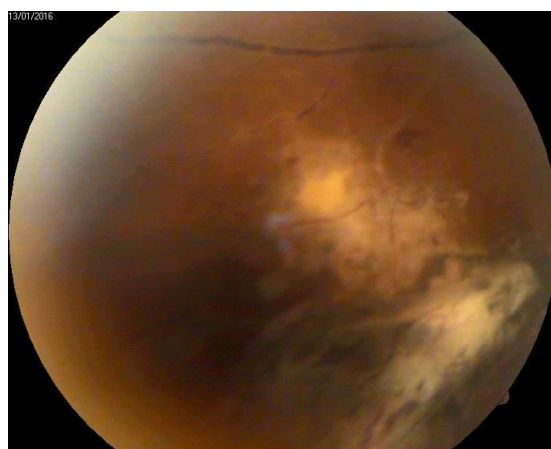


Fig. 3: Active CMV retinitis

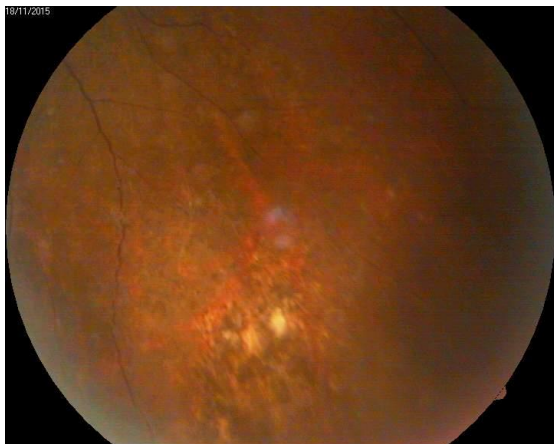

Fig. 4: Salt and Pepper irregular pigmentation

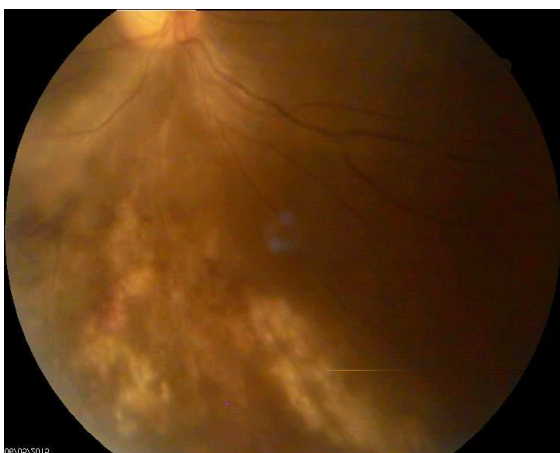

Fig. 5: Active CMV retinitis: Irregular white border with satellite lesions

CMV retinitis causes a mixed pattern of visual loss. A decreased visual acuity here means best corrected visual acuity of $\leq 6/12$. Despite the reduced incidence and severity of retinitis in the post Highly active anti-retroviral therapy (HAART) era, studies have affirmed that the ophthalmoscopic appearance of CMV retinitis does not appear to have changed with ocular complications of AIDS in patients with newly diagnosed CMV retinitis in the post-HAART era resembling those prior to the introduction of HAART except for the disease location, severity and immune status.^[18] CMV retinitis leading to visual loss is predominately due to maculopathy but its varying degree of vitritis and full thickness involvement can lead to necrosis and retinal breaks and detachments.

In present study, fulminating type of CMV retinitis followed by granular and frosted angitis type was seen in majority of cases. Optic neuritis was seen in one patient. All patients with diagnosed CMV retinitis was started with oral valganciclovir on or within week of diagnosis.

Conclusion

We conclude that prevalence of CMV Retinitis is common in patients with CD4+ T lymphocytes < 50

cells/ μ l. Ocular symptoms and poor visual acuity may be misleading as sole criteria indicates the presence of CMV retinitis and advocate a systemic screening of all HIV patients with CD4 count < 100 cells/ μ l to detect the ocular changes due to CMV retinitis for early prevention from severe visual impairment.

Acknowledgement: Thokchom Opendro Singh, Department of Biochemistry for giving valuable input on CMV viral genome and CD 4+ T Lymphocytes.

Conflicting Interest: NIL

References

1. NACO annual report 2014-15 [available on website: <http://naco.gov.in/hiv-facts-figures>]
2. Panda S, Bijaya L, Sadhana Devi N, Foley E, Chatterjee A, Banerjee D, et al. "Interface between drug use and sex work in Manipur." *Natl Med J India*. 2001;14(4): 209-211.
3. Panda S, Chatterjee A, Bhattacharya SK, Manna B, Singh PN, Sarkar s, et al. "Transmission of HIV from injecting drug users to their wives in India." *Int J STD AIDS*. 2000;11(7):468-473.
4. Holland GN, Pepose JS, Pettit TH, Gottlieb MS, Yee RD, Foos RY. Acquired immune deficiency syndrome: Ocular manifestations. *Ophthalmology*. 1983;90:859-873.
5. Stewart MW. Optimal management of cytomegalovirus retinitis in patients with AIDS. *Clin Ophthalmology*. 2010;4:285-299
6. Liu Y, Chen AS, Kamphaengkham S, Leenasirimakul P, Jirawison C, Ausayakhun S, et al. (2016) Diagnostic Utility of Ocular Symptoms and Vision for Cytomegalovirus Retinitis. *PLoS ONE*. 11(10):e0165564. doi: 10.1371/journal.pone.0165564]
7. Gharai S, Venkatesh P, Garg S, Sharma SK and Vohra R: Ophthalmic manifestations of HIV infections in India in the era of HAART: analysis of 100 consecutive patients evaluated at a tertiary eye care center in India. *Ophthalmic Epidemiol*. 2008;15(4):264-271.
8. Shi et al. Prevalence and clinical management of cytomegalovirus retinitis in AIDS patients in shanghai, china. *BMC Infectious Diseases*. 2011 11:326. doi: 10.1186/1471-2334-11-326
9. Vidyarani RK, Kaminibabu KH, Bhabanisana RK, Opendro TH, Sangeeta NG et al; Ocular manifestations of human immunodeficiency Virus / acquired immune deficiency syndrome in Manipur; *Int J Res Med*. 2013;2(2):34-39.
10. Kupperman BD, Petty JG, Richman DD, et al. Correlation between CD4+ counts and prevalence of cytomegalovirus retinitis and human immunodeficiency virus-related noninfectious retinal vasculopathy in patients with acquired immunodeficiency syndrome. *Am J Ophthalmol*. 1993;115(5):575-582.
11. Pertel P, Hirschtick RE, Phair J, et al. Risk of developing cytomegalovirus retinitis in persons infected with the human immunodeficiency virus. *J Acquir Immune Defic Syndr*. 1992;5(11):1069-1074.
12. Tun et al. CMV retinitis screening and treatment in a resource-poor setting: three-year experience from a primary care HIV/ AIDS programme in Myanmar. *J Int AIDS Soc*. 2011;14:41. doi: 10.1186/1758-2652-14-41.

13. Pathai S, Deshpande A, Gilbert C, Lawn SD. Prevalence of HIV-associated ophthalmic disease among patients enrolling for antiretroviral treatment in India: a cross-sectional study. *BMC Infect Dis.* 2009;9:158. doi: 10.1186/1471-2334-9-158
14. Lai TY, Wong RL, Luk FO, Chow VW, Chan CK, Lam DS. Ophthalmic manifestations and risk factors for mortality of HIV patients in the post-highly active anti-retroviral therapy era. *Clin Experiment Ophthalmol.* 2011;39(2):99–104.
15. Morjaria R, Sood V, Manavi K, Denniston AK, Palmer H. Lowering the limit: reducing the CD4 T-cell threshold for ophthalmic screening in patients with HIV in an ethnically diverse UK population. *Clinical Ophthalmology.* 2014;8 2029-2034. doi: 10.2147/OPHTH.S67493.
16. Chen C, Guo CG, Meng L, Yu J, Xie LY, Dong HW, Wei WB. Comparative analysis of cytomegalovirus retinitis and microvascular retinopathy in patients with acquired immunodeficiency syndrome. *Int J Ophthalmol.* 2017;10(9):1396-1401.
17. Ford N, Shubber Z, Saranchuk P, Pathai S, Durier N, Daniel P. O'Brien. Burden of HIV-Related Cytomegalovirus Retinitis in Resource-Limited Settings: A Systematic Review. *Clin Infect Dis.* 2013;57(9):1351-1361
18. Jabs DA, Van Natta ML, Holbrook JT, et al. Longitudinal study of the ocular complications of AIDS. 2. Ocular examination results at enrolment. *Ophthalmology.* 2007;114(4):787–793.

How to cite this article: Devi RV, Anthony K, Ranjana M, Victor R. Cytomegalovirus retinitis in post HAART era in the north eastern India. *Ind J Clin Exp Ophthalmol.* 2018;4(3):384-389.