

## Abductor weakness in intertrochantric fractures operated with PFN and its management

Nitin Wale<sup>1</sup>, S. Phuljhele<sup>2</sup>, Atin Kundu<sup>3,\*</sup>, Rajat Banchhor<sup>4</sup>

<sup>1</sup>Assistant Professor, <sup>2</sup>Professor, <sup>3</sup>Associate Professor, <sup>4</sup>Post Graduate Student, Dept. of Orthopaedics, Pt. J.N.M Medical College, Raipur, Chhattisgarh, India

**\*Corresponding Author: Atin Kundu**

Email: atin.bestdoc@gmail.com

### Abstract

**Introduction:** Intertrochanteric hip fractures are common with advancing age. PFN is now increasingly used to fix unstable intertrochanteric fractures however it does not fix greater trochanter. Gluteus medius and gluteus minimus attach to greater trochanter, hence abductor weakness is a likely consequence. In this study we measured the incidence of post operative abductor weakness (trendelenberg gait) and result of targeted physiotherapy on it.

**Materials and Methods:** Between September 2014 and august 2016, 45 patients with unstable intertrochanteric fractures underwent proximal femoral nailing in the Department of Orthopaedics Pt. J. N. M Medical College and Dr. B.R.A.M Hospital, Raipur (C.G.). The patients included in this study were more than 18 years of age with unstable fractures classified according to Modified Evans classification type 3, 4 and 5 with the duration of trauma less than 3 weeks. The functional assessment was made using Mckay criteria through analysis of abductor muscle strength.

**Result:** Immediate Postoperative muscle power was Grade 1 (02 pt.), Grade 2 (27 pt.), and Grade 3 (14 pt.). At 6 months follow up only 02 patients had grade 4 power (due to varus malunion) rest all had muscle power Grade 5. In this study we found that only 2 out of 45 patients (4.4%) had initial abductor power grade 1, grade 2 -64.4% and rest had grade 3 muscle power. Only 2 patient (due to varus malunion) had grade 4 power at 6 months follow-up rest all patients regained power grade 5.

**Conclusion:** Abductor weakness and trendelenberg gait are fairly common in patients treated with PFN and this complaint is often overlooked. Abductor muscle power should be properly assessed post-operatively and physiotherapy for abductor weakness is essential for complete rehabilitation of patients.

**Keywords:** Intertrochanteric fracture femur, Abductor weakness, Proximal femoral nail.

### Introduction

Intertrochanteric hip fractures are common with advancing age group, they generally malunite in varus, leading to shortening and hip abductor weakness. Non-operative care of intertrochanteric fractures are not practiced now a days because of concurrent medical problems and prolonged incumbency that prevented union from occurring. PFN is now increasingly used to fix unstable intertrochanteric fractures however it does not fix greater trochanter. Gluteus medius and the gluteus minimus attach to greater trochanter hence abductor weakness is a likely consequence. Very few literature have reported this complication. In this study we have measured the incidence of post operative abductor weakness (trendelenberg gait) and result of targeted physiotherapy on it.

### Materials and Methods

Between September 2014 and august 2016, 45 patients with unstable intertrochanteric fractures underwent proximal femoral nailing in the Department of Orthopaedics Pt. J. N. M Medical College and Dr. B. R. A. M Hospital, Raipur (C.G.). The patients included in this study were more than 18 years of age with unstable fractures classified according Modified Evans classification type 3, 4 and 5 with the duration of trauma less than three weeks. Femoral fractures with subtrochanteric extent, pathological fractures due to tumor lesions, previous incapacity to walk and

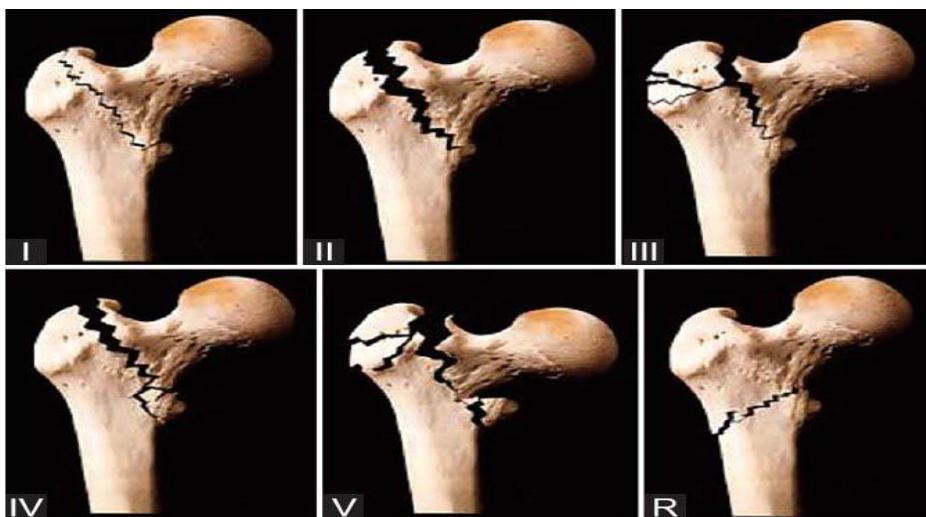
associations with other fractures that would interfere with rehabilitation were excluded in this study.

The functional assessment was made through analysis of abductor muscle strength and specific physiotherapy aimed at restoring abductor power. Abductor muscles were strengthened progressively by resisted exercises by using techniques like repeated contractions, slow reversals and rhythmic stabilizations. Assisted exercises started for patient with marked muscle weakness (power grade 1 and 2). Abductor strength was evaluated at the follow up visit of 6 wk and 3 month and 6 months and finally after 1 year after the surgery.

The modified McKay criteria is useful to assess if a patient has Trendelenburg gait. These criteria measure pain symptoms, gait pattern, Trendelenburg sign status, and the range of hip joint movement.

**Table 1: Modified McKay criteria**

Grade	Criteria
Excellent	Stable, painless hip; no limp; negative Trendelenburg sign; full range of movement
Good	Stable, painless hip; slight limp; slight decrease in range of movement
Fair	Stable, painless hip; limp; positive Trendelenburg sign; and limited range of movement, or a combination of these
Poor	Unstable or painful hip or both; positive Trendelenburg sign



**Fig. 1: Modified evans' classification; Type 1: Two part fracture – undisplaced; Type 2: Two part fracture-displaced; Type 3: Three part fracture without posterolateral support; Type 4: Three part fracture without medial support; Type 5: Four part fracture without posterolateral and medial support; Type R: Reverse oblique fracture**

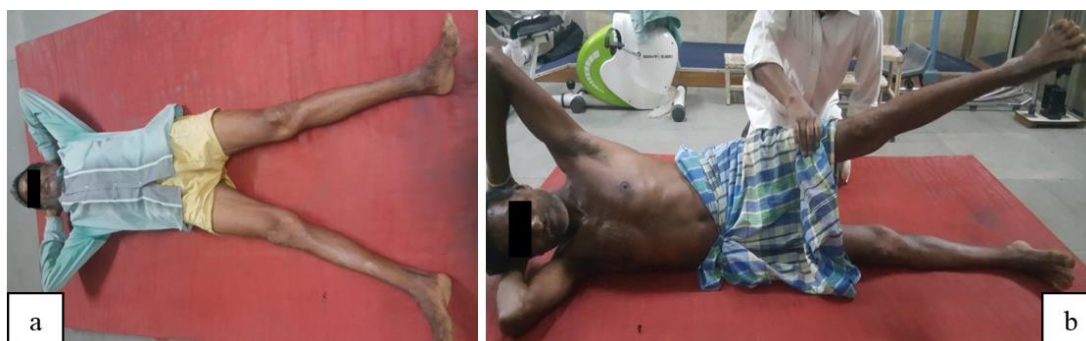**Observations**

Immediate Postoperative muscle power was Grade 1 (02 pt.), Grade 2 (27 pt.), and Grade 3 (14 pt.). Most of the patients improved their muscle power grade at 12

weeks with only 02 patients with Grade 3 and 04 patients with Grade 4 power. At 6months follow up only 02 patients had grade 4 power (due to varus malunion) rest all had muscle power Grade 5.

**Table 2: Abductor strength in immediate post operative period**

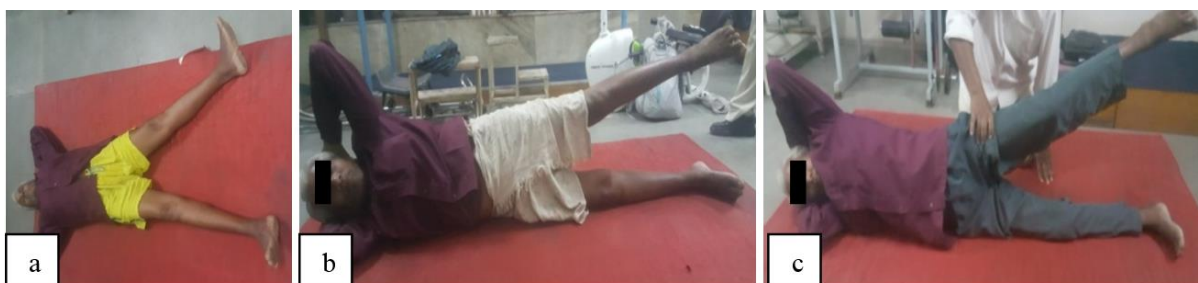Modified Evan's type	Total no. of patients	Abductor muscle strength (Immediate post.op)				
		1	2	3	4	5
3	06	01	04	01	00	00
4	12	00	07	05	00	00
5	27	01	18	08	00	00
<b>Total</b>	45	02	29	14	00	00



**Fig. 2: Abductor muscle power (a): Immediate Post-op grade 2; (b): At 6 months grade 5**

**Table 3: Abductor Muscle strength at various**

Abductor muscle strength (Grade)					
Grade \ Time	1	2	3	4	5
Immediate post. op	02	29	14	00	00
3 weeks	00	04	35	06	00
6 weeks	00	00	08	37	00
12 weeks	00	00	02	04	39
6 months	00	00	00	02	43

**Fig 3: (a): Immediate post op. grade 2' (b): At 6 weeks grade 3; (c): At 6 months Grade****Table 4: Functional assessment at 6 months**

Evans Type	Modified Mckay Criteria (at 6 months)				Total
	Excellent	Good	Fair	Poor	
3	06	00	00	00	06
4	09	02	00	01	12
5	21	05	00	01	27
<b>Total</b>	36	07	00	02	45

In our study modified Mckay criteria showed excellent score in 36 patients (80%), good in 07 (15.56%), and poor in only 2 (4.4%) patients at 6 months.

### Discussion

Intertrochantric fracture femur results in morbidity, hospitalization and mortality in advancing age group. Functionally these patients never returned to prefracture state. Early ambulation is required to avoid medical complications inherent to immobility. Many patients have a significant functional decline and are unable to perform activities of daily living.<sup>6</sup> Some studies cite that even after six months in a proximal femoral fracture, less than half of the individuals recover the physical function that they exhibited before the fracture.<sup>4</sup> Abductor weakness can result from many reasons like varus malunion, excessive collapse both causing shorter abductor arm, entry site (through piriformis fossa which may damage the abductor muscles<sup>7</sup>) and degree of comminution of greater trochanter.

Rudy Reindl et al<sup>10</sup> found that those implants which require extensive reaming of the greater trochanter due to large diameter of the proximal aspect of implant can cause partial detachment of the gluteus medius and may lead to abductor weakness and a Trendelenburg gait.

N. Ivanova et al. found that maximum voluntary isometric force generated in knee and hip muscles for the fractured leg was markedly increased at one week and 6 months postoperatively.<sup>9</sup> In our study we found that two patients (4.4%) had initial abductor power grade 1. 29 patients (64.4%) had grade 2 power and rest had grade 3 muscle power. All patient regained grade 5 power at six months except two patient (grade 4 power) who had varus mal-union.

Some studies claim that laterolateral stability during walking increases with strengthening of abductor and adductor muscles of the hip improving the patient's dynamic balance.<sup>4</sup> Strengthening exercises are the key to the functional improvement of patients<sup>5</sup> along with gait or ADL training or proprioception and others like motor stimulation apparatuses and analgesia. Limitations of mobility are quite common and are partially related to the lack of strength and muscle power. The goal of physical therapy in postoperative treatment of patients with a proximal femoral fracture should be to increase muscle strength, and to improve ambulation and efficiency, thus enabling the elderly patient to become independent. In addition, home based rehabilitation is commonly resorted to in these patients, in view of the difficulty of accessibility, such as lack of transportation, inability to leave their home or fear of doing so.

Most of the available implants like DHS and PFN do not fix greater trochanter (apparently they also don't fix lesser trochanter). Some implants like Trochantric Stabilization plate (TSP) and Tension Band Wiring of greater trochanter are used to fix greater trochanter but many times it is so comminuted that these devices seldom help. Post operative abductor weakness is often overlooked. Patient very often describe a lurch (or limp) in their gait, which is often overlooked by the surgeon, or the lurch is so mild that it may go unnoticed and becomes apparent only on close observation.

In immediate post operative period modified Mckays criteria is useful to assess the abductor weakness and should be routinely used. The physiotherapy must be individualized as some individuals may not tolerate certain exercises hence there can be variations in time to regain full abductor strength. On post operative day one free and resisted exercises are started in all patients except in those having muscle power grade 1 and 2 who require assisted exercises in initial phase and then gradually changed to free and resisted exercises. Assisted exercises include assisted leg -parting in prone and supine position with the other leg fully abducted to fix the pelvis and limit the movement of that hip joint. Free exercises included half standing-leg shortening and lengthening and free leg-parting, half standing-sideways leg lifting. Resisted exercises include weight resistance with half standing or side lying.<sup>8</sup>

### Conclusion

Abductor weakness and trendelenberg gait are fairly common in patients treated with PFN and this complaint is often overlooked. Abductor muscle power should be properly assessed post-operatively and physiotherapy for abductor weakness is essential for complete rehabilitation of patients.

### References

1. Stanley Hoppenfeld, Vasantha L. Murthy. Treatment and Rehabilitation of Fractures, chapter 22 intertrochantric fractures, 2000, p. 283.
2. Rohit Jhamnani, Ronald JM, Harsharaj K. Functional Outcome of Comminuted Intertrochanteric Fracture of Femur Internally Fixed Using Proximal Femoral Nail. *International Journal of Healthcare Sciences*. 2015;3(1):417-425. ISSN 2348-5728
3. Je-Hyun Yoo, Tae-Young Kim, Jun-Dong Chang, Yoon-Hae Kwak, Yong-Shin Kwon. Factors Influencing Functional Outcomes in United Intertrochanteric Hip Fractures: A Negative Effect of Lag Screw Sliding. *Orthopedics*. 2014;37(12):e1101-e1107.
4. Portegijs E, Kallinen M, Rantanen T, Heinonen A, Sihvonen S, Alen M, et al. Effects of resistance training on lower-extremity impairments in older people with hip fracture. *Arch Phys Med Rehabil*. 2008;89(9):1667-1674.
5. Mariana Barquet Carneiro, Débora Pinheiro Lédio Alves, and Marcelo Tomanik Mercadante. Physical therapy in the postoperative of proximal femur fracture in elderly. Literature review. *Acta Ortop Bras*. 2013;21(3):175-178. doi: 10.1590/S1413-78522013000300010
6. Bentler SE. The aftermath of hip fracture. *Amer J Epidemiol*. 2009;170:1290-9.
7. C.M. Ansari Moein, M.H.J. Verhofstad, R.L.A.W. Bleys, Chr. van der Werken. Elsevier; Soft tissue injury related to choice of entry point in antegrade femoral nailing: piriform fossa or greater trochanter tip. *Injury, Int J Care Injured*. 2005;36:1337-1342.
8. The principles of exercise therapy; 4th edition, M. Dena Gardiner; Part four- Muscle strength pg.181, Technique of strengthening muscles pg.201.
9. N. Ivanova, H. Aibast, H. Gapeyeva, T. Kums, A. Märtson, M. Pääsuke. Changes in hip muscle strength after proximal femoral fracture in elderly women. *Acta Kinesiologiae Universitatis Tartuensis*. 2011;17:80-88.
10. Rudy Reindl. Extramedullary vs. Intramedullary Devices in the Treatment of Unstable Intertrochanteric Hip Fractures. *Orthopaedic Trauma Association*, McGill University Health Center.
11. Jensen JS. Classification of trochanteric fractures. *Acta Orthop Scand*. 1980;51:803-810.

**How to cite this article:** Wale N, Phuljhele S, Kundu A, Banchhor R. Abductor weakness in intertrochantric fractures operated with PFN and its management. *Indian J Orthop Surg*. 2018;4(3):230-233.