

## Multiple impacted teeth in a non syndromic patient: A case report and discussion

Abhishek Singh<sup>1</sup>, Vikash Jha<sup>2</sup>, Neha Jha<sup>3</sup>, Poonam Majumder Singh<sup>4,\*</sup>

<sup>1</sup>Dental Surgeon, <sup>2</sup>Junior Staff Surgeon, <sup>1,2</sup>Dept. of Dental Surgery, <sup>1</sup>S.N.M. District Hospital & T.B. Sanatorium, Firozabad, Uttar Pradesh, <sup>2</sup>Dr. Ram Manohar Lohia hospital, New Delhi, <sup>3</sup>Private Practitioner, New Delhi, <sup>4</sup>Consultant Orthodontist, Private Practitioner, Agra, Uttar Pradesh, India

**\*Corresponding Author:**

Email: majumderpoonam87@gmail.com

### Abstract

It is commonly observed that multiple impacted permanent teeth are usually linked to syndromes, hormonal and metabolic disorders. Nevertheless some cases of impaction of multiple teeth are non syndromic. In the present case report, we confer about a 22-year-old female non syndromic patient with missing teeth. Radiological investigation from OPG revealed multiple impacted permanent teeth, though medical and family history along with physical examination was not suggestive of any syndromes.

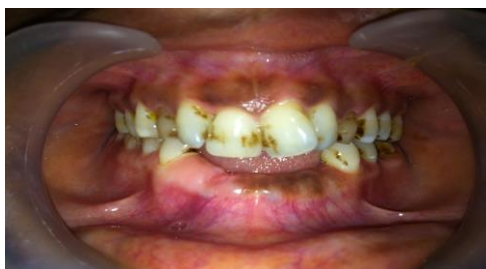**Keywords:** Multiple impaction, Non syndromic patient.

### Introduction

Impacted tooth by definition is “a tooth that cannot, or will not, erupt into its normal functioning positions, past the completion of its root formation. The associated etiology of multiple impacted teeth may be syndromes and metabolic disorders like cleidocranial dysplasia, Down syndrome, Gardner syndrome, Yunis–Varon syndrome, Endocrine deficiencies (hypothyroidism and hypopituitarism), febrile diseases, etc. In some cases, however, impaction of multiple teeth is not due to any syndrome. This case report is about a patient having multiple impacted teeth without any systemic disorder.

### Case Report

A 22-year-old female patient presented with a chief complaint of multiple missing teeth in lower anterior region and compromised esthetics. Intraoral examination revealed that her lower incisors and canines and lower left first molar were missing along with bilateral retained upper deciduous canine and missing upper permanent canines. The patient was of mesomorphic built with a current history of extraction of her over retained lower deciduous anterior teeth.

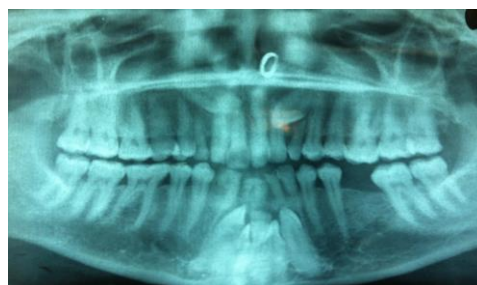

**Fig. 1: Clinical intraoral photograph**

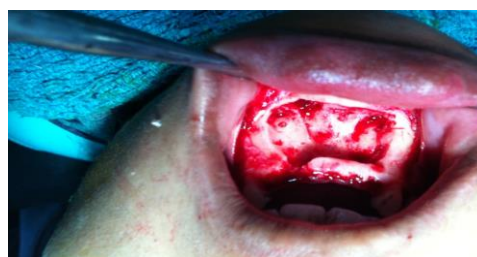
Radiograph revealed over- retained lower deciduous anterior (which were extracted outside our centre) along with over- retained bilateral upper deciduous canine. All her lower anterior teeth were

impacted along with bilateral upper permanent impacted canine; her lower left permanent first molar was also missing which she got extracted many years back due to caries.

Medical, family history and extra oral examination were not suggestive of any syndrome or metabolic disorder. After consultation with the orthodontist a joint decision was made to extract the impacted teeth followed by prosthesis.



**Fig. 2: Radiograph showing multiple impacted teeth**



**Fig. 3: Photograph after extraction of lower impacted teeth**

### Discussion

Although 25% to 50% of the population are affected by dental impactions,<sup>4</sup> multiple impactions are seen rarely and are usually associated with systemic conditions like Cleidocranial dysostosis, *Gorlin-Sedano syndrome*, Gardner's syndrome, and Yunis-Varon Syndrome. Therefore the clinician should be alert and

look for other features of the syndromes and metabolic disorders that may be present on encountering multiple impacted teeth other than third molars or canines.<sup>2</sup>

In the case of metabolic disorders of hormones hypothyroidism, hypoparathyroidism, and Pseudo hypoparathyroidism are to be considered.

Diagnosis of hypothyroidism is done by estimation of T3, T4, and TSH level, which is confirmed by low serum T4 and elevated TSH. Hypoparathyroidism and pseudo hypoparathyroidism is diagnosed by evaluating total serum calcium concentration and serum parathyroid hormone. There is decrease of serum calcium in both and elevation of parathyroid hormone in pseudo hypoparathyroidism and decrease of the hormone in hypoparathyroidism.<sup>6</sup>

However, impaction of multiple teeth may not be accompanied by any systemic conditions. Lack of basal arch perimeter in the dental arches leading to crowding, over retained deciduous teeth with subsequent partial closure of the area by mesiodistal tipping of the adjacent teeth, the premature loss of the primary teeth, and rotation of tooth buds are some of the most common etiologic factors contributing to impaction. The failure to erupt may also result from obstruction or crowding caused by supernumerary teeth. Primary failure of eruption, an uncommon condition, may also be an etiologic factor. In the present case, we believe that over retained deciduous teeth and rotation of tooth buds resulted in multiple impactions in permanent dentition.

Multidisciplinary approach, keeping into concern the principles of esthetics, function and stability, would be the appropriate choice in treating the cases of multiple impacted teeth. Orthodontic extrusions and alignment may be attempted in case of unerupted teeth. Taking into consideration the pathological potential of the impacted teeth which include formation of cysts or root resorption of adjacent erupted teeth, surgical removal is recommended. Rehabilitation of the patient with fixed dentures should be considered and planned with the help of a prosthodontist and implantologist. Restoration of the oral function and esthetics with a strong component of stability in the treatment results should be the main goal in treating these cases.

## Conclusion

Although multiple impacted teeth are mostly associated with hormonal and syndromic condition but it can also be seen in normal individuals hence thorough medical and systemic examination should be done to rule out any such condition and multidisciplinary approach should be taken to treat such patients.

**Funding:** No funding sources.

**Conflict of interest:** None declared.

## References

1. Alling CC, Catone GA. Management of impacted teeth. *J Oral Maxillofac Surg* 1993;51(suppl 1):3–6.
2. D Yildirim, HH Yilmaz and U Aydin. Multiple impacted permanent and deciduous teeth. *Dento Maxillofacial Radiol* (2004) 33, 133–135.
3. Babu V, Nagesh KS, Diwakar NR. A rare case of hereditary multiple impacted normal and supernumerary teeth. *J Clin Pediatr Dent* 1998;23:59–62.
4. Andreason JO, Pindborg JJ, Hjorting-Hansen E, Axell T. Oralhealth care: More than caries and periodontal disease. A survey of epidemiological studies on oral disease. *Int Dent J* 1986;36:207–14.
5. Sharma A. A rare non-syndromic case of concomitant multiple supernumerary teeth and partial anodontia. *J Clin Pediatr Dent* 2001;25:167–69.
6. Sujatha G, Sivapathasundharam B, Sivakumar G, Nalinkumar S, Ramasamy M, Prasad TS Idiopathic multiple impacted unerupted teeth: Case report and discussion. *J Oral Maxillofac Pathol* 2012;16(1):125–27
7. Mercuri LG, O'Neil R. Multiple impacted and supernumerary teeth in sisters. *Oral Surg Oral Med Oral Pathol* 1980;50:293.
8. Leslie JC. Multiple supernumerary teeth. *Oral Surg Oral Med Oral Pathol* 1984;57:463.
9. Tanaka E, Kawazoe A, Nakamura S, Ito G, Hirose N, Tanne Y, et al. An adolescent patient with multiple impacted teeth. *Angle Orthod* 2008;78:1110–18.
10. Zeynep ZA, Pinar SA, Emine K. Impacted primary tooth and tooth agenesis: A case report of monozygotic twins. *Eur J Dent* 2008;2:299–302.

**How to cite the article:** Singh A., Jha V., Jha N., Singh P. Multiple impacted teeth in a non syndromic patient: A case report and discussion. *Int Dent J Student's Res* 2018;6(3):66-67.