

Vulvar pyogenic granuloma: A rare location

Shivani Ranjan^{1,*}, Bharti Devi Thakur²

¹Senior Resident, ²Lecturer, ¹Dept. of Dermatology, Venereology and Leprosy, Acharaya Shri Chander College of Medical Sciences and Hospital, Jammu, Jammu & Kashmir, ²Dept. of Pathology, Government Medical College, Jammu, Jammu & Kashmir, India

***Corresponding Author:**

Email: drshivaniranjana@rocketmail.com

Abstract

Pyogenic granuloma is an acquired vascular tumor. It most commonly presents on head, neck, trunk, distal extremities and face. It is relatively rare on female genitalia. We report two cases of solitary vulvar pyogenic granuloma. **Case 1:** A 23 years old female presented with single lesion on her left labia majora since 20 days. **Case 2:** A 48-year-old woman also presented with a single lesion on her left labia majora since 3 months. Excisional biopsies were done in both the cases which showed features suggestive of pyogenic granuloma. On follow-up, no recurrences were found. Our emphasis is to make dermatologists aware of the rare location of pyogenic granuloma on vulva.

Keywords: Pyogenic granuloma, Vascular tumor, Vulva.

Introduction

Pyogenic granuloma (also known as lobular capillary hemangioma) is one of the most common vascular tumors of all ages usually that follows a minor injury. It mostly presents on head, neck, trunk, distal extremities (especially fingers), feet, face (especially lips, gingival and tongue). It can also arise during pregnancy, particularly on the gingiva and hence, known as epulis of pregnancy. It commonly presents as single, erythematous, sessile or pedunculated, polypoid growth with a smooth or lobulated surface, often with a subtle epithelial collarette at the base, and it bleeds spontaneously or following minor trauma.¹ It is mostly painless, or it can be slightly painful. Pyogenic granuloma presenting on vulva is a rare location and only few case reports are available in the literature. We here report two cases of solitary vulvar pyogenic granuloma.

Case 1

A 23 years old unmarried female presented with solitary cherry red pedunculated lesion on lower aspect of left labia majora (Fig. 1), with 20 days history of pain and bleeding on and off from the lesion. The patient did not recall any history of trauma and also she denied any sexual contact. Excisional biopsy was done which revealed ulcerated surface and a chronic inflammatory infiltrate with multiple endothelial lined vascular spaces arranged in lobules in the dermis (Fig. 2a and 2b).

Case 2

A 48-year-old woman presented with a single, erythematous, pedunculated lesion with lobulated surface on the left labia majora (Fig. 3) since 3 months. According to the patient, it bled occasionally. Patient also had history of itching groins and submammary areas since 6 months which was diagnosed as

dermatophyte infection. There was no history of any trauma prior to the appearance of lesion. VDRL and HIV serology were negative. Excisional biopsy was done which revealed that the epidermis was ulcerated and dermis showed small capillary sized blood vessels with congestion and haemorrhage. She was also given treatment for dermatophyte infection.

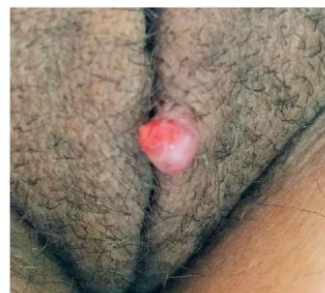

Fig. 1: Pyogenic Granuloma on lower aspect of left labia majora in a 23 years old female

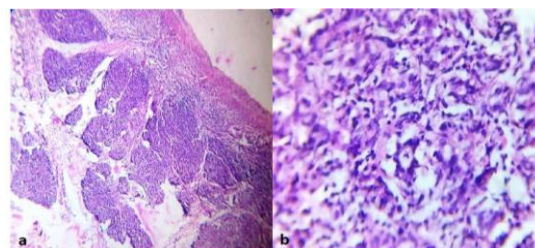


Fig. 2a and 2b: Low power view and high power view showing ulcerated surface and a chronic inflammatory infiltrate with multiple endothelial lined vascular spaces arranged in lobules in the dermis

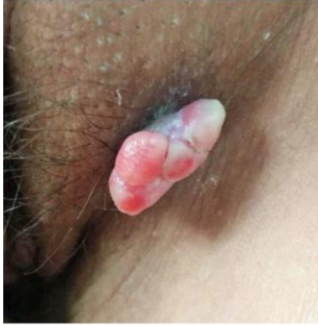

Fig. 3: Pyogenic granuloma on the left labia majora in a years old woman

Discussion

Pyogenic granuloma (PG) is a common benign skin growth. PG of the glans penis has been reported in the literature²⁻⁵ but it is rarely been reported on the female genitalia. The name “pyogenic granuloma” is a misnomer since it is neither infectious nor granulomatous.⁶

The exact cause for the development of PG is unknown. Rather than a true hemangioma, it is believed to be a reactive hyperproliferative vascular response to various stimuli.⁷ In most of the studies, trauma is considered as a primary cause, but the study by Patrice et al found that most (74.2%) of cases had no history of prior trauma or underlying dermatologic condition.⁸ Common associations of PG are portwine stain, psoriasis, eczema, burns, erythroderma, insect bite, viral infections, systemic drugs like retinoids and protease inhibitors.^{7,8} It is considered that trauma or underlying skin disease leads to excessive local production of tumour angiogenesis factor which might play a role in the pathogenesis of PG.^{7,8}

PGs are benign but there is always a fear of malignancy. So a skin biopsy should always be considered. Treatment options include surgical excision, cryotherapy, sclerotherapy, curettage followed by electrocauterization of the base, lasers, 5% imiquimod cream, beta-adrenergic receptor antagonists-timolol or propranolol.^{9,10} Among lasers, diode lasers, Nd:YAG lasers, erbium-YAG and CO₂ lasers have all been used successfully.¹⁰ Patrice et al has reported lower recurrence rates with shave excision and cautery in comparison to cautery alone.⁸ Full-thickness skin excision and primary closure is most widely accepted.⁸ PGs in pregnancy should be dealt conservatively as most of them may resolve spontaneously after delivery.

Conclusion

Unacquaintance with the rare location of pyogenic granuloma on vulva can cause confusion with other common differentials like warts, condyloma lata, condyloma acuminata and verrucous carcinoma. Since it is a benign tumor which can be easily treated with surgery with low recurrence rates, so we call attention of dermatologists to recognize pyogenic granuloma on the rare location on vulva.

Funding: No funding sources.

Conflict of interest: None declared.

References

1. Arikian D. C., Kiran G., Sayar H., Kostu B., Coskun A., Kiran H. Vulvar pyogenic granuloma in a postmenopausal woman: case report and review of the literature. *Med* 2011;3
2. Maeda Y, Izutani T, Yonese J, Ishikawa Y, Fukui I. Pyogenic granuloma of the glans penis. *Br J Urol* 1998;82:771-72.
3. Summers JL. Pyogenic granuloma: an unusual complication of papaverine injection therapy for impotence. *J Urol* 1990;143:1227-28.
4. Tomasini C, Puiatti P, Bernengo MG. Multiple pyogenic granuloma of the penis. *Sex Transm Inf* 1998;74:221-22.
5. Walzman M, Kundu A, Fraser I. Pyogenic granuloma of the penis: a rare entity? *Genitourin Med* 1995;71:43-4.
6. Chong KM, Yeh TC, Hwang JL. Vulvar Lobular Capillary Hemangioma (Pyogenic Granuloma). *Taiwanese J Obstet Gynecol* 2005;44(1):94-95.
7. Gupta S, Radotra BD, Kumar B. Multiple, genital lobular capillary haemangioma (pyogenic granuloma) in a young woman: a diagnostic puzzle. *Sex Transm Inf* 2000;76:51-52
8. Patrice SJ, Wiss K, Mulliken JB. Pyogenic granuloma (lobular capillary hemangioma): a clinicopathologic study of 178 cases. *Pediatr Dermatol* 1991;8:267-76.
9. Santos FA, Câmara S, Reis F, Freitas T, Gaspar H, Cordeiro M. Vulvar Lobular Capillary Hemangioma: A Rare Location for a Frequent Entity. *Case Rep Obstet Gynecol* 2016
10. Wollina U, Langner D, França K, Gianfaldoni S, Lotti T, Tchernev G. Pyogenic Granuloma – A Common Benign Vascular Tumor with Variable Clinical Presentation: New Findings and Treatment Options. *Open Access Maced J Med Sci* 2017;5(4):423-26.

How to cite this article: Ranjan S., Thakur B. Vulvar pyogenic granuloma: A rare location. *Indian J Clin Exp Dermatol* 2018;4(4):346-47.