

## Intramedullary lipoma without spinal dysraphism in an adult: A case report & review of literature

Rajesh Shenoy<sup>1</sup>, Ravi Ichalakaranji<sup>2,\*</sup>

<sup>1</sup>Professor, <sup>2</sup>Resident, Jawaharlal Nehru Medical College, Belgaum, Karnataka, India

**\*Corresponding Author:**

Email: ravi.ichalakaranji@gmail.com

### Abstract

Spinal cord lipomas are rare benign tumours<sup>1,7,10,15</sup> and mainly of 2 types. Those usually associated with the syndrome of spinal dysraphism,<sup>16,22</sup> where these lesions communicate with subcutaneous lipomas through a defect in the posterior elements of the spine (such as spina bifida, lipomyelomeningocele, myelomeningocele, diastematomyelia, cutaneous lipoma, fistula, pilosity & Klippel-Feil malformation) and those without spinal dysraphism.<sup>7</sup>

Spinal cord lipomas which are not associated with spinal dysraphism are even less frequent, accounting for 1% of spinal cord tumours.<sup>1,15,23</sup> 60% are localized intradurally & 40%, extradurally.<sup>5,9</sup>

Here we present a case of a 22 years male patient came to our hospital with h/o upper back pain, non-radiating type, localized to thoracic spine and his examination showed normal gait with mild spasticity in left lower limb, with no sensory or motor deficits. Romberg's sign was mildly positive. Bilaterally reflexes were equal and normal, with left Babinski sign present.

MRI whole spine with plain and contrast showed T1 and T2 hyperintense lesion in dorsal spine extending from D4-D9 intradural intramedullary lesion suggestive of lipoma with no evidence of spinal dysraphism.

Patient was subjected for surgical excision and postoperatively patient recovered well with symptom free intervals.

**Keywords:** Intramedullary lipomas, Spinal cord lipomas, Spinal dysraphism, M.R.I spine.

### Introduction

Spinal cord lipomas are rare benign tumours<sup>1,7,10,15</sup> and mainly of 2 types. Those usually associated with the syndrome of spinal dysraphism,<sup>16,22</sup> where these lesions communicate with subcutaneous lipomas through a defect in the posterior elements of the spine (such as spina bifida, lipomyelomeningocele, myelomeningocele, diastematomyelia, cutaneous lipoma, fistula, pilosity & Klippel-Feil malformation) and those without spinal dysraphism.<sup>7</sup>

Spinal cord lipomas which are not associated with spinal dysraphism are even less frequent, accounting for 1% of spinal cord tumours.<sup>1,15,23</sup> 60% are localized intradurally & 40%, extradurally.<sup>5,9</sup>

Intramedullary lipomas are even more rare, accounting for 0.45-0.6% of all spinal cord tumours.<sup>8</sup> Commonest location of these tumors are in cervico-thoracic region usually present in 20-40 yrs of age.<sup>2</sup> The exact etiology of spinal cord intramedullary lipomas is unknown.

M.R.I. is the gold standard for the evaluation of these spinal cord lipomas.<sup>1</sup>

There is no agreement on the indications for surgery in these cases,<sup>14,24</sup> especially those well preserved neurologically and/or with minimal symptoms, and the management remains a challenge.<sup>6</sup> Despite their benign nature, lipomas are usually not amenable to complete resection<sup>11</sup> as complete adhesion to the spinal cord limits extent of resection.<sup>21</sup> Attempts at radical resection carry a significant risk of morbidity, as there is usually NO cleavage plane between the lipoma and the spinal cord.<sup>14,24</sup> Therefore, the main goal of surgery, is not total removal of the lesion,<sup>5</sup> but

subtotal resection of the tumour & decompression of the adjacent neural structures.<sup>5,14</sup> It stabilizes the disease process in the long run.

Large spinal cord intramedullary lipomas (>5cms in length) are not common and only few have been reported in the literature.

In our case it measured 11.5cms in length over 6 vertebral levels.

As soon as early clinical or radiological evidence of recurrence is seen, such patient to be operated early to prevent fixed Neurological deficits.

### Case Report

#### Patient history

A 22 years male patient presented to our hospital with h/o upper back pain, non-radiating type, localized to thoracic spine with no h/o trauma, no h/o weakness in limbs, with no h/o bowel/bladder involvement. He had tingling sensations in right great toe.

**Examination:** General examination showed no cutaneous stigmata such as hair, dimples or masses.

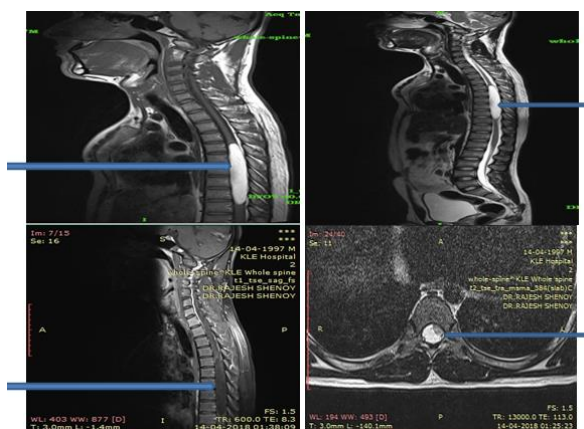
Neurological examination showed patient had normal gait with mild spasticity in left lower limb, with no sensory or motor deficits. Romberg's sign was mildly positive. Bilaterally reflexes were equal and normal, with left Babinski sign present.

**Laboratory examinations:** Complete blood count and blood chemistry results were all within normal limits.

**Radiological findings:** Plain X-rays showed no evidence of any congenital anomalies or any features suggestive of tumours.

MRI whole spine with plain and contrast (Fig. 1): showed T1 and T2 hyperintense lesion in dorsal spine extending from D4-D9 intradural intramedullary measuring 11.5cms with thickness of 1.5cms showing

loss of signal intensities on fat suppression images suggestive of fat content with no evidence of enhancement on contrast study, features suggestive of lipoma.



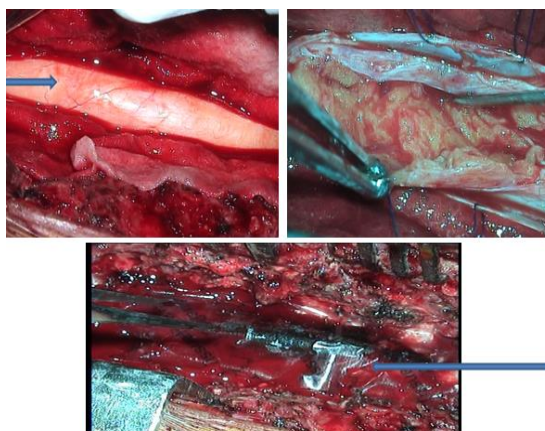
**Fig. 1: MRI spine shows T1 & T2 hyperintense intradural intramedullary lesion with contrast non enhancing suggestive of Lipoma**

CT spine was done which showed no evidence of spinal dysraphism without any erosion of laminae/pedicles or expansion of the spinal canal.

### Surgical management

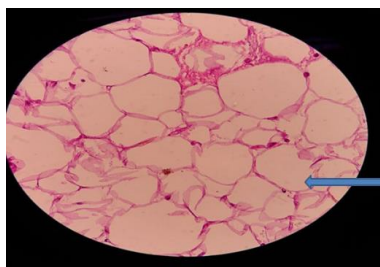
Midline vertical incision was taken, exposing D4-D9 lamina, followed by laminectomy and flavectomy. Dura looked tensed and pale in colour. Durotomy was done in the midline vertically. On opening the dura, arachnoid was stretched and pale white. Arachnoid mater was opened with an arachnoid knife. Cord was expanded and pale yellowish in colour. Myelotomy was done over the thinnest overlying neural tissue. Soft to firm yellowish tumour which was vascular&

interspersed between the nerve fibres noted compressing the cord anterolaterally to the left. Gentle decompression was done. Tumour –cord margin was not distinguishable as neuromonitoring during surgery was not available at our institute, other intraoperative signs like decrease/ lack of cord pulsation was looked during surgery. Tumor dissection was stopped on seeing white matter substance on all the sides and collapse of the completely into the canal. There was always free flow of CSF until the end of the surgery. Subtotal excision could be achieved without injuring nerve fibres and with strict hemostasis. Duroplasty done with help of an artificial dural substitute (dural tissue patch). Wound was closed in layers.



**Fig. 2: Intraoperative images showing intramedullary lipoma with excision and repair with tissue dura patch**

**Histopathology Report:** Showed fragments of mature adipose tissue lobules with a few nerve funicles and thick walled blood vessels.

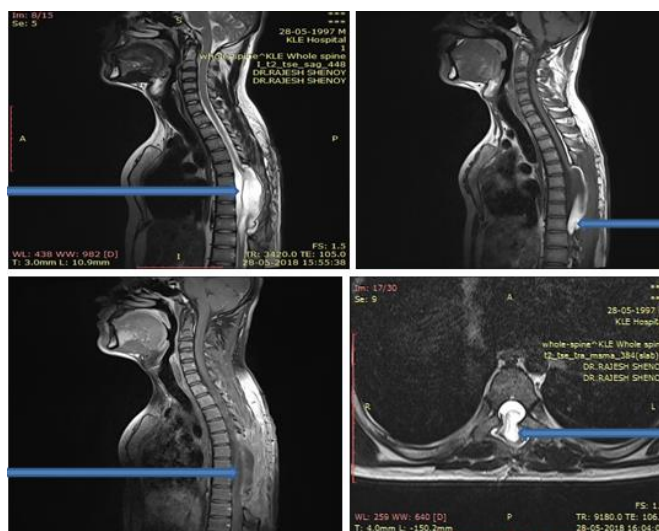


**Fig. 3: HPR slide showing mature adipose cells suggestive of lipoma**

**Postoperative course:** No immediate postop complications were seen.

Postoperatively patient recovered well with no deficits.

**Follow up (after 6 weeks):** Patient was pain free, with no spasticity, normal reflexes and a mute Babinski. Rhombergs sign remained positive.



**Fig. 4: Follow up MRI spine plain and contrast shows dilatation of spinal canal with CSF filled outpouching and residual lipoma on lateral aspect**

## Discussion

Most lipomas of the spinal cord are usually associated with spinal dysraphism and are usually found in the lumbosacral region.<sup>2</sup> Spinal cord intramedullary lesions without spinal dysraphism, are rare.<sup>1</sup> Both the males and females are affected equally.<sup>1,2</sup> They may involve the entire length of the cord, but most commonly seen in the cervico dorsal or the dorsal region,<sup>1,2</sup> and present in the second or third decade of life.<sup>1,2</sup> Classically these tumors are intradural either extramedullary or intramedullary or the combination of two.<sup>11</sup> It is usually posteriorly located in the cord around the midline. They may surface (subpial) and distort and expand the spinal cord (juxtamedullary). Most involve several spinal cord segments. True intramedullary lipoma is very rare.<sup>4</sup>

Histologically, they consist of mature fat cells, separated by delicate connective tissue with intervening collagen fibres, interposed in the neural tissue.<sup>1,2,8</sup> Other mesenchymal derivatives like striated muscle, neural and epithelial tissue may also be found.<sup>1,2</sup> These other types of tissue do not contain neoplastic cells with potential for growth. Lipomatous fat is metabolically

similar to adipose tissue in the rest of the body.<sup>14</sup> Admixed nerve bundles are often located at the periphery, suggestive of secondary entrapment of adjacent nerve roots.<sup>1</sup>

Intradural spinal lipomas are perhaps best considered as congenital inclusion tumours of the central nervous system.<sup>12</sup> Many theories have been proposed to explain the intramedullary location of these lesions.<sup>1,2</sup> "Developmental error theory" is the most accepted, and postulates that mesenchymal cells that are precursor to adipocytes become misplaced during embryologic neural tube development and migrate into the developing neural tube before closure and develop into lipoma later.<sup>1,2</sup> This explains the cause for the lipoma being dorsally in the cord and those not associated with spinal dysraphism.<sup>1,2</sup> According to the "Metaplasia theory" connective tissue metaplasia contribute to fat deposition within the dura. The "Hamartomatous origin theory" where the ectodermal or mesodermal remnants like peripheral nerve, skeletal muscle, dermoid cyst, renal or lymphoid tissue may be found.<sup>1</sup> Another hypothesis says that adipocytes may be derived from mesenchymal cells which give rise to

spinal vessels and these cells are prevented from forming adipocytes by neural crest cells. However, if neural crest cells are abnormal or defective, the inhibition fails and mesenchymal cells form adipocytes.<sup>1,2</sup>

Fleming et al proposed that lipomas which occurs in non dysraphic individuals represent true neoplasms, because due to hyperplasia there is a progressive increase in tumor size, which was seen where recurrence occurred.<sup>3</sup>

Lipomas of the spinal cord exert mass effect causing neurological deficit similar to the other spinal cord tumor.<sup>3</sup> The clinical presentation & examination findings reflect the location and size of the spinal cord lipoma.<sup>17</sup> Patients presents symptoms months before establishing the diagnostic findings and signs on clinical examination localise the lesion at the end.<sup>13</sup>

Gradual increase in limb weakness, hypotonia gait disturbance and loss of proprioception may be the presenting symptoms. Also signs of dorsal column disturbances, ataxia, pain and urinary incontinence may be present.<sup>1,10,14,19</sup>

M.R.I. is considered the gold standard for the identification and the differential diagnosis of lipomas. Due to short T1 relaxation time of fat and its long T2 relaxation time Lipomas show high signal intensity on T1 and T2 weighted images.<sup>18</sup> Fat suppression images will confirm the presence of fat, and post contrast images show no enhancement of the lesion.

Treatment depends on symptoms, and is tailored accordingly. Most of these patients exhibit symptoms years before they are actually diagnosed.<sup>3,5</sup> patients with incidental findings or with no symptoms and without neurologic signs and symptoms can be managed conservatively with periodic follow up to monitor clinical and radiological progress.<sup>1,2,5</sup> When deciding whether prophylactic surgery is necessary for asymptomatic patients, the risk of surgery and the possible post-operative outcome with respect to pre-operative deficits should be reevaluated.<sup>14</sup> In symptomatic patients, surgical planning should be early decompression before symptom progression. Early decompression, with subtotal removal of tumor, with careful attention to the spinal cord elements,<sup>17</sup> with dural patch grafting to enlarge the space for slow growing residual tumour is a prudent and safe approach.<sup>1,6</sup> Early surgical decompression can prevent irreversible spinal cord dysfunction, although most symptomatic patients do not improve significantly after surgery.<sup>1</sup> These lesions are benign, however complete surgical removal is not possible due to their vast attachment to the surrounding neural tissues.<sup>1</sup>

Inpatients presenting with neurological deficits, spinal cord decompression with sub total resection may be the best option.

There have been no reports of radiation therapy or chemotherapy used as adjuvants in the treatment of

spinal cord lipomas, nor any reports of malignant transformation.<sup>17</sup>

In our case, due to the infiltrative nature of the lesion and extensive adhesions of the lipoma, complete removal was not possible. Intraspinal lipomas, being congenital lesions, not only compress but would actually replace normal tissue, during development resulting in less redundancy in the functional pathways.<sup>2</sup> Hence, there is a greater chance of permanent injury to the residual normal tissue post-operatively.<sup>2</sup> Therefore, early surgical decompression is recommended before irreversible spinal cord dysfunction sets in, following which, surgical results are suboptimal.<sup>2</sup> Impaired neurological functions due to parenchymal damage occurs due to aggressive surgical removal of lipomas, recent surgical and technical advances, like intra-op ultra-sound, operating microscope, the ultrasonic aspirator, surgical laser etc. have significantly improved surgical management.<sup>1</sup>

The extent of the lesion and the extent of neurological dysfunction dictates the outcome and prognosis.<sup>1,20</sup> Early diagnosis and treatment provides a better outcome.

Patients presenting with severe neurological symptoms have a very poor prognosis with no improvement after surgical resection.

When early clinical signs of recurrence develop, with radiological evidence, early re-operation should be done to prevent from developing a fixed neurological deficit.

Since these lipomas are very slow growing tumors, the greatest drawback of MR imaging is its ineffectiveness post-operatively due to difficulty in differentiating recurrence from residual tumour, which is always present in cases of intramedullary lipomas, since total resection of these tumors is not feasible.<sup>3</sup> Characteristically, the area in which the lipomas have been resected demonstrates a diffuse area of abnormality when the tissue planes are disrupted and the resulting scar tissue melds homogenously with the residual fibrofatty tissue of the lipomas.<sup>3</sup>

## Conclusion

Intramedullary spinal cord lipomas without spinal dysraphism are very rare, and usually have an indolent course. M.R.I. is diagnostic and have got typical signal characteristics of fat. Clinically, they cause symptoms and neurological deficits due to mass effect and secondary compressive myelopathy. These benign lesions have extensive surrounding neural tissue attachments making complete surgical removal impossible. Pre-operative neurological status is determines the long term outcome after surgery. Early surgical intervention with preserved neurological status results in a better outcome.

Large or giant intramedullary spinal cord lipomas like ours (>11.5cms) are uncommon. Since our patient was asymptomatic without any fresh neurological

complaints and scan didn't show conclusive evidence of any recurrence regular follow up is being done for the same.

## References

- Solomou A, Panagiotopoulos V, Kraniotis P et al. Massive bilocular spinal cord intramedullary lipoma of the thoracic spine. *BJR Case Rep* 2017;3:20170009.
- Sujeet Kumar Meher, Laxmi Narayan Tripathy, Harsh Jain et al. Nondysraphic cervicomedullary intramedullary lipoma. *J Craniovertebr Junction Spine* 2017;8(3).
- Uddanapalli Sreeramulu Srinivasan, Natarajan Raghunathan, Lawrence Radhi. Long Term Outcome of Non-Dysraphic Intramedullary Spinal Cord Lipomas in Adults: Case Series and Review. *Asian Spine J* 2014;8(4):476-83.
- Kabir SM, Thompson D, Rezajooi K et al. Nondysraphic intradural spinal cord lipoma: case series, literature review and guidelines for management. *Actaneurochirurgica* 2010;152(7):1139-44.
- Kabir SM, Thompson D, Rezajooi K, Casey AT. Nondysraphic intradural spinal cord lipoma: case series, literature review and guidelines for management. *Actaneurochirurgica* 2010;152(7):1139-44.
- Viveksharma, Divyeparakshitiwari, Janak raj. Subpial spinal lipoma without dysraphism world journal of surgical medical and radiation oncology volume no 7.
- Wan-Soo So, M.D. Woo-Jong Lee, M.D. Ha-Young Choi, M.D. Jong-Pil Eun, M.D. Spinal Intramedullary Lipoma without Dysraphism. *J Korean Neurosurg Soc* 2007;42:42-5.
- Asdrubal Falavigna 1, Ana Claudia Segatto, Karinesalgado. A rare case of intramedullary lipoma associated with cyst. *Arq Neuropsiquiatr* 2001;59(1):112-15.
- Halisson Yoshinari Ferreira da Cruz, Dhiego Bastos, Andrei Fernandes Joaquim. Intramedullary non-dysraphic cervical spine lipoma- case report. *Arq Bras Neurocir* 2014;33(2):147-50.
- Anita Basavaraj, Manasi Kadam, Ashish Chugh, DB Kadam. Spinal Intramedullary Lipoma without Dysraphism. *J Assoc Physicians India* 2014;62(10).
- Bulenterdocan, Muradbavbek, Nur al tinors, et al. Cervical Intramedullary Lipoma with Spinal Dysraphism. *Turkish Neurosurg* 2002;12:46- 49.
- Jeffrey P. Blount, M.D., and Scott Elton, M.D. Spinal lipomas. *Neurosurg. Focus/ Volume 10/ January, 2001.*
- CPT Nicholas Teneyuque, LTC Kathy B. Porter, Thomas Pennington: Cervicothoracic Intradural Spinal Lipoma Without Dysraphism Diagnosed Postpartum. *J Military Med* 2015;180:1:e149.
- Ahmet Bekar, Soner Sahin, Özgür Taskapiloglu et al. Intradural Spinal Lipoma: Report of A Thoracic Case and A Lumbar Case. *Turkish Neurosurg* 2004;14(1-2):52-6.
- Cem Yilmaz and Fatih Aydemir. Thoracic Intramedullary Lipoma in a 3-year-old Child: Spontaneous Decrease in the Size Following Incomplete Resection. *Asian J Neurosurg* 2018;13(1):188-190. doi: 10.4103/1793-5482.180965.
- Bhatore HS, Singh P, Chaturvedi A, et al. Nondysraphic intramedullary spinal cord lipomas: a review. *Neurosurg Focus* 2005;18(2):ECP1.
- Intradural Intramedullary and Intradural Extramedullary Lipomas Unassociated with Spinal Dysraphism. *Neuro Oncol* 14 Apr 2016.
- Asdrubal Falavigna, Ana Claudia Segatto, Karine Salgado. A Rare Case Of Intramedullary Lipoma Associated With Cyst. *Arq Neuropsiquiatr* 2001;59(1).
- Yu-ichiro Ohnishi, Koichi Iwatsuki, Takashi Moriwaki et al. Adequate Decompression of Adult Lumbar Intradural Lipoma without Dysraphism Using a Monopolar Stimulation Electrode for Intraoperative Monitoring: Case Report. *J Spine*, an open access journal ISSN: 2165-7939.
- Dino Samartzis, Christopher C. Gillis, Patrick Shih, et al. Intramedullary Spinal Cord Tumors: Part I—Epidemiology, Pathophysiology, and Diagnosis. *Global Spine J* 2015;5(5):425-35. Published online 2015 Mar 31. doi: 10.1055/s-0035-1549029.
- Kazuaki Mineta, Yuichiro Goda, Toshinori Sakai et al. Late-Onset Non-Dysraphic Intradural Spinal Cord Lipoma: A Case Report and Literature Review. *Ann Orthop Rheumatol* 2(1): 1008. Submitted: 10 December 2013; Accepted: 16 January 2014; Published: 18 January 2014.
- CMH Snelling, PM Ellis, RML Smith, et al. Lipomatous lumbar mass with an attached digit and associated split cord malformation. *Can J Neurol Sci* 2008;35:250-54.
- Cheng-Ta Hsieh, Jui-Ming Sun 1, Ming-Ying Liu. Lipoma of conus medullaris without spinal dysraphism in an adult. *Neurol India* 2009;57(6).
- Klekamp J, Fusco M, Samii M. Thoracic Intradural Extramedullary Lipoma: Report of three cases and review of the literature. *Actaneurochir (Wien)* 2001;143:767-74.