

## Morphometric analysis of various measurements of malleus on the basis of sexual dimorphism

Mayankkumar Javia<sup>1,\*</sup>, P. Saravanan<sup>2</sup>

<sup>1</sup>Associate Professor, <sup>2</sup>Assistant Professor, Dept. of Anatomy, <sup>1</sup>Banas Medical College and Research Institute, Palanpur, Gujarat, <sup>2</sup>Gujarat Adani Institute of Medical Sciences, Bhuj, Gujarat, India

\*Corresponding Author: Mayankkumar Javia

Email: drjaviamd@gmail.com

### Abstract

The malleus is the largest of the ear ossicles. In the present study, we tried to determine the normal range of the values of various measurements of malleus and whether these measurements are useful for the sexual dimorphism or not. Out of total 60 malleus used in the present study, 30 were retrieved from the male cadavers and 30 were retrieved from the female cadavers. Mean of total length of malleus, mean of length of manubrium of malleus and mean of length of head and neck of malleus in male are more as compared to female in the present study. Mean of index of malleus in male is less as compared to female in the present study. Among all the measurements taken in the present study; total length of malleus having statistically significant difference between the male and female malleus and it can be used for the sexual dimorphism of malleus for Kachchhi Gujarati population of present study.

**Keywords:** Total length of malleus, Length of manubrium of malleus, Length of head and neck of malleus, Index of malleus.

### Introduction

The malleus is the largest of the ossicles, and is shaped somewhat like a mallet. It is 8–9 mm long and has a head, neck, handle (manubrium) and anterior and lateral processes. The head is the large upper end of the bone and is situated in the epitympanic recess. It is ovoid in shape, articulates posteriorly with the incus, and is covered elsewhere by mucosa. The cartilaginous articular facet for the incus is narrowed near its middle and consists of a larger upper part and a smaller lower part, orientated almost at right angles to each other. Opposite the constriction, the lower margin of the facet projects in the form of a process, the spur of the malleus. The neck is the narrowed part below the head, and inferior to this is an enlargement from which the anterior and lateral processes project. The handle of the malleus is connected by its lateral margin to the tympanic membrane. It is directed downwards, medially and backwards. It decreases in size towards its free end, which is curved slightly forwards and is flattened transversely. Near the upper end of its medial surface there is a slight projection to which the tendon of tensor tympani is attached. The anterior process is a delicate bony spicule, directed forwards from the enlargement below the neck, and connected to the petrotympanic fissure by ligamentous fibres. In fetal life it is the longest process of the malleus and is continuous in front with Meckel's cartilage. The lateral process is a conical projection from the root of the handle of the malleus. It is directed laterally and is attached to the upper part of the tympanic membrane and, via the anterior and posterior malleolar folds, to the sides of the notch in the upper part of the tympanic sulcus. The cartilaginous precursor of the malleus originates as part of the dorsal end of Meckel's cartilage. With the exception of its anterior process, the malleus ossifies from a single endochondral centre which appears near the future neck of the bone in the fourth month *in utero*. The anterior process

ossifies separately in dense connective tissue and joins the rest of the bone at about the sixth month of fetal life.

In the present study, we tried to determine the normal range of the values of various measurements of malleus and whether these measurements are useful for the sexual dimorphism or not.

### Materials and Methods

In the present study, 60 dry adult malleus bones were used. These bones were retrieved during the routine dissection of cadavers donated to the Department of Anatomy, Gujarat Adani Institute of Medical Sciences, Bhuj, Gujarat, India. Out of total 60 malleus used, 30 were retrieved from the male cadavers and 30 were retrieved from the female cadavers. Pathological, fractured or malleus of unknown sex were excluded from the study. Only fully ossified malleus of known sex were included in the study. The study was done during the year 2017-18 after the prior approval of the institutional ethics committee of Gujarat Adani Institute of Medical Sciences, Bhuj, Gujarat, India.

Following measurements of the malleus were taken by using digital vernier caliper:

1. Total length of malleus [Fig. 1]

Total length of malleus was measured as the maximum straight distance between the top of the head and the end of the manubrium of the malleus.



**Fig. 1: Showing the measurement of total length of malleus**

2. Length of manubrium of malleus [Fig. 2]

Length of manubrium of malleus was measured as the maximum straight distance between the end of the lateral process and the end of the manubrium of the malleus.



**Fig. 2: Showing the measurement of length of manubrium of malleus**

3. Length of head and neck of malleus [Fig. 3]

Length of head and neck of malleus was measured as the maximum straight distance between the top of the head and the end of the lateral process of the malleus.



**Fig. 3: Showing the measurement of length of head and neck of malleus**

To avoid intra-observer variation, each measurement was taken at three different times and the mean of all three readings was taken as the final reading.

Above mentioned measurements were further used to calculate the following index:

1. Index of malleus

Index of malleus was calculated by using the following formula:

Index of malleus = length of manubrium of malleus/ total length of malleus x 100

For each of this measurement, mean value, standard deviation, standard error of mean, range (minimum-maximum), mean  $\pm$  SD (Standard Deviation) were calculated. Independent sample t test was applied and p value was calculated at 95% confidence interval by using SPSS (Statistical Package for the Social Sciences) software for the comparison of various parameters and index of malleus in male and female.

**Results and Discussion**

**Table 1: Showing the parameters, Sex-Male/Female, N-number of bones taken, Mean, SD-Standard deviation, Standard error of mean, Range (minimum-maximum), Mean±SD of various measurements and index of malleus**

Parameters	Sex	N	Mean	SD	Std. Error Mean	Range (min-max)	Mean±SD
Total length of malleus	male	30	7.8847 mm	0.4451 mm	0.0813 mm	6.97 mm - 8.70 mm	7.4396 mm - 8.3298 mm
	female	30	7.6280 mm	0.4801 mm	0.0877 mm	6.88 mm - 8.38 mm	7.1479 mm - 8.1081 mm
Length of manubrium of malleus	male	30	4.5943 mm	0.4514 mm	0.0824 mm	3.96 mm - 5.94 mm	4.1429 mm - 5.0457 mm
	female	30	4.4787 mm	0.3667 mm	0.0669 mm	3.56 mm - 5.12 mm	4.1120 mm - 4.8454 mm
Length of head and neck of malleus	male	30	5.0627 mm	0.3830 mm	0.0699 mm	4.16 mm - 5.65 mm	4.6797 mm - 5.4457 mm
	female	30	4.9490 mm	0.2489 mm	0.0454 mm	4.43 mm - 5.50 mm	4.7001 mm - 5.1979 mm
Index of malleus	male	30	58.2517	4.3775	0.7992	51.62-71.83	53.8742 - 62.6292
	female	30	58.7860	4.4245	0.8078	51.00- 69.96	54.3615- 63.2105

As shown in the table 1, in the present study, mean of total length of malleus in male is 7.8847 mm, SD is 0.4451 mm, range from 6.97 mm to 8.70 mm and mean±SD from 7.4396 mm to 8.3298 mm. Mean of total length of malleus in female is 7.6280 mm, SD is 0.4801 mm, range from 6.88 mm to 8.38 mm and mean±SD from 7.1479 mm to 8.1081 mm.

Mean of length of manubrium of malleus in male is 4.5943 mm, SD is 0.4514 mm, range from 3.96 mm to 5.94 mm and mean±SD from 4.1429 mm to 5.0457 mm. Mean of length of manubrium of malleus in female is 4.4787 mm, SD is 0.3667 mm, range from 3.56 mm to 5.12 mm and mean±SD from 4.1120 mm to 4.8454 mm.

Mean of length of head and neck of malleus in male is 5.0627 mm, SD is 0.3830 mm, range from 4.16 mm to 5.65

mm and mean±SD from 4.6797 mm to 5.4457 mm. Mean of length of head and neck of malleus in female is 4.9490 mm, SD is 0.2489 mm, range from 4.43 mm to 5.50 mm and mean±SD from 4.7001 mm to 5.1979 mm.

Mean of index of malleus in male is 58.2517, SD is 4.3775, range from 51.62 to 71.83 and mean±SD from 53.8742 to 62.6292. Mean of index of malleus in female is 58.7860, SD is 4.4245, range from 51 to 69.96 and mean±SD from 54.3615 to 63.2105.

Mean of total length of malleus, mean of length of manubrium of malleus and mean of length of head and neck of malleus in male are more as compared to female in the present study. Mean of index of malleus in male is less as compared to female in the present study.

**Table 2: Showing the statistical analysis and the results of independent samples test applied to various measurements and index of malleus**

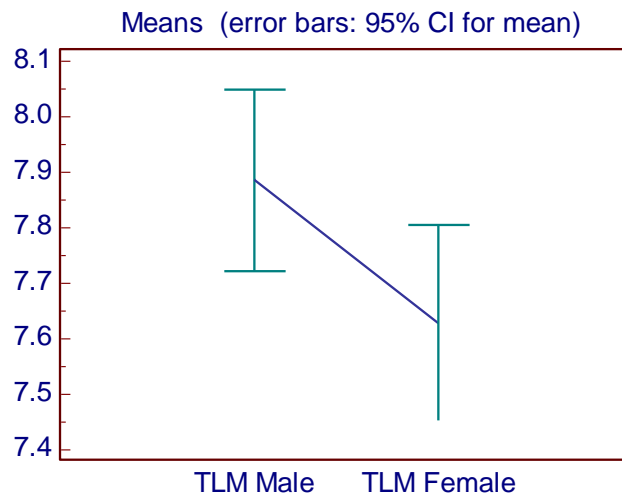
		Independent Samples Test									
		Levene's Test for Equality of Variances		t-test for Equality of Means							
		F	Sig.	t	df	Sig. (2-tailed)	Mean Difference	Std. Error Difference	95% Confidence Interval of the Difference		
										Lower	Upper
Total length of malleus	Equal variances assumed	1.307	.258	2.147	58	.036	.2566667	.1195318	.0173978	.4959355	
	Equal variances not assumed			2.147	57.670	.036	.2566667	.1195318	.0173687	.4959647	
Length of manubrium of malleus	Equal variances assumed	.288	.594	1.089	58	.281	.1156667	.1061797	-.0968750	.3282083	
	Equal variances not assumed			1.089	55.663	.281	.1156667	.1061797	-.0970652	.3283985	

Length of head and neck of malleus	Equal variances assumed	5.480	.023	1.363	58	.178	.1136667	.0833870	-.0532506	.2805840	
	Equal variances not assumed			1.363	49.790	.179	.1136667	.0833870	-.0538386	.2811720	
Index of malleus	Equal variances assumed	.067	.797	-.470	58	.640	-.5342799	1.1362460	-	2.8087234	1.7401637
	Equal variances not assumed			-.470	57.994	.640	-.5342799	1.1362460	-	2.8087288	1.7401690

As shown in table 2, p value for the total length of malleus (for both- with equal variances assumed as well as equal variances not assumed) is 0.036, which suggest statistically significant difference between the male and

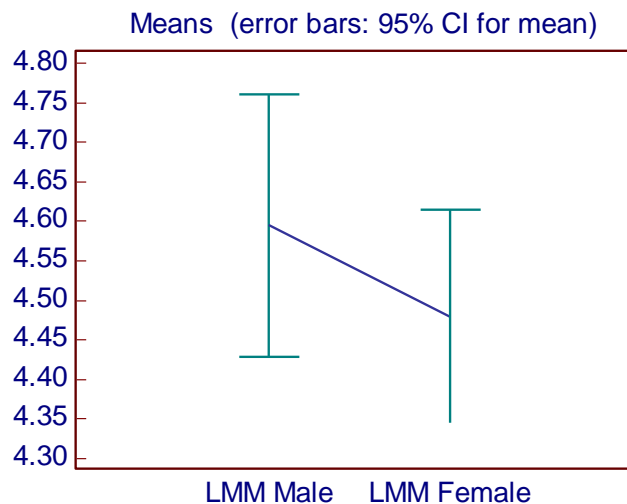
female malleus for the total length of malleus. P values for other parameters are more than 0.05, which suggest that there is no statistically significant difference for these parameters of malleus between male and female.

**Graph 1: Showing the distribution of observations of total length of malleus in male and female (with 95% confidence interval for mean) as well as line joining the mean of total length of malleus in male and mean of total length of malleus in female**



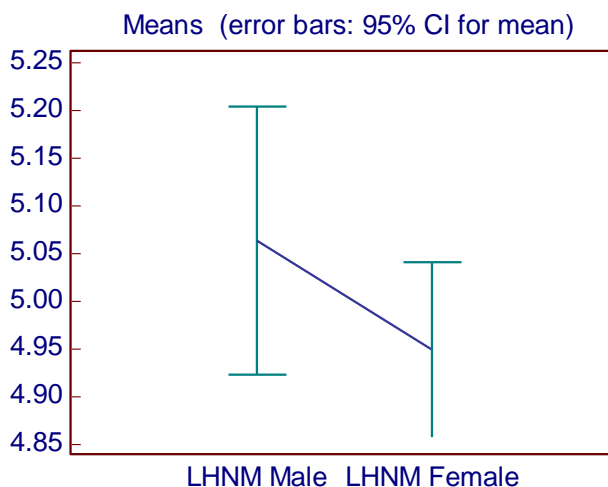
(TLM: Total Length of Malleus)

**Graph 2: Showing the distribution of observations of length of manubrium of malleus in male and female (with 95% confidence interval for mean) as well as line joining the mean of length of manubrium of malleus in male and mean of length of manubrium of malleus in female**



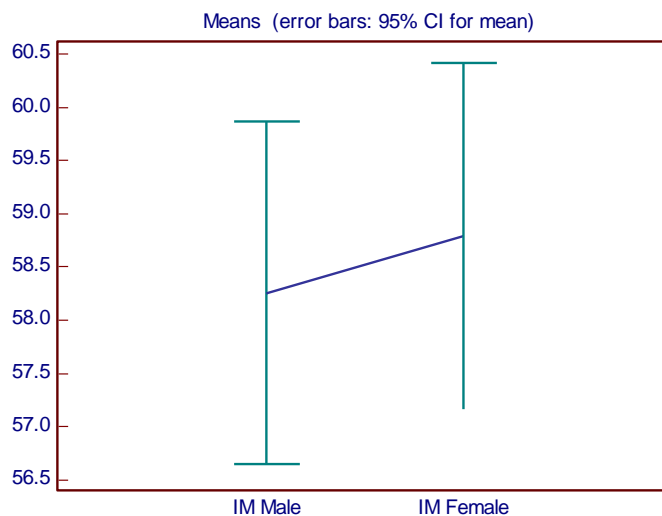
(LMM: Length of Manubrium of Malleus)

**Graph 3:** Showing the distribution of observations of length of head and neck of malleus in male and female (with 95% confidence interval for mean) as well as line joining the mean of length of head and neck of malleus in male and mean of length of head and neck of malleus in female.



(LHNM: Length of Head and Neck of Malleus)

**Graph 4:** Showing the distribution of observations of index of malleus in male and female (with 95% confidence interval for mean) as well as line joining the mean of index of malleus in male and mean of index of malleus in female.



(IM: Index of Malleus)

**Table 3:** Showing the comparison of findings of various parameters and index of malleus of male and female in the present study with the findings of other researchers

No	Researcher	Study population	Sample size	Sex and side	Parameters			
					Total length of malleus (mm) (mean±SD)	Length of manubrium of malleus (mm) (mean±SD)	Length of head and neck of malleus (mm) (mean±SD)	Index of malleus (mean±SD)
1	Harneja NK and Chaturvedi RP (1973)	Rajasthan India	50	-	7.15 ±0.31	4.22 ±0.35	-	-

2	Arensburg et al (1981)	Indian	31	-	7.8 ±0.35	4.4 ±0.47	-	56.6
3	Oschman Z and Meiring JH (1991)	South african	122	-	7.844	4.399	-	-
4	Bhatnagar DP et al (2001)	Patiala, Punjab, India	60	-	8.36 ±1.39	4.65 ±0.27	-	-
5	Unur E et al (2002)	Turkey (newborn)	40	-	7.69 ±0.6	4.7 ±0.45	4.85 ±0.29	60.97 ±3.77
6	Singh K et al (2012)	Haryana India	60	Right	7.947 ±0.415	4.762 ±0.45139	5.237 ±0.3409	-
			60	Left	7.9467 ±0.401	4.726 ±0.376	5.2172 ±0.4	-
			30	Male right	8.078 ±0.453	4.896 ±0.384	5.194 ±0.363	-
			30	Female right	7.817 ±0.334	4.628 ±0.48	5.28 ±0.318	-
			30	Male left	8.045 ±0.471	4.844 ±0.341	5.21 ±0.462	-
			30	Female left	7.848 ±0.294	4.608 ±0.379	5.224 ±0.335	-
7	Nadeem G (2012-13)	Indian	30	-	8 ±0.046	4.58 ±0.015	-	-
8	Ramirez LM and Ballesteros LE (2013)	Columbian	23	-	8.18 ±0.24	4.91 ±0.25	-	-
9	Mogra K et al (2014)	Rajasthan India	66	Total	8.53 ±0.58	5.2 ±0.48	4.72 ±0.82	61.01 ±3.74
			33	Right	8.515 ±0.6553	5.106 ±0.4636	4.606 ±0.8078	60.18 ±3.555
			33	Left	8.545 ±0.5056	5.303 ±0.4831	4.833 ±0.826	61.84 ±3.788
10	Vinayachandra PH et al (2014)	South Indian	50	-	7.45 ±0.39	-	-	-
11	Rathava J et al (2015)	Gujarati	60	-	7.81 ±0.32	4.59 ±0.34	5 ±0.2	-
12	K Radha (2016)	South Indian	25	-	7.4	4.2	-	-
13	Sodhi S et al (2017)	North India	100	Total	7.83	4.44	4.68	56.77
			50	Right	7.87 ±0.37	4.47 ±0.41	4.7 ±0.43	56.77
			50	Left	7.8 ±0.54	4.42 ±0.42	4.68 ±0.41	56.78
14	Present study (2017-18)	Kachchhi (Gujarati)	30	Male	7.8847 ±0.4451	4.5943 ±0.4514	5.0627 ±0.383	58.2517 ±4.3775
			30	Female	7.628 ±0.4801	4.4787 ±0.3667	4.949 ±0.2489	58.786 ±4.4245

As shown in table 3, Harneja NK and Chaturvedi RP in 1973 measured the total length and length of manubrium of malleus in Rajasthani population (sample size 50). In that study, mean of total length of malleus was 7.15 mm with SD 0.31 mm and mean of length of manubrium of malleus was 4.22 mm with SD 0.35 mm.

Arensburg et al in 1981 measured the total length, length of manubrium and index of malleus in Indian population (sample size 31). In that study, mean of total length of malleus was 7.8 mm with SD 0.35 mm, mean of length of manubrium of malleus was 4.4 mm with SD 0.47 mm and mean of index of malleus was 56.6.

Oschman Z and Meiring JH in 1991 measured the total length and length of manubrium of malleus in South African population (sample size 122). In that study, mean of total length of malleus was 7.844 mm and mean of length of manubrium of malleus was 4.399.

Bhatnagar DP et al in 2001 measured the total length and length of manubrium of malleus in population of Patiala (Punjab, India) (sample size 60). In that study, mean of total length of malleus was 8.36 mm with SD 1.39 mm and mean of length of manubrium of malleus was 4.65 mm with SD 0.27 mm.

Unur E et al in 2002 measured the total length, length of manubrium, length of head and neck and index of malleus in Turkish population (sample size 40). In that study, mean of total length of malleus was 7.69 mm with SD 0.6 mm, mean of length of manubrium of malleus was 4.7 mm with SD 0.45 mm, mean of length of head and neck of malleus was 4.85 mm with SD 0.29 mm and mean of index of malleus was 60.97 with SD 3.77.

Singh K et al in 2012 measured the total length, length of manubrium and length of head and neck of malleus in population of Haryana, India (sample size: male right 30, male left 30, female right 30, female left 30). In that study, mean of total length of malleus of right side was 7.947 mm with SD 0.415 mm, of left side was 7.9467 mm with SD 0.401 mm, of male right side was 8.078 mm with SD 0.453 mm, of female right side was 7.817 mm with SD 0.334 mm, of male left side was 8.045 mm with SD 0.471 mm and of female left side was 7.848 mm with SD 0.294 mm. In that study, mean of length of manubrium of malleus of right side was 4.762 mm with SD 0.45139 mm, of left side was 4.726 mm with SD 0.376 mm, of male right side was 4.896 mm with SD 0.384 mm, of female right side was 4.628 mm with SD 0.48 mm, of male left side was 4.844 mm with SD 0.341 mm and of female left side was 4.608 mm with SD 0.379 mm. In that study, mean of length of head and neck of malleus of right side was 5.237 mm with SD 0.3409 mm, of left side was 5.2172 mm with SD 0.4 mm, of male right side was 5.194 mm with SD 0.363 mm, of female right side was 5.28 mm with SD 0.318 mm, of male left side was 5.21 mm with SD 0.462 mm and of female left side was 5.224 mm with SD 0.335 mm.

Nadeem G in 2012-13 measured the total length and length of manubrium of malleus in Indian population (sample size 30). In that study, mean of total length of malleus was 8 mm with SD 0.046 mm and mean of length of manubrium of malleus was 4.58 mm with SD 0.015 mm.

Ramirez LM and Ballesteros LE in 2013 measured the total length and length of manubrium of malleus in Columbian population (sample size 23). In that study, mean of total length of malleus was 8.18 mm with SD 0.24 mm and mean of length of manubrium of malleus was 4.91 mm with SD 0.25 mm.

Mogra K et al in 2014 measured the total length, length of manubrium, length of head and neck and index of malleus in population of Rajasthan, India (sample size: right 33, left 33). In that study, mean of total length of malleus was 8.53 mm with SD 0.58 mm, of right side was 8.515 mm

with SD 0.6553 mm and of left side was 8.545 mm with SD 0.5056 mm. In that study, mean of length of manubrium of malleus was 5.2 mm with SD 0.48 mm, of right side was 5.106 mm with SD 0.4636 mm and of left side was 5.303 mm with SD 0.4831 mm. In that study, mean of length of head and neck of malleus was 4.72 mm with SD 0.82 mm, of right side was 4.606 mm with SD 0.8078 mm and of left side was 4.833 mm with SD 0.826 mm. In that study, mean of index of malleus was 61.01 with SD 3.74, of right side was 60.18 with SD 3.555 and of left side was 61.84 with SD 3.788.

Vinayachandra PH et al in 2014 measured the total length of malleus in South Indian population (sample size 50). In that study, mean of total length of malleus was 7.45 mm with SD 0.39 mm.

Rathava J et al in 2015 measured the total length, length of manubrium and length of head and neck of malleus in population of Gujarat, India (sample size 60). In that study, mean of total length of malleus was 7.81 mm with SD 0.32 mm, mean of length of manubrium of malleus was 4.59 mm with SD 0.34 mm and mean of length of head and neck of malleus was 5 mm with SD 0.2 mm.

K Radha in 2016 measured the total length and length of manubrium of malleus in South Indian population (sample size 25). In that study, mean of total length of malleus was 7.4 mm and mean of length of manubrium of malleus was 4.2 mm.

Sodhi S et al in 2017 measured the total length, length of manubrium, length of head and neck and index of malleus in North Indian population (sample size: right 50, left 50). In that study, mean of total length of malleus was 7.83 mm, of right side was 7.87 mm with SD 0.37 mm and of left side was 7.8 mm with SD 0.54 mm. In that study, mean of length of manubrium of malleus was 4.44 mm, of right side was 4.47 mm with SD 0.41 mm and of left side was 4.42 mm with SD 0.42 mm. In that study, mean of length of head and neck of malleus was 4.68 mm, of right side was 4.7 mm with SD 0.43 mm and of left side was 4.68 mm with SD 0.41 mm. In that study, mean of index of malleus was 56.77, of right side was 56.77 and of left side was 56.78.

In the present study (2017-18), we measured the total length, length of manubrium, length of head and neck and index of malleus in population of Kachchh, Gujarat, India. In this study, mean of total length of malleus in male is 7.8847 mm with SD 0.4451 and in female it is 7.628 mm with SD 0.4801 mm. Mean of length of manubrium of malleus in male is 4.5943 mm with SD 0.4514 mm and in female it is 4.4787 mm with SD 0.3667 mm. Mean of length of head and neck of malleus in male is 5.0627 mm with SD 0.383 mm and in female it is 4.949 mm with SD 0.2489 mm. Mean of index of malleus in male is 58.2517 with SD 4.3775 and in female it is 58.786 with SD 4.4245.

## Conclusion

We determined the normal range of the values of various measurements and index of malleus in the Kachchhi Gujarati population of present study. Among all the

measurements taken in the present study; total length of malleus having statistically significant difference between the male and female malleus and it can be used for the sexual dimorphism of malleus for Kachchhi Gujarati population of present study.

**Conflict of Interest:** Nil.

## References

1. Standring S. Gray's anatomy 40th Edition. Anatomical Basis Of Clinical Practice, Churchill Livingstone, London 2008; 36:627
2. Harneja NK, Chaturvedi RP. A study of the human ear ossicles. *Indian J Otol* 1973;25:154-160.
3. Arensburg B, Harell M, Nathan H. The human middle ear ossicles, morphometry and taxonomic implications. *J Hum Evol* 1981;10:199-205.
4. Oschman Z and Meiring JH; A Morphometric and Comparative Study of The Malleus; *Acta Anatomica* 1991;142(1):60-61.
5. Bhatnagar DP, Singal P and Thapar SP; Anatomy of Malleus- A Human Ear Ossicle; *Anthropologists* 2001;3(2):139-141.
6. Unur E, Ulger H, Ekinici N. Morphometrical and Morphological variations in the middle ear ossicles in the newborn. *Erciyes Med J* 2002;24(2):57-63.
7. Singh K, Chhabra S, Sirohiwal BL, Yadav SPS. Morphometry of malleus a possible tool in sex determination. *J Forensic Res* 2012;3(6):1-3.
8. Nadeem G. Can fetal ossicles be used as prosthesis in adults? A morphometric study. *Int J Exp Clin Anat* 2012-13;6(7):52-57.
9. Ramirez, LM and Ballesteros, LE; Anthropometry of the Malleus in Humans: A Direct Anatomic Study; *Int J Morphol* 2013;31(1):177-183.
10. Mogra K, Gupta S, Chauhan S. Morphological and morphometrical variations of malleus in human cadavers. *Int J Health Biomed Res* 2014;2(3):186-192.
11. Vinaychandra P H. Morphometry and variations of malleus with clinical correlation. *Int J Anat Res* 2014;2(1):191-194.
12. Rathava J, Trivedi P, Kukadiya U. Morphometric study of malleus in Gujarati population. *Int J Adv Res* 2015;3(3):306-310.
13. Radha K. Morphological and morphometric study of malleus in South Indian population. *Int J Anat Res* 2016;4(2):2342-2344.
14. Sodhi S, Singh Z, Lal J. Morphometric dimensions of human ear ossicles of males. *Natl J Med Res* 2017;7(1):47-51.

**How to cite this article:** Javia M, Saravanan P. Morphometric analysis of various measurements of malleus on the basis of sexual dimorphism. *Indian J Anat Surg Head Neck Brain* 2018;4(4):94-101.