

A study of morphological spectrum of upper gastrointestinal tract lesions by endoscopy and correlation between endoscopic and histopathological findings

Deepa Rani¹, Stuti Bhuvan^{2,*}, Atul Gupta³

¹Associate Professor, ²Junior Resident, ³Professor, Dept. of Pathology, S.N. Medical College, Agra, Uttar Pradesh, India

***Corresponding Author:**

Email: stutibhuvan015@gmail.com

Received: 30th June, 2018

Accepted: 6th August, 2018

Abstract

Introduction: With the increasing use of endoscopy, gastrointestinal abnormalities are encountered more often. However it has been realized that endoscopic appearances are not pathognomonic and they need histological confirmation. The objective of this study was to determine the morphological spectrum of upper gastrointestinal tract lesions on histopathology and the correlation between endoscopic and histopathological diagnosis.

Materials and Methods: A histopathological study was carried out in 100 endoscopic biopsy specimens of upper gastrointestinal tract lesions. Conventional haematoxylin and eosin staining was done in all the 100 cases. Warthin-Starry stain was done in gastric biopsies, where there was suspicion of *Helicobacter pylori* (*H. pylori*) gastritis on histopathology.

Results: In our study, out of 100 cases, stomach was the most common site, comprising of 46% of all the cases followed by esophagus (30%) and duodenum (24%). On histology, squamous cell carcinoma of esophagus was found to be the most common lesion with an incidence of 22%, followed by celiac disease (14%), *H. pylori* gastritis (9%) and fundic gland polyp (8%). Our data suggested that in case of visible growth on endoscopy, the biopsy correlated well with histopathology. However, histopathology significantly improved the diagnosis of inflammatory lesions.

Conclusion: Endoscopic procedure in adjunction with histological interpretation remains the mainstay of diagnostic modality in cases of upper gastrointestinal tract lesions.

Keywords: Upper gastrointestinal tract, Endoscopy, Biopsy, Histopathology.

Introduction

Human gastrointestinal tract is long, tortuous and common site for lesions like congenital, inflammatory and neoplastic conditions.¹ To facilitate diagnosis of different lesions, endoscopy and histology are complementary.² Endoscopic biopsies are performed not only for the diagnosis of the disease but also for monitoring its course, determining its extent and responses to therapy and for early detection of complications.¹ Upper gastrointestinal tract is a common site for neoplasms, especially malignant tumors. Worldwide, gastric adenocarcinoma is the second most common cancer, and carcinoma of esophagus is the sixth leading cause of death.³ The purpose of this study was to determine the spectrum of morphological lesions of upper gastrointestinal tract and find out the correlation between endoscopic and histopathological diagnosis.

Aims and Objectives

1. To study the morphological spectrum of endoscopic biopsies of upper gastrointestinal tract lesions on histopathology.
2. To study the incidence of various lesions identified.
3. To study the correlation between endoscopic diagnosis and histopathological diagnosis.

Materials and Methods

The material for the study was endoscopic biopsies of upper gastrointestinal tract lesions sent to the histopathology department over a period of 1.5 years. A total of 100 cases

were studied. Endoscopic biopsy specimens were fixed in 10% buffered formal saline, followed by tissue processing, embedding and sectioning. The tissue sections were stained with haematoxylin and eosin. In addition, Warthin-Starry stain was performed to confirm the presence of *Helicobacter pylori* (*H. pylori*) in the cases where there was suspicion of *H. pylori* gastritis on histology.

Results

The histopathological examination was done in hundred endoscopic biopsies of the upper gastrointestinal lesions. Out of 100 cases examined in the study, there were 61 males and 39 females. Overall male to female ratio in our study was 1.5:1. The youngest patient in our study was 21 years old, while the oldest one was of 80 years. Maximum number of cases were in 5th to 7th decade of life. Out of 100 cases, 30% of the biopsies were from the esophagus, 46% from the stomach and 24% were from the duodenum. In our study, non-neoplastic lesions (54%) were more common than the neoplastic lesions (46%).

Thirty esophageal biopsies were examined in the present study, out of which, two (6.7%) were non-neoplastic and twenty eight (93.3%) were neoplastic. Moderately differentiated squamous cell carcinoma was the commonest lesion, found in twelve (40%) cases. This was followed by well differentiated squamous cell carcinoma in six cases (20%), poorly differentiated squamous cell carcinoma in six cases (13.3%) and adenocarcinoma in five cases (16.7%). Two cases (6.7%) were of reflux esophagitis. The least

common lesion in esophagus was squamous papilloma, which constituted 3.3% of all the cases. [Table 1a], [Fig. 1].

A total of 46 endoscopic gastric biopsies were examined, out of which thirty two (69.6%) were non-neoplastic lesions and fourteen (30.4%) were neoplastic. Overall, the most common lesion in the stomach was H. pylori gastritis (19.5%), followed by fundic gland polyp (17.5%). Chronic non-specific gastritis and signet ring cell adenocarcinoma occurred with equal frequency (15% each). This was followed by tubular adenocarcinoma, which constituted 11% of all cases. Four cases (8.8%) each of gastric ulcer and hyperplastic polyp and one case (2.2%) each of papillary adenocarcinoma and diffuse large B cell lymphoma (DLBCL) were also diagnosed. Thus, the most common non-neoplastic lesion was H. pylori gastritis and the most common neoplastic lesion was signet ring cell adenocarcinoma. [Table 1b], [Fig. 2 and 3].

Out of twenty four duodenal biopsies, twenty (83.3%) were non-neoplastic and four (16.7%) were neoplastic.

Overall, celiac disease was the commonest diagnosis, comprising of 14 cases (58.5%), followed by duodenitis and adenocarcinoma, which constituted three cases (12.5%) of each. Two cases (8.3%) were found to have normal histology. One case (4.1%) each of Giardiasis and low grade neuroendocrine tumor G1 (carcinoid) was also diagnosed. [Table 1c], [Fig. 4].

In the present study, a total of hundred upper gastrointestinal tract biopsies were subjected to histopathological examination. Stomach was the most common site comprising of 46% of all the cases, followed by esophagus (30%) and duodenum (24%). On histology, squamous cell carcinoma of esophagus was found to be the most common lesion with an incidence of 22%, followed by celiac disease (14%), H. pylori gastritis (9%) and fundic gland polyp (8%) [Table 2].

Table 1(a): Distribution of esophageal lesions according to histopathological findings

Nature of cases	Lesions	Number of cases	Percentage%
Non-neoplastic	Reflux esophagitis	02	6.7
Benign	Squamous papilloma	01	3.3
Malignant	Well differentiated squamous cell carcinoma	06	20
	Moderately differentiated squamous cell carcinoma	12	40
	Poorly differentiated squamous cell carcinoma	04	13.3
	Adenocarcinoma	05	16.7
Total		30	100

Table 1(b): Distribution of gastric lesions according to histopathological findings

Nature of cases	Lesions	Number of cases	Percentage%
Non-neoplastic	Gastric ulcer	04	8.8
	Chronic nonspecific gastritis	07	15
	H.pylori gastritis	09	19.5
	Hyperplastic polyp	04	8.8
	Fundic gland polyp	08	17.5
Neoplastic	Tubular adenocarcinoma	05	11
	Signet ring cell adenocarcinoma	07	15
	Papillary adenocarcinoma	01	2.2
	Lymphoma(DLBCL)	01	2.2
Total		46	100

Table 1(c): Distribution of duodenal lesions according to histopathological findings

Nature of cases	Lesions	Number of cases	Percentage%
Non-neoplastic	Normal	02	8.3
	Giardiasis	01	4.1
	Duodenitis	03	12.5
	Celiac disease	14	58.5
Neoplastic	Adenocarcinoma	03	12.5
	Neuroendocrine tumor G1	01	4.1
Total		24	100

Table 2: Incidence of upper gastrointestinal tract lesions diagnosed on the basis of histology on endoscopic biopsies

S. No.	Lesions	Site	Cases	Incidence
1	Reflux Esophagitis	Esophagus	02	02%
2	Squamous papilloma	Esophagus	01	01%
3	Squamous cell carcinoma	Esophagus	22	22%
4	Adenocarcinoma	Esophagus	05	05%
5	Gastric ulcer	Stomach	04	04%
6	Chronic nonspecific gastritis	Stomach	07	07%
7	H. pylori gastritis	Stomach	09	09%
8	Hyperplastic polyp	Stomach	04	04%
9	Fundic gland polyp	Stomach	08	08%
10	Signet ring cell adenocarcinoma	Stomach	07	07%
11	Tubular adenocarcinoma	Stomach	05	05%
12	Papillary adenocarcinoma	Stomach	01	01%
13	Lymphoma (DLBCL)	Stomach	01	01%
14	Normal duodenum	Duodenum	02	02%
15	Duodenitis	Duodenum	03	03%
16	Celiac disease	Duodenum	14	14%
17	Giardia	Duodenum	01	01%
18	Adenocarcinoma	Duodenum	03	03%
19	Neuroendocrine tumor G1	Duodenum	01	01%
	Total		100	100%

Table 3(a): Correlation between endoscopic and histopathological findings of esophageal lesions

Endoscopic Findings	Histopathological Findings			
	Reflux Esophagitis	Squamous Papilloma	Carcinoma	Total
Erythema	02	-	-	02
Ulcer	-	-	02	02
Growth	-	01	25	26
Total	02	01	27	30

Table-3(b): Correlation between endoscopic and histopathological findings of gastric lesions

Endoscopic Findings	Histopathological Findings							
	Gastric Ulcer	Chronic non-specific gastritis	H.pylori gastritis	Hyperplastic polyp	Fundic gland polyp	Carcinoma	Lymphoma	Total
Erythema	-	01	02	-	-	-	-	03
Ulcer	04	04	04	-	-	02	-	14
Erosion	-	02	03	-	-	-	-	05
Polypoidal growth	-	-	-	04	08	-	-	12
Growth (suspicious of malignancy)	-	-	-	-	-	11	01	12
Total	04	07	09	04	08	13	01	46

Table 3(c): Correlation between endoscopic and histopathological findings of duodenal lesions

Endoscopic Findings	Histopathological Findings						
	Normal	Duodenitis	Celiac Disease	Giardia	Adenocarcinoma	Carcinoid	Total
Normal	02	-	02	-	-	-	04
Erythema	-	03	-	01	-	-	04
Scalloping of mucosa	-	-	12	-	-	-	12
Growth (suspicious of malignancy)	-	-	-	-	03	01	03
Total	02	03	14	01	03	01	24

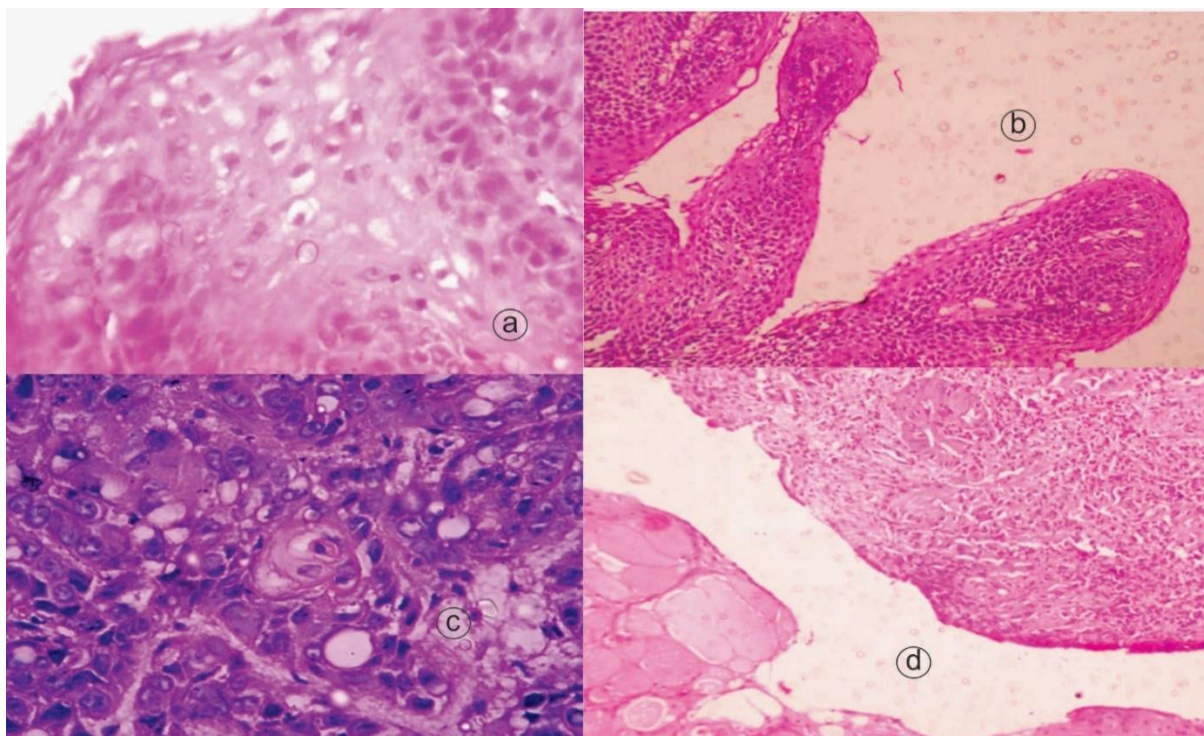


Fig. 1a: Reflux esophagitis showing intercellular edema, balloon cells and intraepithelial lymphocytes (arrows). (H & E, 400X) **b:** Squamous papilloma of esophagus showing benign squamous epithelium, lining delicate connective tissue stalks. (H & E, 100X); **c:** Moderately differentiated squamous cell carcinoma of esophagus showing large; **d:** Moderately differentiated adenocarcinoma of esophagus showing glandular differentiation. (H& E, 100X)

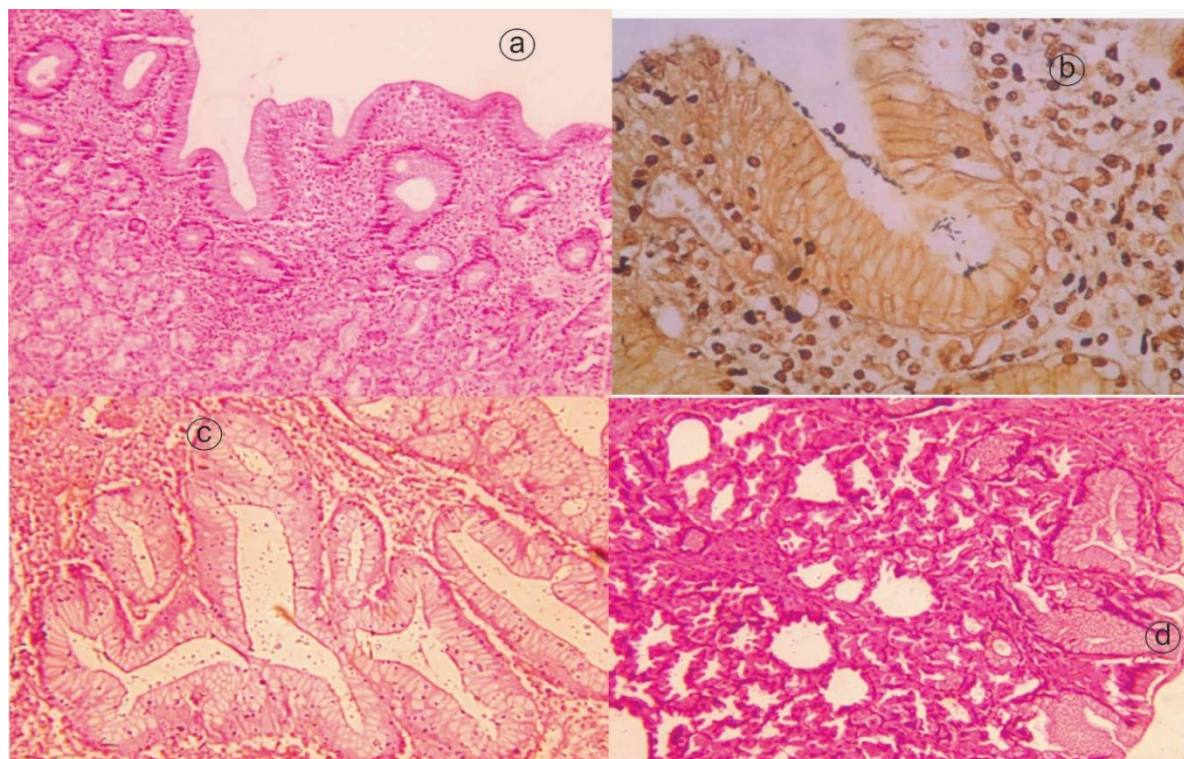


Fig. 2a: Chronic nonspecific gastritis showing superficial lympho-plasmacytic inflammation. (H & E, 100X); **b:** *Helicobacter pylori* gastritis. Organisms present in the lumen, and less tightly adherent to surface foveolar cells (Warthin-Starry stain, 100X); **c:** Hyperplastic polyp of stomach showing inflamed stroma and tortuous gland. (H & E, 100) **d:** Fundic gland polyp of stomach showing cystically dilated glands lined by parietal cells (H & E, 100X)

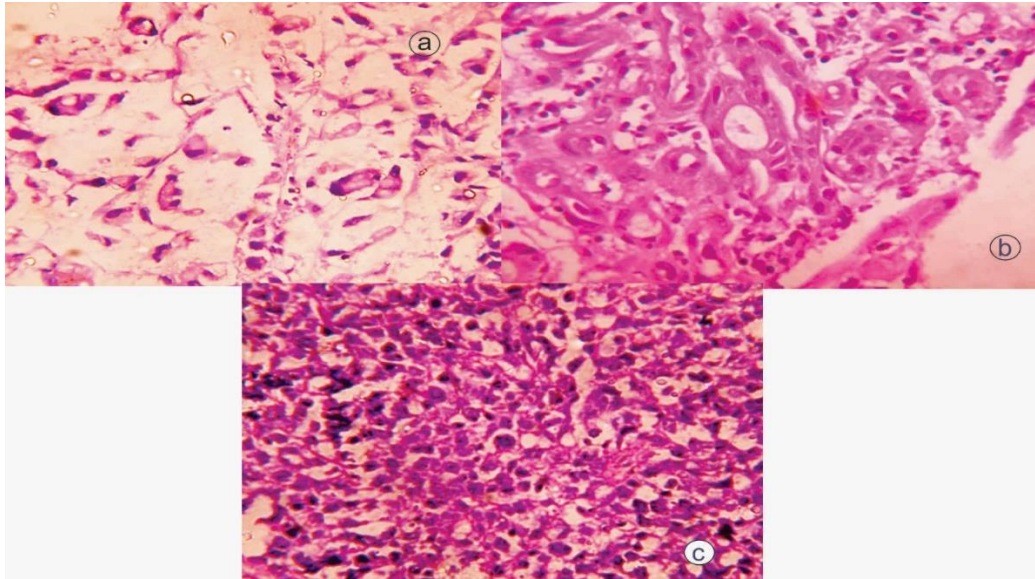


Fig. 3a: Signet ring cell adenocarcinoma of the stomach showing malignant cells with large, atypical nuclei, prominent nucleoli and intracytoplasmic mucin-filled vesicles that impart the signet ring” appearance. (H & E, 400X); **b:** Tubular adenocarcinoma of stomach showing glandular structure lined by malignant cells. (H & E, 400X); **C:** Gastric DLBCL showing sheets of pleomorphic large cells with prominent nucleoli and moderate amounts of cytoplasm. (H & E, 400 X)

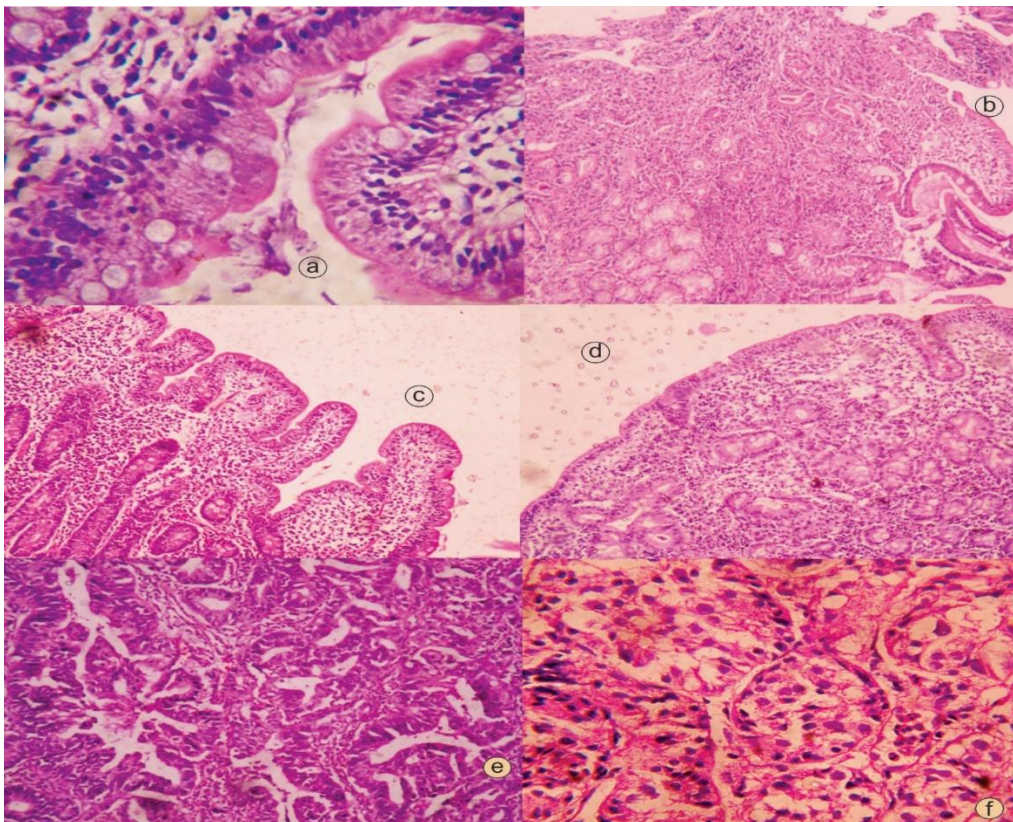


Fig. 4a: Giardiasis showing pear-shaped organism with prominent paired nuclei, paired median rods, a curved median body and flagellae. (H & E, 400X); **b:** Chronic duodenitis showing increased chronic inflammation in lamina propria and prominent intramucosal Brunner glands. (H & E, 100X); **c:** Duodenal biopsy-Grade I celiac disease showing increased intraepithelial lymphocytes. (H & E, 100X); **d:** Duodenal biopsy-Grade III celiac disease showing marked villous blunting, increased surface intraepithelial lymphocytes. (H & E); **e:** Duodenal adenocarcinoma showing glands lined by malignant cells. (H & E, 100 X); **f:** Carcinoid tumor of duodenum showing small, polygonal cells with moderate amount of eosinophilic cytoplasm and round, regular nuclei displaying the typical salt and pepper chromatin

Discussion

In the present study, our aim was to find out the morphological spectrum of endoscopic biopsies of upper gastrointestinal tract lesions on histopathology, incidence of various lesions identified and correlation between endoscopic findings and histopathological diagnosis of upper gastrointestinal tract lesions.

Overall male to female ratio in our study was 1.5:1, which was comparable to the findings of Islam SMJ, who reported a ratio of 1.4:1.⁴ Upper gastrointestinal tract lesions were more common in males as compared to females, as also stated in the study by Rashmi K et al.⁵ In our study, maximum number of cases were in 5th to 7th decade, which was comparable to the findings of the studies conducted by Jeshadi A et al and Sharma S et al.^{1,2} In our study, over all, stomach was found to be the most common site for upper gastrointestinal tract lesions followed by esophagus and duodenum. This correlated with the findings of Rashmi K et al and Gulia SP et al.^{5,6}

Among thirty esophageal biopsies studied, neoplastic conditions predominated (93.3%). This finding correlated with the study of Sheikh BA et al.⁷ In our study, most common esophageal lesion was moderately differentiated squamous cell carcinoma (40%). This was similar to the findings of Jawalkar S et al and Pun CB et al, who also reported moderately differentiated squamous cell carcinoma to be the most common lesion in their studies.^{8,9}

Out of forty-six biopsies from the stomach, 32 (69.5%) cases were non-neoplastic lesions, whereas 14 (30.5%) cases were neoplastic. This observation correlated with those of Rashmi K et al and Sheikh BA et al.^{5,7} The most common non-neoplastic lesion in our study was *H. pylori* gastritis. Sheikh BA et al also found *H. pylori* gastritis (20.4%) to be the commonest non-neoplastic lesion in their study.⁷ In our study, all fourteen neoplastic lesions were found to be malignant on histology. Seven (15.2%) were diagnosed as signet ring carcinoma, five (10.8%) as tubular carcinoma and one case each (2.1%) as lymphoma (DLBCL) and papillary adenocarcinoma. These findings differed from the study done by Sheikh BA et al, in which moderately differentiated adenocarcinoma was the most common lesion.⁷

Out of 24 duodenal biopsies in our study, 20 (83.4%) were diagnosed as non-neoplastic and 4 (16.6%) as neoplastic. Thus non-neoplastic lesions predominated in duodenal biopsies and this finding correlated well with the studies done by Rashmi et al and Jawalkar S et al.^{5,8}

Overall on histology, squamous cell carcinoma of esophagus was found to be the most common lesion with an incidence of 22%. In stomach, the most common lesion was *H. pylori* gastritis (9%) and in duodenum, celiac disease (14%) was found to be the most common lesion. These findings correlated well with the study done by Menon F et al.¹⁰

Correlation between Endoscopic and Histopathological findings of Upper Gastrointestinal Tract Lesions: Among all histologically confirmed malignant tumors of esophagus, all 27 cases (100%) were reported as 'suspicious of

malignancy' on endoscopy as well. This correlated with the study done by Islam SMJ et al.⁴

Endoscopy of stomach showed various findings such as erythema, erosion and ulcer. In our study, the correlation between endoscopy and histology in malignant cases was good and the findings were similar to the ones reported by Jeshadi S et al and Sharma S et al, who also observed good correlation between the two techniques in the cases of carcinoma.^{1,2}

In our study, 24 lesions were biopsied from the duodenum. In 13 cases, scalloping of mucosal folds was seen on endoscopy and all these cases were diagnosed as celiac disease on histology. Hence, the endoscopic and histological findings of celiac disease correlated well with each other. Four cases were diagnosed as suspicious of malignancy on endoscopy, out of which three cases were diagnosed as adenocarcinoma of duodenum on histology and one case was diagnosed as carcinoid. These findings correlated well with the study done by Islam SMJ et al.⁴

Thus the two techniques complement each other in the management of patients with upper gastrointestinal tract lesions, but histological examination is essential for the confirmation of diagnosis.

Conclusion

Upper gastrointestinal tract endoscopy helps in visualization of specific site of mucosal lesions. Endoscopy is incomplete without biopsy and histopathology is the gold standard for the diagnosis of endoscopically detected lesions. Hence, we can conclude that the combination of these two methods provide a powerful diagnostic tool for better patient management.

Financial Support and Sponsorship: Nil.

Conflicts of Interest: None.

References

1. Jeshadi A, Mohammad AM, Kadaru MR, Nagamuthu ER, Kalangi H, Boddu A et al. Study of gastric biopsies with clinicopathological correlation-A tertiary care centre experience. *J Evid Based Med Healthc* 2016;3:2937-2940.
2. Sharma S, Makaju R, Dhakal R, Purbey B, Gurung RB, Shrestha R. Correlation between endoscopic and histopathological findings in gastric lesions. *Kathmandu Univ Med* 2015;51:216-219.
3. Hussain SI, Reshi R, Akhter G, Beigh A. Clinicopathological study of upper gastrointestinal tract endoscopic biopsies. *Int J Cur Res Rev* 2015;7:78-85.
4. Islam SMJ, Ahmed ASMM, Ahamad MSU, Hafiz SAMMA. Endoscopic and histologic diagnosis of upper gastrointestinal lesions, Experience in Port city of Bangladesh. Chattagrammaa-O-Shishu hospital. *MCI* 2014;13:11-14.
5. Rashmi K, Horakerappa MS, Karar A, Mangala G. A study on histopathological spectrum of upper gastrointestinal tract endoscopic biopsies. *IJMRHS* 2013;2:418-442.
6. Gulia SP, Chaudhary M, Noorunnisa N, Balagurunathan K. Interpretation of upper gastrointestinal tract mucosal biopsies-A study conducted in teaching hospital in Puducherry, India. *Int J Med Health Sci* 2012;3:17-24.

7. Sheikh BA, Hamdani S, Malik R. Histopathological spectrum of lesions of upper gastrointestinal tract-A study of endoscopic biopsies. *GJMEDPH* 2015;4:1-8.
8. Jawalkar S and Arakeri SU. Role of endoscopic biopsies in upper gastrointestinal diseases. *RJPBCS* 2015;6:977-983.
9. Pun CB, Aryal G, Basyal R, Shrestha S, Pathak T, Bastola S. Histopathological pattern of esophageal cancer at BP Koirala cancer hospital in Nepal: A three year retrospective study. *J Pathol Nepal* 2012;2:277-281.
10. Menon F, Baloch K, Memon AA. Upper gastrointestinal endoscopic biopsy: Morphological spectrum of lesions. *Professional Med J* 2015;22: 1574-1579.

How to cite this article: Rani D, Bhuvan S, Gupta A. A study of morphological spectrum of upper gastrointestinal tract lesions by endoscopy and correlation between endoscopic and histopathological findings. *Indian J Pathol Oncol* 2019;6(1):28-34.