

Fungal rhinosinusitis: A clinicomorphological study in a tertiary institute

G. Anushuya¹, Aja Chandramohan^{2,*}, Ponnusamy Karkuzhali³, Manickam Saraswathi⁴

^{1,2}Assistant Professor, ³Professor and HOD, ⁴Professor, Dept. of Pathology, ^{1,3,4}Sree Balali Medical College & Hospital, Tamil Nadu, ²Government Medical Mohan Kumaramangalam Medical College, Tamil Nadu, India

*Corresponding Author: Aja Chandramohan

Email: anirudhaja6@gmail.com

Received: 28th June, 2018

Accepted: 28th July, 2018

Abstract

Introduction: There is a lack of proper landmark studies from South India on fungal rhinosinusitis. The varying clinical and histological presentations of fungal rhinosinusitis and lack of clinicopathological studies, prompted us to undertake this study.

Materials and Methods: This study conducted over a period of 7 years at Goshen Institute of pathology (Madras medical college) one of the renowned premier institutes of Pathology in India. A total of 738 cases of sinusitis have been reported over the 7 years study period. The patients were of the age group from 12 to 92 years. All clinical data was retrieved from the patients' record file to study the emerging trend of fungal rhinosinusitis in this population of India.

Result: A total of 738 cases were diagnosed as rhinosinusitis, of which 84 were of fungal etiology. It was observed in our study that the prevalence of fungal sinusitis is ~11.4%. Fungal rhinosinusitis was found to be little more common in male (55.3%). The age of patients ranged from 13yrs to 91yrs. The peak incidence was seen in 3rd to 5th decade of life.

Conclusion: The study conducted in a tertiary care institute in Tamil Nadu has shown that there is an increase in the incidence of fungal sinusitis. It is inferred from our study that the most common causative agent is mucormycosis followed by aspergillus. The prompt diagnosis of fungal rhinosinusitis is important due to the angio-invasive nature of the fungi requiring aggressive anti-fungal therapy.

Keywords: Allergic fungal rhinosinusitis - AFR - FRS - Mucormycosis - aspergillosis – Chromoblastomycosis.

Introduction

Acute / chronic rhinosinusitis affects approximately 20% of general population. Fungal rhinosinusitis (FRS) was once considered to be a rare disorder, but is now being identified and reported more frequently. In India this entity was considered to be prevalent only in northern regions but is now being reported from other parts of the country as well. A study by Sandeep Suresh et al in the year 2016 has found the prevalence of fungal rhinosinusitis in northern Tamil Nadu to be 30%.¹ A study conducted by Stammberger² showed 140 patients with massive fungal sinusitis from 1976-1985. According to a literature review, the highest incidence of allergic fungal rhinosinusitis was noted in Mumbai, India, as reported in the study by Ferguson.³ The environmental predisposing factors include cigarette smoking and atopy. The causative agents for rhinosinusitis can be fungi or bacteria. Bacterial rhinosinusitis is caused most frequently by coagulase-negative staphylococci followed by *Hemophilus influenzae*, *Staphylococcus aureus* and lastly *Streptococcus pneumoniae*. Fungi as a causative agent of sinusitis is increasing accounting for 5–10% of all CRS cases. Our study over a period of 7yrs has shown that fungal rhinosinusitis constituted 11.4% of all cases of rhinosinusitis. The organisms implicated in causing fungal rhinosinusitis are *Aspergillus* species, *Mucor*, *Rhizomucor*, *Absidia*, *Cunninghamella*, *Mortierella*, *Saksenaea* etc. It is observed that dematiaceous fungi is the most common cause of rhinosinusitis in the west while aspergillus is the most common cause of rhinosinusitis in India.

Materials and Methods

A prospective and retrospective analysis of rhinosinusitis cases reported in Goshen Institute of Pathology, Madras Medical College, over a period of 7 years were collected. The clinical details of 738 cases of sinusitis were retrieved from case files of ENT Department and Medical Record Board. For all the cases, we received FESS specimens, which were multiple, grey white to grey brown soft tissue fragments ranging from 0.5cc to 3 cc in aggregate. All these specimens were either all embedded or partially embedded, depending on the quantity and the samples were processed routinely, stained with H&E, followed by PAS stain and GMS stain for morphological identification of fungi.

Result

We have reported a total of 738 cases as rhinosinusitis, of which 84 were of fungal etiology. The age distribution of rhinosinusitis along with sex predilection from 2010 to 2016 is given in Chart 1. A total of 738 case have been reported over period of 7 years, including 408 males and 330 females. The age of patients ranged from 13yrs to 91yrs. It was inferred from our study that fungal rhinosinusitis is more common in males including 408 cases, constituting 55.3%, while females had a prevalence of 44.7%. The age group most commonly affected by rhinosinusitis was 2nd to 4th decade consisting of 50.2% of the total cases. The least common age group involved was 1st decade and 70yrs of age, together constituting~1.4% (10 cases). The data collected from our studies showed that the presenting symptoms was non-specific and variable like fever, facial or sinus pain and headache. It was observed from our study that the sites

involved in descending order of frequency were - pansinusitis maxillary sinusitis ethmoid sinusitis sphenoidal sinusitis frontal sinusitis as depicted in Chart 2. Involvement of more than one sinus was seen in 473 cases (64.1%), while isolated frontal sinus involvement was least common. Visual loss, proptosis, and periorbital edema were present in 2 patients. Deviated nasal septum was seen in 5 patients. Of the 738 cases of rhinosinusitis, it was found that patients presenting with polypoidal lesion was frequent, consisting of 70.3% of the cases and those presenting with non-polypoidal sinusitis was less common, constituting 29.7% of the cases as shown in Chart 3. Of all the cases of rhinosinusitis, a clinical diagnosis of fungal rhinosinusitis was made in 129 cases, of these fungi were demonstrated only in 58 cases (predictive value of 45%). Our study shows that the total number of cases with biopsy proven fungal sinusitis was 84, which consisted of 11.4% of cases. Of the 84 biopsy proven cases of fungal sinusitis, the prevalence of fungal sinusitis was more in men as compared to women consisting of 52 males and 32 female as shown in Chart 4. While rhinosinusitis was common in 2nd to 4th decade of life, it was found that fungal rhinosinusitis was observed to be common in 41-51 years of age (18 cases). 13 patients had polyp as clinical presentation accounting to 15.6% of biopsy proven fungal sinusitis cases. Paraffin embedded sections from those cases reported as fungal sinusitis were reviewed and the results compiled. The distribution of fungal sinusitis among various species is depicted in Chart 5. The commonest was found to be mucormycosis consisting of 57% of the cases, followed by Aspergillosis accounting to 39.5%. While Chromoblastomycosis, candidiasis and mixed fungal infection was rare constituting one case each and together consisting of 3.5% of the cases. Fig. 1 shows mucormycosis which shows the presence of broad aseptate hyphae with obtuse angle branching. Fig. 2 shows the presence aspergillosis which are seen as delicate, septate hyphae with acute angle branching. Fig. 3 shows chromoblastomycosis, which are seen as brown pigmented round structures (pigmented sclerotic bodies) which are descriptively referred to as "copper-pennies on plate appearance."

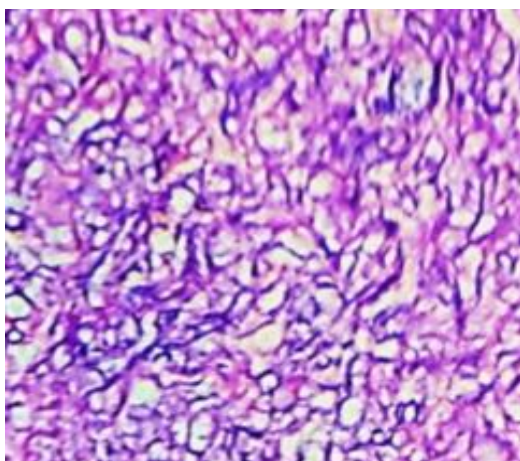


Fig. 1: Photomicrograph of mucormycosis in 40x (H& E stain)

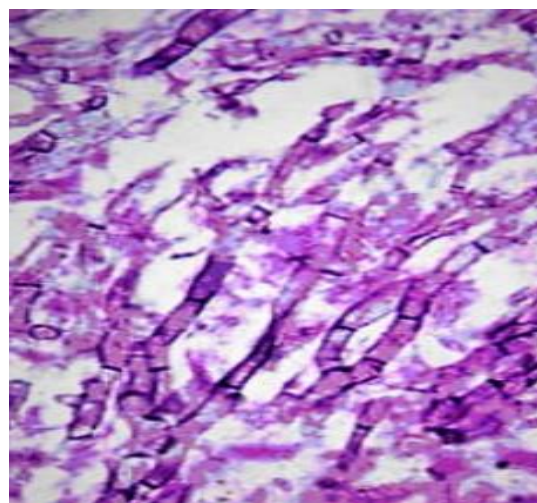


Fig. 2: Photomicrograph of aspergillus in 40x (H& E stain)

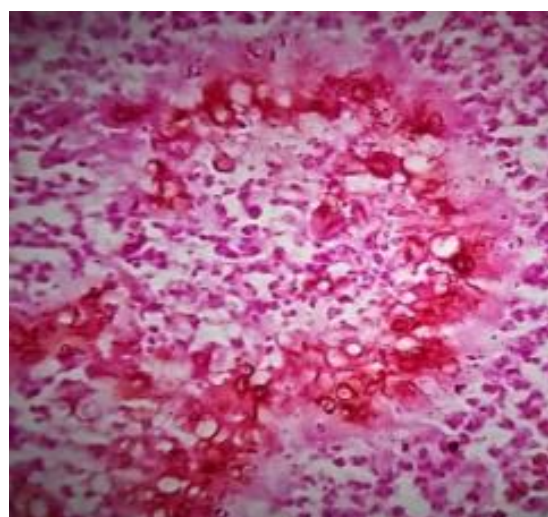


Fig. 3: Photomicrograph of chromoblastomycosis in 40x (H& E stain)

Chart 1: Total cases of rhinosinusitis with distribution among male and female

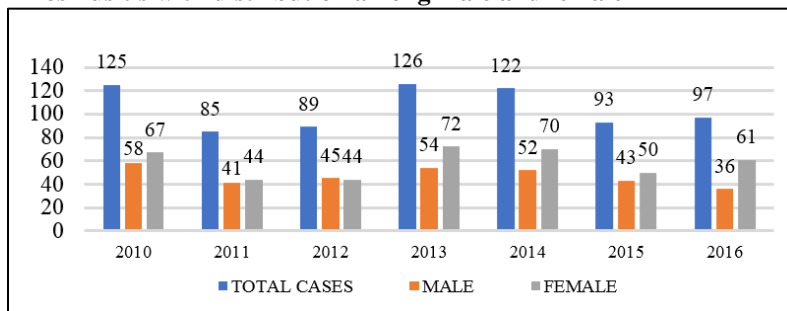


Chart 2: Site wise prevalence of rhinosinusitis

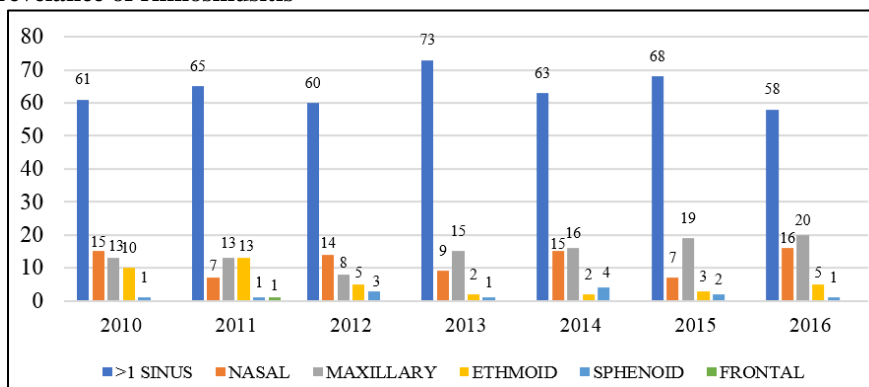


Chart 3: Polypoidal lesion vs non polypoidal sinusitis

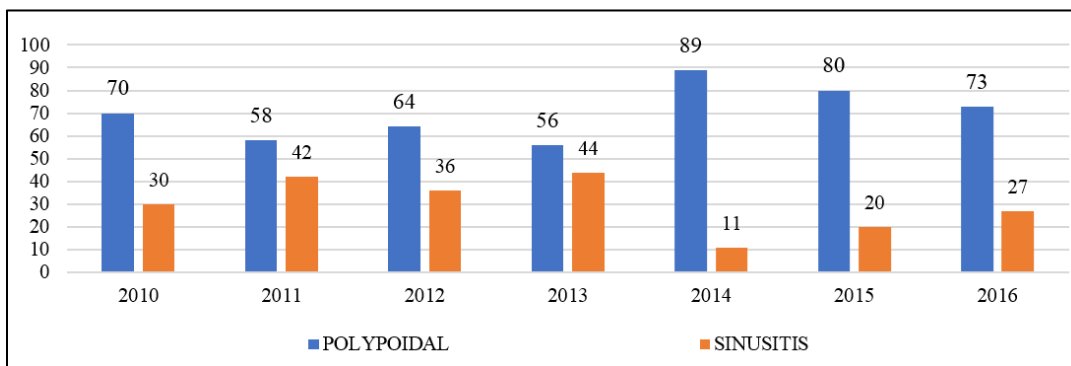


Chart 4: Male: female ratio in patients diagnosed with fungal sinusitis

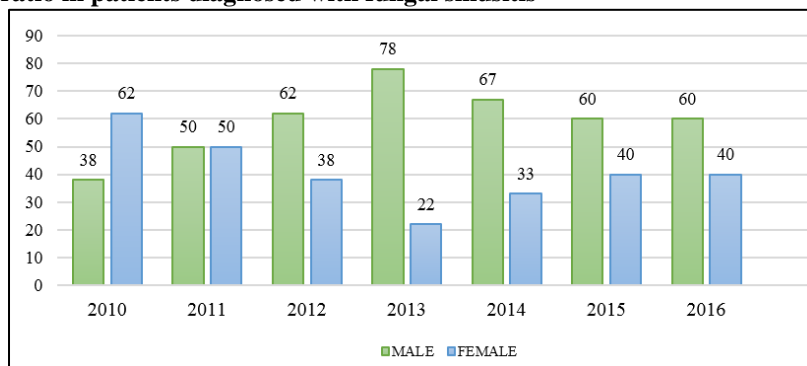
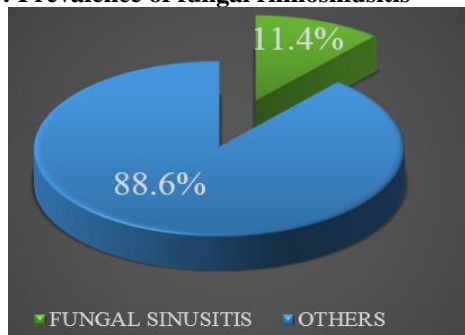
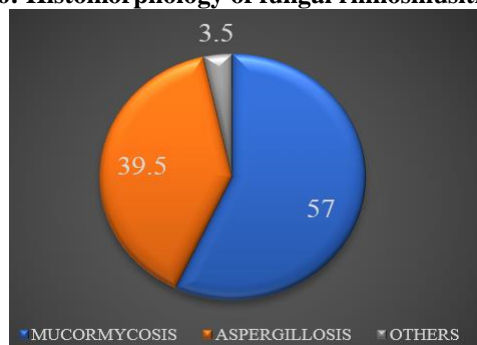


Chart 5: Prevalence of fungal rhinosinusitis**Chart 6: Histomorphology of fungal rhinosinusitis**

Discussion

It was in the 17th century that Sinonasal fungal disease was first described. There is a geographical diversity due to environmental factors, different climates. It has been elucidated that non - invasive disease is more common than invasive counterpart. Invasive disease is common in immunocompromised individuals. Hazarika et al.⁴ has reported 3 cases of rhinocerebral mucormycosis, in elderly diabetic patients. Chakrabarti et al.⁵ in north India reported 50 cases of fungal rhinosinusitis in a total of 119 patients of clinically suspected cases over a 2-year duration. Milosev et al.⁶ has interestingly found that *Aspergillus* rhinosinusitis was more frequently seen in male patients in their teens and twenties. Rhinosinusitis has been found to be affecting approximately 20% of the population. Anatomic abnormalities like deviated nasal septum, nasal polyposis, and foreign bodies in the nasal passage are well known predisposing factors for fungal rhinosinusitis. In our study, 517 cases diagnosed as sinusitis had nasal polyposis. Chronic indolent invasive fungal sinusitis is further divided into 2 types: chronic invasive fungal sinusitis, chronic invasive granulomatous sinusitis.⁸ According to Aribandi et al⁷ *Aspergillus fumigatus* is the most common causative of Chronic invasive fungal sinusitis. Fulminant fungal sinusitis with angioinvasion is seen in patients with hematologic malignancies, diabetes, those who are immunocompromised immunocompromised rarely in immunocompetent individuals. Of the biopsy proven fungal sinusitis cases in our study, 18 presented with polyposis. The most common causative fungal organism in India in other studies is *Aspergillosis*⁷ whereas in our study mucormycosis was found to be the most common causative organism. mucormycosis, in biopsy is seen as thick aseptate irregular

hyphae and obtuse angle branching¹⁰ while *Aspergillus* is uniform septate slender hyphae showing acute angle branching.¹⁰ *Chromoblastomycosis* is seen as pigmented sclerotic bodies frequently called as “copper pennies”. Fungal granuloma shows palisading macrophages along with foreign body type of giant cells. *Candida* shows spores with pseudohyphae.¹⁰ Non-invasive disease is treated by surgical debridement and sinus ventilation only, with or without local corticosteroid therapy in allergic type. In addition to the above measures invasive lesions needs to be treated with antifungal chemotherapy.

Conclusion

This study conducted in Tamil Nadu, in a tertiary care institution shows that there is an increase in the incidence of fungal sinusitis over the past few decades. Peak incidence of fungal sinusitis as observed our study is 40-50 years. The most common causative organism is mucormycosis sp. followed by *aspergillus* sp. From our study it has been inferred that only in half the cases, fungal infection could be clinically suspected and, in the rest, the histopathological examination contributed solely to the diagnosis. The prompt diagnosis of fungal rhinosinusitis especially mucormycosis and aspergillosis highly important due to the angioinvasive nature of the organisms, which necessitates critical alert to clinicians for prompt debridement and aggressive anti-fungal therapy.

References

1. Suresh, V. Prevalence and clinical profile of fungal rhinosinusitis. *Allergy Rhinol* 2016;7(2):e115-e120.
2. Stammberger H. Endoscopic surgery for mycotic and chronic recurring sinusitis. *Ann Otol Rhinol Laryngol* 1985;Suppl119:1-11.
3. Ferguson BJ. Fungus balls of the paranasal sinuses. *Otolaryngol Clin North Am* .(2000). 33:389-398.
4. Kathleen T. Montone; Infectious Diseases of the Head and Neck: A Review, *Am J Clin Pathol* 2007;128(1):35-67.
5. Hazarika P, Ravikumar V, Nayak RG, Rao PS, Shivananda PG. Rhinocerebral mycosis. *Ear Nose Throat J* 1984;63:464-468.
6. Chakrabarti A, Sharma SC, Chandler J. Epidemiology of pathogenesis of paranasal sinus mycoses. *Otolaryngol Head Neck Surg* 1992;107:745-750.
7. Michael RC, Michael JS, Ashbee RH, Mathews MS. Mycological profile of fungal sinusitis: An audit of specimens over a 7-year period in a tertiary care hospital in Tamil Nadu. *Indian J Pathol Microbiol* 2008;51(4):493-496.
8. Manohar Aribandi, MD, Victor A. McCoy, MD and Carlos Bazan. Imaging Features of Invasive and Noninvasive Fungal Sinusitis: A Review. *Radio Graphics* 2007;27:1283-1296.
9. Ravikumar, A., Mohanty, S., Vatsanath, R. P., & Raghunandhan, S. Allergic fungal sinusitis— A clinicopathological study. *Indian J Otolaryngol Head Neck Surg* 2004;56(4):317-320.
10. Stacey E Mills. Sternberg's Diagnostic Surgical Pathology, 5th Edition. 2010. Chapter 21. p861-862.

How to cite this article: Anushuya G, Chandramohan A, Karkuzhali P, Saraswathi M. Fungal rhinosinusitis: A clinicomorphological study in a tertiary institute. *Indian J Pathol Oncol* 2019;6(1):35-38.