

Histopathological spectrum of renal tumors in nephrectomy specimens

Madhu Kumar R¹, Meghana P^{2,*}, Vidya Vasudev³, Bharathi M⁴

^{1,3}Assistant Professor, ²Post Graduate Student, ⁴Professor and HOD, Dept. of Pathology, ¹Sambhram Institute of Medical Sciences, Karnataka, ²⁻⁴Mysore Medical College and Research Institute, Mysore, Karnataka, India

***Corresponding Author: Meghana P**

Email: meghanap.mp@gmail.com

Received: 13th July, 2018

Accepted: 7th October, 2018

Abstract

Introduction: Kidneys are the vital organs of the body which are having multiple functions. The benign or malignant diseases of the kidney result in total organ removal. Renal tumors comprises a wide spectrum of neoplastic lesions with patterns that are distinct for children and adults. In India management of chronic kidney diseases is a great challenge as the dialysis and kidney transplantations are expensive.

Objectives: To study histopathological features of various renal tumors in nephrectomy specimens and to determine the age and sex distribution in various renal tumors

Materials and Methods: The study was done in Mysore medical college and research institute. Total 14 nephrectomy cases were studied in a period of 2 years from 2015 to 2017.

Results: Total 14 renal tumors were studied. In which RCC is the most common -10 cases, followed by SCC and Angiomyolipoma, 2 cases each. Most of the patients presented in age group of 4th to 5th decade with male to female ratio of 1.16:1. Histologically RCC-clear cell type was the most common subtype

Conclusion: RCC is the most common renal tumors in which clear cell type is most common subtype.

Keywords: Renal tumors, Renal cell carcinoma, Clear cell carcinoma.

Introduction

Kidneys are the vital organs of the body which are having multiple functions.

Their main function is not only excretion but they also maintain water and salt metabolism along with acid base balance, they are going to maintain the blood pressure through renin-angiotensin mechanism and hematopoiesis by producing erythropoietin.¹ Like other organs in human body, kidneys also involved by many benign or malignant diseases which requires total organ removal. Simple nephrectomy is done to remove non functioning kidneys which are irreversibly damaged by different benign pathological conditions and On the other hand for different malignant conditions of the kidney radical nephrectomy is indicated.² Renal tumors comprise a wide spectrum of neoplastic lesions with patterns that are distinct for children and adults. A wide variety of benign and malignant tumors arises from the renal parenchyma.³ Surgery remains the standard of treatment for localised RCC. Nephron sparing surgery is favoured for small, organ-confined tumors. New techniques, such as cryoablation and radiofrequency ablation which are minimally invasive, have shown good results and the follow-up is still short.⁴

Materials and Methods

This is a cross section study undertaken in the department of pathology, Mysore Medical College and Research Institute for duration of 18 months from December 2015 to May 2017. A total number of 50 cases were studied.

Detailed clinical history of the patients were collected while receiving the specimen and by checking the medical records. All nephrectomy specimens were fixed in 10% formalin and then subjected to gross examination, noting the

size, appearance, external surface and cut surface. Representative bits were taken, processed and stained with routine Hematoxylin and Eosin and other special stains wherever required. All sections were studied and clinicopathological evaluation of nephrectomy specimens were done. Tumors were further classified according to 2016 WHO classification.

Results

This study is done in Mysore Medical College and Research Institute where total of 14 cases of renal tumor were studied. Renal cell carcinoma (RCC) was the commonest tumor seen in the present study and was found to be frequent in 4th and 5th decade. It comprised of 20% (10/50) of all the renal lesions and 71.4% (10/14) of the neoplastic lesions of the kidney. Two cases of squamous cell carcinoma and angiomyolipoma were seen each comprised of 14.3% each. Squamous cell carcinoma was seen in the 4th and 5th decade. Angiomyolipoma was seen in 3rd and 4th decade.

Table 1 shows the frequency of neoplastic lesions in relation to sex. Renal cell carcinoma was equally distributed in both sex (male: female ratio- 1:1). Two cases of squamous cell carcinoma was seen in male. Two cases of Angiomyolipoma was seen in female.

Table 2 illustrates the macroscopic features of the kidney in renal cell carcinoma. Kidney was enlarged in all cases. The most frequent finding was the presence of haemorrhagic and necrotic areas. Cystic degeneration was present in 50% of the cases.

Table 3 illustrates the frequency of various histological variants of renal cell carcinoma The most common subtype encountered was clear cell type comprising of 5 out of 10

cases of RCC followed by papillary variant which comprises of 4 cases. Chromophobe variant was seen in 1 case.

Table 4 shows the microscopic features of renal cell carcinoma. In clear cell RCC out of 5 cases 3 cases exhibited Fuhman nuclear grade 3 and 2 cases shows Fuhman nuclear grade 2. Chromophobe RCC exhibits Fuhman nuclear grade 2. In Papillary RCC out of 4 cases 3 exhibits Fuhman nuclear grade 4 and 1 case exhibits Fuhman nuclear grade 3. One case of papillary RCC showed lymphatic infiltration.

Squamous Cell Carcinoma: Two case of SCC is were seen. Grossly both are enlarged, tumor proper seen which is involving almost entire kidney, areas of haemorrhage and necrosis is seen. Microscopically squamoid cells with increased N:C ratio, prominent nucleoli and moderate amount of cytoplasm. Also seen are areas of necrosis.

Angiomyolipoma: One case of classical and one case of epitheloid Angiomyolipoma. Grossly both were enlarged, cut section shows multiple yellowish areas. Microscopically fatty tissue, blood vessels and muscle component seen in both the cases. Epitheloid cells are seen in epitheloid variant of angiomyolipoma.

Table 5 shows that majority of the RCC were presented in Stage I (50%, 5/10), followed by Stage II (40%, 4/10) and 1 case in stage III. 2 cases of SCC is in stage II.

Table 6 shows the clinical presentation neoplastic lesions:

RCC: All cases presented with pain abdomen and haematuria. 8 cases were with mass per abdomen

SCC: There was 2 cases of SCC who presented with pain abdomen, mass per abdomen and hematuria.

Angiomyolipoma: There were 2 cases both the cases presented in pain abdomen and 1 case presented with mass per abdomen and haematuria.

Table 4: Microscopic features of renal cell carcinoma

	Clear cell carcinoma	Chromophobe carcinoma	Papillary carcinoma
Clear cells	05		
Granular cells	05		
Papillary areas	01		4
Raisinoid nucleus		1	
Furhman nuclear grade			
1			
2	02		
3	03	01	01
4			03
Areas of haemorrhage and necrosis	05	01	04
Evidence of capsular infiltration	00	00	00
Evidence of Renal vein infiltration	00	00	00
Evidence of lymphatic infiltration	00	00	01
Evidence of adrenal involvement	00	00	00

Table 1: Frequency of neoplastic lesions of the kidney in relation to sex

Neoplastic Lesions	Male	Female	No. of Cases
Renal cell carcinoma	5	5	10
Squamous cell carcinoma	2	0	2
Angiomyolipoma	0	2	2
Total	7	6	14

Table 2: Gross features of the kidney in renal cell carcinoma

Gross findings	Number of cases
Enlargement	10
Capsular Infiltration	00
Areas of haemorrhage	10
Areas of necrosis	10
Areas of cystic degeneration	05
Evidence of adrenal involvement	00
Non-neoplastic kidney	00

Table 3: Frequency of the various histological variants of renal cell carcinoma

Histological variants	No. of Cases	Percentage (%)
Clear cell RCC	5	50%
Chromophobe RCC	1	10%
Papillary RCC	4	40%
Total	10	100

Table 5: Staging of malignant tumors of the kidney

Tumor	Stage	No. of Cases
TNM Staging (AJCC Cancer, 7 th Edition)		
Renal Cell Carcinoma	I	5
	II	4
	III	1
	IV	
Squamous cell Carcinoma	I	
	II	2
	III	
	IV	

Table 6: Clinical features of neoplastic lesions

Clinical features	RCC	SCC	Angiomyolipoma
Pain abdomen/Flank pain	10	02	02
Mass per abdomen	08	02	01
Pain abdomen + mass per abdomen	08	02	01
Haematuria	10	02	01

Discussion

Histopathology is an important and useful learning tool in the hands of pathologists to study the spectrum of diseases.

Radical nephrectomy (RN) was first described by Robson in 1963, it has been described as the standard surgical treatment of kidney cancer.⁵

In this study Renal cell carcinoma is most common renal tumor which is similar to Aiffa Aiman et al⁶ and Ngairangbam S et al⁷

S No.	Authors	Clear cell type	Papillary cell type	Chromophobe type	Sarcomatoid type
1	Mahesh kumar et al ⁸	57.19%(4)	14.2%(1)	14.2%(1)	14.2%(1)
2	Shaila et al ¹	58.3%(7)	33.33%(4)	8.3%(1)	-
3	Present study	50%	40%	10%	-

Out of 10 cases most of i.e., 50% cases were clear cell type RCC followed by papillary cell RCC, 40% and 10% of chromophobe RCC. Which is Shaila et al¹ where most common type is clear cell type RCC (58.3%).2 case of squamous cell carcinoma is seen in one case of squamous cell carcinoma is seen in Aiffa Aiman et al⁶.

Angiomyolipoma

In this study there are 2 cases (4% of total nephrectomy and 14.28% of neoplastic lesion) of Angiomyolipoma with

female predominance all the 2 cases were seen in females and of age 35 and 50years. In this one is classical and another is epithelioid angiomyolipoma Microscopically, the tumors were composed of mature adipose tissue, tortuous thick-walled blood vessels and bundles of smooth muscle that seem to emerge from the vessel walls which were in accordance with the literature review.

In a study done by Shaila et al¹ and Aiman A et al¹¹ 1.87% and 0.7% with female predominance.

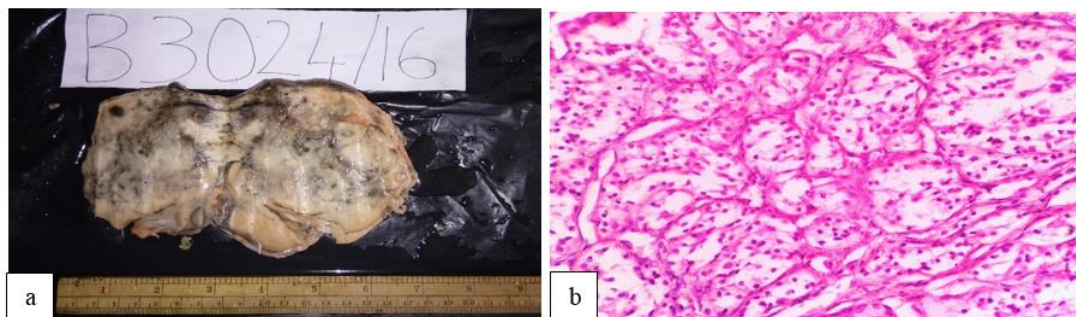


Fig. 1a: Gross specimen of Clear cell RCC, cut section shows grey white area which is involving entire kidney; **1b:** Microscopy section shows groups of tumor cells characterised by round to oval shape and the nucleus have irregular outlines and prominent nucleoli (H & E, 40X)

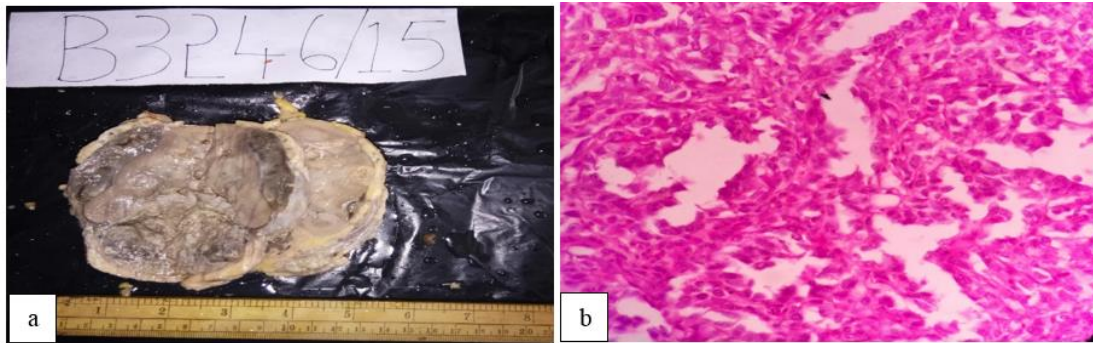


Fig. 2a: Gross specimen of papillary RCC, cut section shows grey white tumor proper involving entire kidney. Also seen papillary like growth; **2b:** Microscopy of papillary RCC, section shows tumor cells arranged papillary pattern separated by delicate, intricately branching fibrovascular septae. (H & E, 40X)

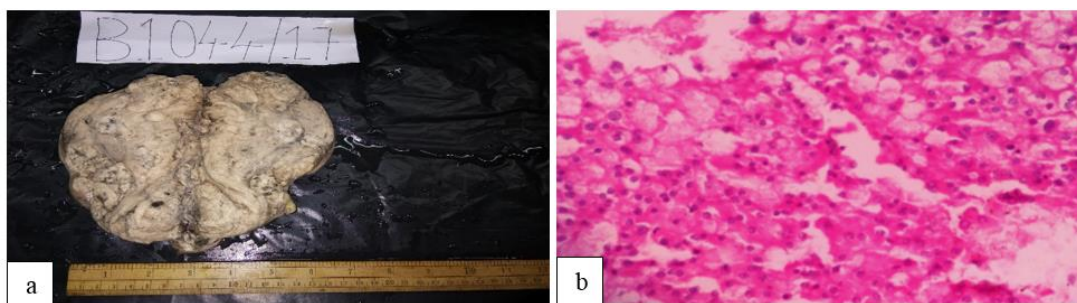


Fig. 3a: Gross specimen of Chromophobe RCC, cut section shows grey white ill-defined growth involving entire kidney; **3b:** Microscopy: Section shows groups of tumor cells acinar growth pattern with individual cells showing clear to eosinophilic flocculent cytoplasm and few of them have perinuclear halos (H & E, 40X).

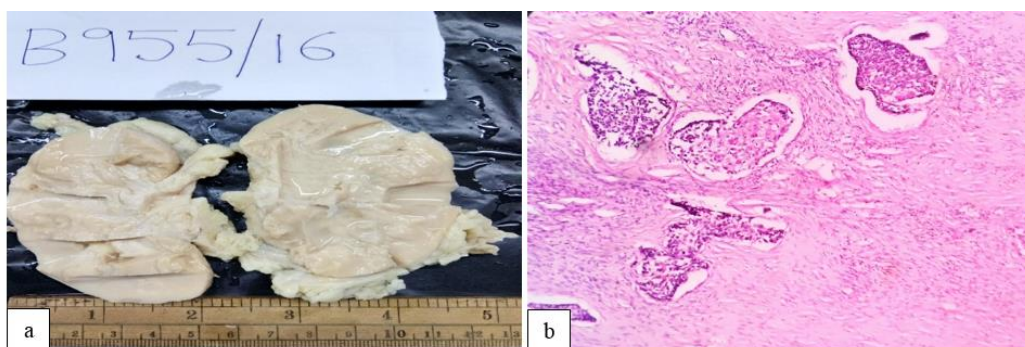


Fig. 4a: Gross specimen of Squamous cell carcinoma with cut surface showing grey white; **4b:** Microscopy of SCC shows pleomorphic squamoid cells. (H & E, 10X)

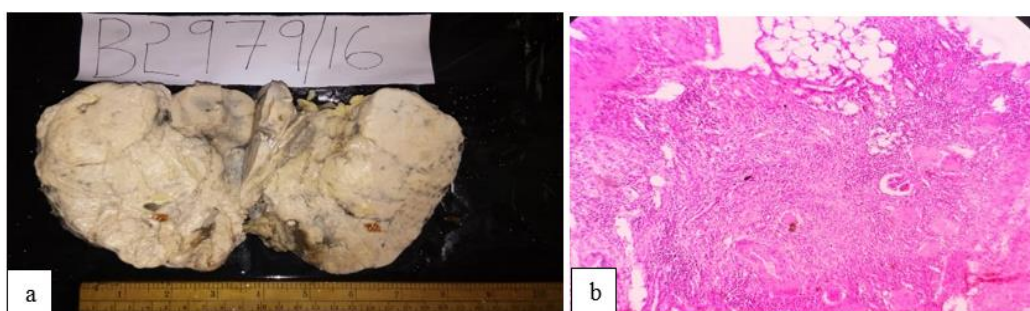


Fig. 5a: Gross specimen of Angiomyolipoma showing enlarged with cut surface showing grey white and yellowish areas; **5b:** Microscopy of Angiomyolipoma shows all three component i.e., adipose tissue, blood vessels and spindle cells. (H & E 10X)

Conclusion

Renal cell carcinoma was the commonest renal tumor encountered followed by SCC and Angiomyolipoma, 2 cases each. The most common presenting feature of Renal cell carcinoma was pain abdomen and hematuria followed by mass per abdomen. Most commonly affected males were in age group of 4 -5th decade.

Conflict of Interest: None.

References

1. Shaila, Nityananda B. S, Tamil Arasi. Spectrum of Lesions in Nephrectomy Specimens in Tertiary Care Hospital. *J Evol Med Dent Sci* 2015;4(73):12714-12726.
2. Datta B, Moitra T, Chaudhury DN, Halder B. Analysis of 88 nephrectomies in a rural tertiary care center of India. *Saudi J Kidney Dis Transpl* 2012;23:409-413.
3. Bashir N, Bashir N, Shah P, Bhat N, Salim O, Nuzhat. Histopathological study of renal tumors in resected nephrectomy specimens – an experience from tertiary care centre. *Natl J Med Res* 2015;5(1)26-29.
4. Terrone C, Volpe A. The Role of Pathology for Clinical Decision-Making in Renal Cell Carcinoma is increasing. *Eur Urol* 2007;51:1166–1170.
5. Najjar MS, Bhat MA, Wani IA, Bandy KA, Reshi AR, Daga BA et al. Profile of renal tuberculosis in 63 patients. *Indian J Nephrol* 2003;13: 104-107.
6. Aiman A, Singh K, Yasir M. Histopathological spectrum of lesions in nephrectomy specimens: A five year Experience in a tertiary care hospital. *J Sci Soc* 2013;40:148-154.
7. Ngairangbam S, Konjengbam R. Histopathological spectrum of non-neoplastic & neoplastic lesions in nephrectomy specimens. *J Evid Based Med. Healthc* 2016;3(16):627-629. DOI: 10.18410/jebmh/2016/143.
8. Mahesh Kumar U., Yelikar BR., Girija Patil, Mahesh H Karigoudar, Pankaj Pande and Patil SB. Spectrum of Histopathological lesions in Nephrectomy specimens – A two year study in a tertiary care hospital. *Int J Res Pharm Biomed Sci* 2012;3(4):1787-1790.

How to cite this article: Kumar MR, Meghana P, Vasudev V, Bharathi M. Histopathological spectrum of renal tumors in nephrectomy specimens. *Indian J Pathol Oncol* 2019;6(1):52-56.