

## Study of expression of vascular endothelial growth factor and histomorphological correlation in colorectal malignancies

Adil S. A. K<sup>1</sup>, Sharath Kumar H. K<sup>2,\*</sup>, Chaithra M. S<sup>3</sup>, Bharathi M<sup>4</sup>

<sup>1</sup>Assistant Professor, <sup>2</sup>Professor, <sup>3</sup>Post Graduate Student, <sup>4</sup>HOD, Dept. of Pathology, Mysore Medical College and Research Institute, Mysore, Karnataka, India

\*Corresponding Author: Sharath Kumar H. K

Email: sharutanu1748@gmail.com

Received: 28<sup>th</sup> March, 2018

Accepted: 16<sup>th</sup> July, 2018

### Abstract

**Introduction:** Colorectal cancer is the most common cancer of gastrointestinal tract. It is ranked fourth in causing cancer related deaths. Compared to western world, the incidence rates are low in India. The pathogenesis involved here is tumor induced angiogenesis which is the most important factor for tumor growth, invasion and metastasis. Vascular endothelial growth factor (VEGF) is known to play a major role in angiogenesis.

**Aim:** Is to study the expression of VEGF in colorectal malignancies and correlate the expression with histomorphological findings.

**Materials and Methods:** Tissue samples from 30 patients with colorectal cancer of various stages, who had undergone resection during May 2016- February 2018, were taken for the study. Out of 30 cases, 27 were of Adenocarcinoma, 2 were Neuroendocrine tumors and 1 was Rectal Gastrointestinal stromal tumor. Scoring system was applied to assess the VEGF expression.

**Results:** Patients with stage 1, well differentiated and grade 1 tumors had predominantly score 2 of VEGF expression; patients with stage 2, grade 2 and moderately differentiated tumors with mucinous component had predominantly score 3 of VEGF expression and patients with stage 3, grade 3 and poorly differentiated tumors had predominantly score 4 of VEGF expression. Thus VEGF expression was positively correlated with tumor grade, and TNM stage ( $p < 0.05$ ).

**Conclusion:** Quantification of VEGF expression in colorectal cancers may give a reliable prognostic information, which could further help in selecting patients of high risk of disease progression for adjuvant therapy.

**Keywords:** Colorectal cancer, Angiogenesis, VEGF expression.

### Introduction

Colorectal cancer (CRC) is the most common cancer of gastrointestinal tract. It is ranked fourth in causing cancer related deaths. Compared to western world, the incidence rates are low in India.<sup>1</sup> CRC incidence is generally higher in men; and the risk increases with age as the majority of cases are diagnosed in patients older than 50 years.<sup>2</sup> Furthermore, many other factors have been known to contribute significantly in the increased incidence of CRC. These factors include geographical variation, family history, diet, chronic inflammatory disease and polyposis syndrome.<sup>3-7</sup>

Vascular network is crucial for tumors to grow as well as for their metastasis. The cancer cells, without blood circulation, can grow only up to 1-2mm but not beyond. Hence tumors prompt the growth of host blood vessels, a process called angiogenesis, which is necessary for adequate supply of oxygen and nutrients to the cancer cells. Therefore angiogenesis is the basic pathogenic step for the progression of cancer.<sup>8</sup>

Angiogenesis is controlled by production of several growth factors and growth inhibitors.<sup>9</sup> In this respect several growth factors have been recognized as angiogenesis activators including vascular endothelial growth factor (VEGF), basic fibroblast growth factor (bFGF), transforming growth factor alpha (TGF- $\alpha$ ), transforming growth factor beta (TGF- $\beta$ ), epidermal growth factor (EGF) etc. The VEGF family of receptors are known to play a major role in tumor vascularization. VEGF is a potent

angiogenic agent in cancer tissues as well as normal tissues.<sup>10</sup>

VEGF belongs to the platelet derived growth factor (PDGF) family.<sup>11</sup> There are six types of VEGF: VEGF-A, B, C, D, E and F. The action of VEGF protein is mainly on the vascular endothelial cells.<sup>12-14</sup>

Enhanced expression of VEGF has been found in several tumors including colorectal cancers and it may be linked to an advanced stage of the disease or may predict a potential metastatic risk.

Several studies done on VEGF expression in CRC have revealed that VEGF expression correlates with stage of disease and histological grade of tumor. Thus an attempt was made to study the expression of VEGF in colorectal cancer patients and correlate its expression with histopathological findings, which could be helpful to use VEGF as prognostic indicator and also could be helpful to select the patients who may benefit from adjuvant treatment including new therapeutic strategies in the future.

### Materials and Methods

The specimens of tumors from the patients who had undergone resection for CRC, were collected from the department of pathology, Mysore Medical College and Research Institute, during the year May 2016- February 2018. All types of colorectal malignancies were included in the study. Biopsy specimens and cases where there is extensive tumor necrosis without viable tumor cells for accurate evaluation of the immunohistochemistry were

excluded from the study. The detailed clinical history including the age, gender and results of relevant investigation done was collected from the patient's case records. In every case the standard protocol for surgical grossing of resected specimens was followed. After conventional processing, paraffin sections of 5µm thickness were stained by Haematoxylin and Eosin for histopathological study. In addition, 4µm sections were cut from the paraffin block of tumor tissue and was taken on the glass slide coated with Poly-L-Lysine (PLL) for immunohistochemistry to detect VEGF expression.

The tumours were classified as per the prescribed WHO classification. The typology followed based on histological findings was classical, signet ring and mucinous variants. The grading of classical type tumors (well, moderately and poorly differentiated) was also determined.

### Immunohistochemical Staining

Sections of 4µm thickness were made and taken on poly-L-Lysine (PLL) coated slides. Immunohistochemistry for VEGF expression was performed on tissue sections using VEGF rabbit polyclonal antibody that recognizes cytoplasmic VEGF in paraffin embedded tissue.

Heat antigen retrieval was done by using pressure cooker for VEGF rabbit polyclonal antibody and standard immunohistochemistry procedure was conducted as per the manufacturer's (Biogenex) manual of instructions. Placenta was used as positive tissue control.

### Evaluation of VEGF expression

The criterion for a positive immune reaction was a dark brown cytoplasmic precipitate. The intensity of the staining was assessed quantitatively by counting the percentage of positively stained cells out of 100 malignant cells at 40 total magnification for atleast 20 fields and qualitatively as dense and faint staining.

A four scaled scoring system was chosen in this study.<sup>16</sup>

Score 0 = Negative, None of the cells stained positive of tumor cells.

Score 1 = Weak or mild staining, 5%-10% of tumor cells stained positive.

Score 2 = Moderate staining, 10-25% of tumor cells stained positive.

Score 3 = Strong staining, 25-50% of tumor cells stained positive.

Score 4 = Highly strong staining, i.e more than 50% of tumor cells stained positive.

### Statistical Analysis

The data was collected, statistically evaluated and represented in terms of frequency distribution tables. The categorical and counting variables were presented by frequencies and percentages. The proportion of subjects revealing the expression according to the various subgroups such as age, gender, type of cancer, grade and stage was estimated. The differences in frequency of expression between various subgroups were tested for statistical significance by employing chi Square /Fischer test. P score of  $\leq 0.05$  was considered statistically significant.

### Results

Tissue samples from 30 patients with colorectal cancer of various stages, who had undergone resection during May 2016- February 2018, were taken for the study. Out of 30 cases, 27 were of Adenocarcinoma, 2 were neuroendocrine tumor and 1 was Rectal Gastrointestinal stromal tumor. Scoring system was applied to assess the VEGF expression. VEGF expression was positively demonstrated in all 30 cases but the degree of expression varied from case to case. It was more intense (score 4) in poorly differentiated, grade 3 and Stage III tumors than in other subtypes.

Strong positive statistical correlation was found between VEGF expression and grade and stage of the colorectal tumors ( $p < 0.05$ ) (Table 2 & 3). On the other hand, VEGF expression showed no statistical correlation with age and sex of the patient ( $p > 0.05$ ) (Table 4 & 5). Histological type and site of the tumors also showed no statistical correlation with VEGF expression ( $p > 0.05$ ) (Table 1 & 6).

**Table 1: VEGF expression in relation to histological types**

S. No.	Histological type of CRC	VEGF Score						Total-30	%
		Score 0	Score 1	Score 2	Score 3	Score 4			
1.	Well differentiated adenocarcinoma	-	2	09	5	1	17	56.6	
2.	Well differentiated adenocarcinoma with mucinous component	-	-	-	1	-	1	3.3	
3.	Moderately differentiated adenocarcinoma	-	-	1	1	1	3	10	
4.	Moderately differentiated adenocarcinoma with mucinous component	-	-	-	2	1	3	10	
5.	Poorly differentiated adenocarcinoma tumors	-	-	-	-	2	2	6.6	
6.	Signetring cell	-	-	-	1	-	1	3.3	

	adenocarcinoma							
7.	Neuroendocrine tumor	-	-	1	1	-	2	6.6
8.	Rectal Gastrointestinal stromal Tumor	-	-	1	-	-	1	3.3
P : 0.322 (P>0.05)								

**Table 2: VEGF expression in relation to grade of the tumor**

S. No.	Grade	VEGF Score						Total-30	%
		Score 0	Score 1	Score 2	Score 3	Score 4			
1.	Grade 1	-	2	11	1	-	14	46.6	
2	Grade 2	-	-	1	10	1	12	40.0	
3	Grade 3	-	-	-		4	4	13.3	
P : 0.001 (P<0.05)									

**Table 3: VEGF expression in relation to stage of the tumor**

S. No.	TNM Stage	VEGF Score						Total-30	%
		Score 0	Score 1	Score 2	Score 3	Score 4			
1.	Stage 1	-	2	8	3	-	13	43.3	
2	Stage 2	-	-	4	7	2	13	43.3	
3	Stage 3	-	-	-	1	3	4	13.3	
P : 0.01 (P<0.05)									

**Table 4: VEGF expression in relation to age distribution**

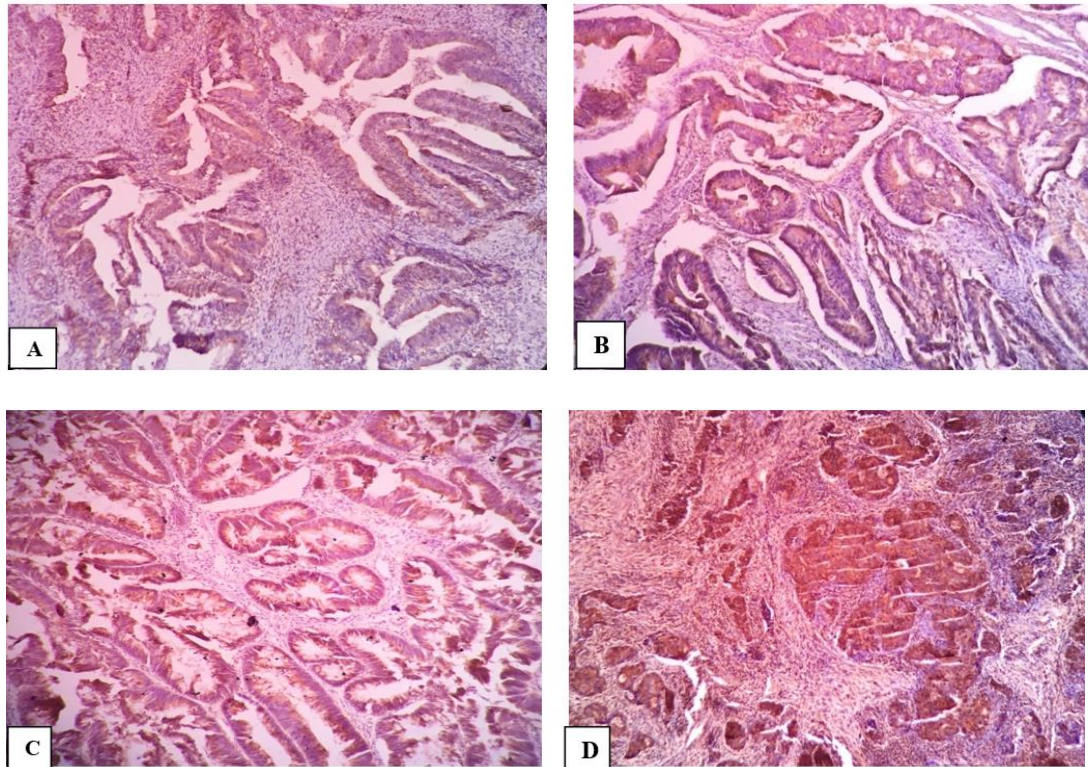
S. No.	Age	VEGF Score						Total-30	%
		Score 0	Score 1	Score 2	Score 3	Score 4			
1.	<40yrs	-	-	-	1	-	1	3.3	
2.	41-50yrs	-	1	4	5	1	11	36.7	
3.	51-60yrs	-	-	4	2	1	7	23.3	
4.	61-70yrs	-	1	4	2	1	8	26.7	
5.	71-80yrs	-	-	-	1	2	3	10	
P : 0.572 (P>0.05 )									

**Table 5: VEGF expression in relation to gender of the patient**

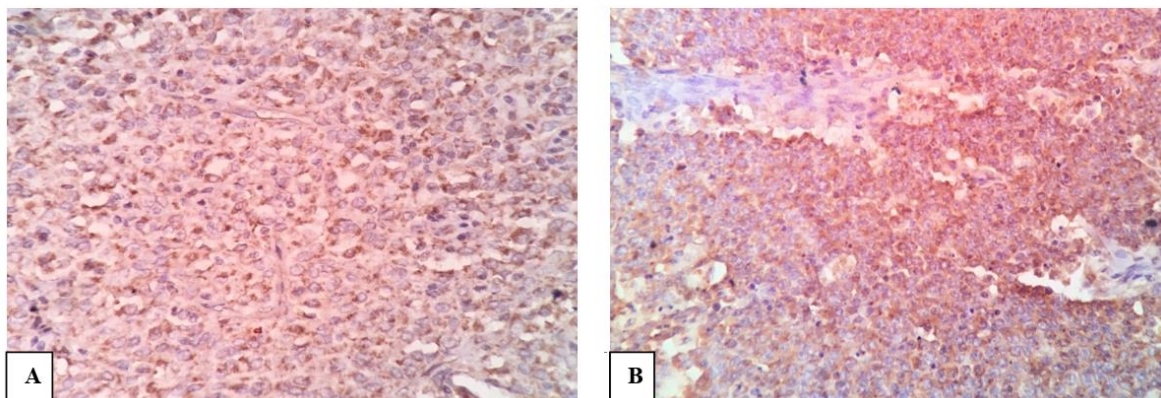
S. No.	Gender	VEGF Score						Total-30	%
		Score 0	Score 1	Score 2	Score 3	Score 4			
1.	Female	-	1	5	6	2	14	46.6	
2.	Male	-	1	7	5	3	16	53.3	
P : 0.920 (P>0.05 )									

**Table 6: VEGF expression in relation to site of the tumor**

S. No.	Site	VEGF Score						Total -30	%
		Score 0	Score 1	Score 2	Score 3	Score 4			
1.	Transverse colon	-	-	1	-	-	1	3.3	
2.	Sigmoid / Rectosigmoid	-	-	3	2	-	5	16.6	
3.	Ascending colon	-	-	2	-	2	4	13.3	
4.	Anus	-	-	-	-	1	1	3.3	
5.	Rectum	-	2	5	8	2	17	56.6	
6.	Caecum	-	-	1	1	-	2	6.6	
P : 0.438 (p>0.05)									



**Fig. 1:** Photomicrograph of IHC staining of VEGF expression; A): Score 1 of VEGF expression in well differentiated adenocarcinoma; B): Score 2 of VEGF expression in well differentiated adenocarcinoma; C): Score 3 of VEGF expression in moderately differentiated adenocarcinoma; D): Score 4 of VEGF expression in poorly differentiated adenocarcinoma



**Fig. 2:** Photomicrograph of IHC staining of VEGF expression. A): Score 2 of VEGF expression in Rectal Gastrointestinal Stromal tumor; B): Score 3 of VEGF expression in neuroendocrine tumor of caecum

### Discussion

The important findings of the present study are discussed in the succeeding paragraphs.

VEGF expression was significantly demonstrated in poorly differentiated, grade 3 and advanced stage tumors and it implied poor prognosis in patients with CRC. This prospective study was conducted to assess VEGF immunohistochemical reactivity in colorectal malignancies and to analyze the relation between its expression and pathological characteristics and prognosis.

Basically, there were 30 cases in the present study out of which were 16 male and 14 female patients. The age distribution of the patients included in the study ranged from 35 to 80 years with an average age of 55 years. Similar age range was seen in Patil et al study, who reported average age of CRC patients in India as  $47 \pm 5$  years.<sup>17</sup> In the present study of 30 patients, only one patient was aged below 40 years; 16 patients were aged between 40-60 years and 13 were between 60-80 years. Thus CRC is the disease of old age. The incidence of this disease in young age is associated, with hereditary syndromes like Peutz-Jegher's,

hereditary non polyposis colorectal cancer or Familial adenomatous polyposis.<sup>18</sup>

Age and sex of the patients showed no statistical correlation with VEGF expression (Table 4 & 5). Similar observations was also seen in other studies,<sup>19-22</sup> However, Van Triest B et al study showed contrary findings where in significant positive correlation between VEGF expression and patient's gender and age was demonstrated.<sup>23</sup>

Further, site of the tumors also did not have correlation with VEGF expression. (Table 6). Similar observation was also seen in Mohamed HAD et al study.<sup>32</sup>

In the current study, VEGF expression was more intense i.e score 4 was demonstrated in poorly differentiated and grade 3 tumors. As the grading of the tumor increased, the intensity of VEGF expression also increased. This shows strong statistical correlation of VEGF expression with Histological grade of the tumor (Table 2). Studies by Mohamed HAD et al,<sup>32</sup> Zheng et al,<sup>15</sup> Jia et al,<sup>21</sup> Xu et al<sup>22</sup> and Ali F et al<sup>16</sup> also demonstrated similar observation.

The next factor to show significant correlation with VEGF expression was tumor stage (Table 3). We used TNM classification for staging of the tumor. Most of the stage III tumors showed score 4 of VEGF expression. The stage I tumors showed predominantly score 2 of VEGF expression and stage II tumors showed predominantly score 3 of VEGF expression. This result matched with other studies of Minagawa et al,<sup>25</sup> Jia et al<sup>21</sup> and Saumaoro et al.<sup>26</sup>

Further, it was also observed that all tumors with mucinous component showed increased VEGF expression (score 3). Similar observation was seen in Mohamed HAD et al study.<sup>32</sup>

VEGF is an important growth factor required for tumor angiogenesis in most of the solid malignancies including CRCs. Many studies have shown that increased VEGF expression in primary tumors was associated with poor prognosis.<sup>26,27,28</sup> But this also implies that VEGF could be a potentially useful target for pharmacological inhibition of angiogenesis. Hence, several different research projects are underway to target VEGF signal transduction. Counteracting monoclonal antibodies against VEGF have been shown to block its angiogenic activity, resulting in regression of tumor vasculature which in turn helps in inhibiting the further progression of the tumor. This can also increase the delivery of chemotherapy and make radiation therapy more effective. Most importantly it can increase the survival of CRC patients.<sup>29-31</sup>

## Conclusion

The results of the study further give the evidence for the role of VEGF in the carcinogenesis of CRC. Accordingly, increased VEGF expression could be considered as a poor prognostic parameter of colorectal malignancies. Further, inhibition of VEGF might be a promising targeted antiangiogenic therapy in CRC which could improve outcomes.

**Conflict of Interest:** None.

## References

1. Mohandas K M. Colorectal cancer in India: controversies, enigmas and primary prevention. *Indian J Gastroenterol* 2011;30(1):3-6.
2. Brenner H, Hoffmeister M, Haug U. Should colorectal cancer screening start at the same age in European countries? Contributions from descriptive epidemiology. *Br J Cancer* 2008;99:532-535.
3. Zarychanski R, Chen Y, Bernstein CN, Hebert PC. Frequency of colorectal cancer screening and the impact of family physicians on screening behavior. *CMAJ* 2007;177:593-597.
4. Khafagy W, El-Ghazaly M, El-Shobaky MT, Khafagy M. Colorectal cancer in Egypt \_ does it differ? *Coloproctol* 2000;22:109-115.
5. Bronner MP. Gastrointestinal inherited polyposis syndromes. *Mod Pathol* 2003;16:359-365.
6. Ahsan H, Neugut AI, Garbowski GC, Jacobson JS, Forde KA, Treat MR, et al. Family history of colorectal adenomatous polyps and increased risk for colorectal carcinoma. *Ann Intern Med* 1998;128:900-905.
7. Eaden J. Colorectal carcinoma and inflammatory bowel disease. *Aliment Pharmacol Ther* 2004;20:24-30.
8. Nishida N, Yano H, Nishida T, Kamura T, Kojiro M. Angiogenesis in Cancer. *Vasc Health Risk Manag* 2006;2(3):213-219.
9. Klagsbrun M, D'Amore PA. Regulation of angiogenesis. *Annu Rev Physiol* 1991;53:217-39.
10. Folkman J. What is the evidence that tumors are angiogenesis dependent? *J Natl Cancer Inst* 1990;82:4-6.
11. Shiota G, Ishida M, Noguchi N, Oyama K, Takano Y, Okubo M, et al. Circulating P53 antibody in patients with colorectal carcinoma: relation to clinicopathological features. *Dig Dis Sci* 2000;45:122-128.
12. Takuya Y, Takao O, Tadashi S, Hiromitsu M, Kazuyuki T, Hirota I, et al. Vascular endothelial growth factor (VEGF) as a prognosticator for colorectal cancer. *J Jpn Soc Colo-Proctol* 2000;53:27-34.
13. Shibuya M. Structure and function of VEGF/VEGF-receptor system involved in angiogenesis. *Cell Struct Funct* 2001;26:25-35.
14. Holmes DIR, Zachary I. The vascular endothelial growth factor (VEGF) family: angiogenic factor in health disease. *Genome Biol* 2005;6:209-212.
15. Zheng S, Han MY, Xiao ZX, Peng JP, Dong Q. Clinical significance of vascular endothelial growth factor expression and neovascularization in colorectal carcinoma. *World J Gastroenterol* 2003;9:1227-1230.
16. Ali F, Hashim, As'ad A. Al-Janabi. Vascular endothelial growth factor receptor expression correlates with histologic grade and stage of colorectal cancer. *Libyan J Med* 2010;5:5059.
17. Patil, P.S, Saklani A, Gambhire, P. Colorectal Cancer in India: An Audit from a Tertiary centre in a low prevalence area. *Indian J Surg Oncol* 2017;8:484.
18. Kumar, Abbas, Fausto, Mitchel. Robbins Basic Pathology (8<sup>th</sup>ed). Philadelphia: Saunders/Elsevier. 2007;619-620.
19. Akagi K, Ikeda Y, Miyazaki M, Abe T, Kinoshita J. Vascular endothelial growth factor-C (VEGF-C) expression in human colorectal cancer tissues. *Br J Cancer* 2000;83:887-891.
20. Hanrahan V, Currie MJ, Gunningham SP, Morrin HR, Scott PA. The angiogenic switch for vascular endothelial growth factor VEGF-A, VEGF-B, VEGF-C and VEGF-D in the adenoma-carcinoma sequence during colorectal cancer progression. *J Pathol* 2003;2:183-194.

21. Jia Y-T, Li Z-X, He Y-T, Liang W, Yang H-C, Ma HJ (2004) Expression of vascular endothelial growth factor-C and the relationship between lymphangiogenesis and lymphatic metastasis in colorectal cancer. *World J Gastroenterol* 2004;10:3261-3263.
22. Xu T, Chen D, Chen J. Expression of vascular endothelial growth factor C and its correlation with lymph node metastasis in colorectal carcinoma. *J Huazhong Univ Sci Technolog Med Sci* 2004;24:596-598.
23. Van Triest B, Pinedo HM, Blaauwgeers JL, van Diest PJ, Schoenmakers PS, et al. (2000) Prognostic role of thymidylate synthase, thymidine phosphorylase/platelet-derived endothelial cell growth factor and proliferation markers in colorectal Cancer. *Clin Cancer Res* 2000;6:1063-1072.
24. Xu Q, Chen RX, Wang ZW, Ni QC, Qian JJ. Clinical research on angiogenesis in colorectal carcinoma and expression of CK20 mRNA in peripheral blood. *Zhonghua Yi Xue Za Zhi* 2005;85:1205-1208.
25. Minagawa N, Nakayama Y, Hirata K, Onitsuka K, Inoue Y. Correlation of plasma level and immunohistochemical expression of vascular endothelial growth factor in patients with advanced colorectal cancer. *Anticancer Res* 2002;22:2957-2963.
26. Saumaoro LT, Uetake H, Takagi Y, Iida S, Higuchi T, et al. Coexpression of VEGF-C and Cox-2 in human colorectal cancer and its association with lymph node metastasis. *Dis Colon Rectum* 2006;49:392-398.
27. Ellis LM. Preclinical data targeting vascular endothelial growth factor in colorectal cancer. *Clin Colorectal Cancer* 2004;4:55-61.
28. Boxer GM, Tsiompanou E, Levine T, Watson R, Begent RH. Immunohistochemical expression of vascular endothelial growth factor and micro vessel counting as prognostic indicators in node negative colorectal cancer. *Tumour Biol* 2005;26:1-8.
29. Sia D, Alsinet C, Newell P, Villanueva A. VEGF signaling cancer treatment. *Curr Pharma Des* 2014;20(17):2834-2842.
30. Rosen LS (2005) VEGF-targeted therapy: Therapeutic potential and recent advances. *Oncol* 2005;6:382-391.
31. Pradeep CR, Sumila ES, Kuttan G (2005) Expression of vascular endothelial growth factor and VEGF receptors in tumor angiogenesis and malignancies. *Integr Cancer Therap* 2005;4:315-321.
32. Mohamed HAD, Abd El All HS, Kamel AAEA. Correlation of Vascular Endothelial Growth Factor expression and Neovascularization with Colorectal Carcinoma: A Pilot Study. *J Adenocarcinoma* 2016;1:1.

**How to cite this article:** Adil SAK, Sharath Kumar HK, Chaithra MS, Bharathi M. Study of expression of vascular endothelial growth factor and histomorphological correlation in colorectal malignancies. *Indian J Pathol Oncol* 2019;6(1):57-62.