

A rare case of nodular hidradenoma in inguinal region with cytohistological correlation: A case report

Varun Kumar¹, Sujata Raychaudhuri^{2,*}, Kanika Singh³, Sheetal G. Gole⁴

¹Tutor, ²Associate Professor, ³Assistant Professor, ⁴Professor, Dept. of Pathology, ESIC Medical College and Hospital, Faridabad, Haryana, India

*Corresponding Author: Sujata Raychaudhuri

Email: sujatabulu@yahoo.co.in

Received: 30th July, 2018

Accepted: 30th November, 2018

Abstract

Nodular hidradenomas is an uncommon benign skin tumor which arises as nodules from eccrine sweat glands. It is more common in adults. We present here a case of nodular hidradenoma in inguinal region with complaints of oozing in a middle aged female. Cytological diagnosis was suggestive of adnexal tumor and final confirmation was based on histopathology aided with immunohistochemistry. The case is presented to highlight the significance of cytology in the initial diagnosis of this lesion if correlated carefully with clinical presentation along with typical cytological features.

Keywords: Hidradenoma, Cytology, Inguinal, Histopathology, Immunohistochemistry.

Introduction

Hidradenoma is a benign cutaneous tumour of the sweat glands. It is also known as nodular hidradenoma, eccrine acrospiroma, clear cell myoepithelioma and solid cystic hidradenoma. It is a slow growing, solitary, solid or cystic and firm intradermal nodule which generally occur on head and neck or limb. The overlying skin may be flesh colored, erythematous or blue. It can affect any age group ranging from 3-93 years. The peak incidence is found in middle aged adults with slightly predominance in female. Sometimes it can be symptomatic, with spontaneous oozing, hemorrhage, tenderness, pruritus and burning.¹ Here, we report a rare case of nodular hidradenoma presenting in inguinal region which is an uncommon site, with cytohistological correlation.

Case Report

A 35 year old female came to surgical out patient department with a swelling on right inguinal region since four months. She complained of watery discharge from the lesion since last one week. There was no history of trauma on that site. She had taken ATT for pulmonary tuberculosis three years back. Clinically differential diagnosis of tubercular or reactive lymph node was given and patient came to the department of pathology for fine needle aspiration cytology (FNAC). On examination, there was a solitary, slightly elevated swelling with normal appearing skin, measuring approximately 1 cm × 1 cm. There was no discharge at that time. It was firm, mobile and non tender. No other swellings were found elsewhere in the body. Her routine hematological and biochemical investigation were in normal limits. FNAC was performed from the lesion and cytological smears were stained with May Grunwald Giemsa stain. Smears were moderately cellular showing

polygonal cells which were small having round to ovoid nucleus with dense cytoplasm along with few other cells which were having larger nucleus with vacuolated cytoplasm. Also noted were few spindle to squamoid cells with occasional eosinophilic hyaline material against a hemorrhagic background (Fig. 1). A provisional diagnosis of benign adnexal tumor or mesenchymal lesion was rendered. Following this, local excision was done and sent for histopathological examination (HPE). Grossly, a skin covered soft tissue mass was received measuring 2cmx1cm x1cm with well circumscribed nodule measuring 0.8 cm × 0.8 cm in the dermis. Cut section of the nodule showed a grey white solid areas and few tiny cystic areas filled with straw colored fluid. Microscopy revealed a well circumscribed nodule in the dermis without any connection to overlying epidermis (Fig. 2a). Nodule comprised of two types of cells: polyhedral cells with eosinophilic granular cytoplasm and round or oval vesicular nuclei with conspicuous nucleoli and other cells with clear cytoplasm containing a small, dark, central to eccentric located nucleus. Tumor cells also formed duct like structure at few places. Also seen were some cystic spaces filled with eosinophilic material (Fig. 2b). The clear cells contain considerable amounts of glycogen which were PAS positive (Fig. 3a). Immunohistochemical (IHC) staining showed diffuse membranous positivity for CK (Fig. 3b). EMA showed patchy membranous positivity (Fig. 3c) while focal cytoplasmic positivity was noted for CEA (Fig. 3d). S-100 and vimentin were negative. There were no evidence of necrosis, atypical cells and mitotic figures. Histopathological features were consistent with nodular hidradenoma which was supported by IHC.

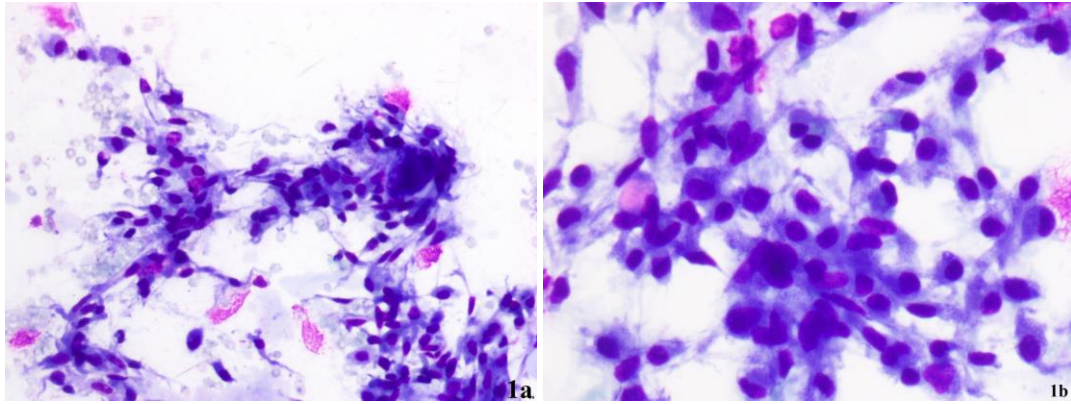


Fig. 1a, 1b: MGG stained cytosmear shows small round to ovoid to spindle cells with dense and vacuolated cytoplasm. (20x, 40x respectively)

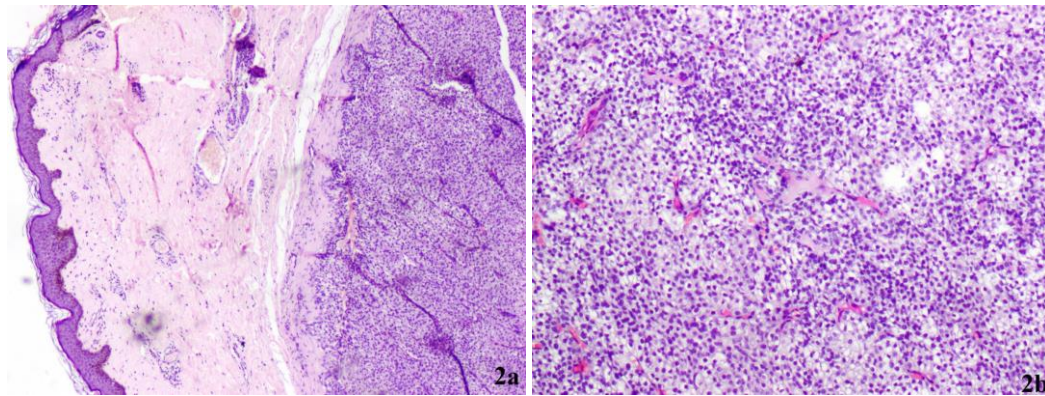


Fig. 2(a): H & E stained microsection shows a well circumscribed nodule in dermis (4x); 2(b): Higher power shows polygonal cells with dense eosinophilic cytoplasm and clear cells with clear cytoplasm (10x).

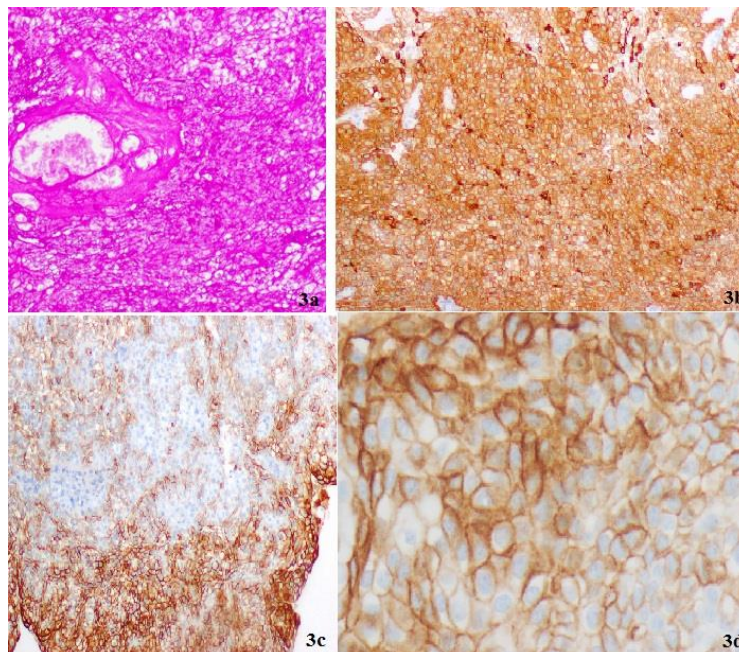


Fig. 3 (a): Tumor cells show PAS stain positivity (10x); 3(b): Diffuse CK membranous positivity (10x); 3(c): Patchy EMA membranous positivity (10x); 3(d): Focal CEA cytoplasmic positivity (40x)

Discussion

Nodular hidradenoma is a rare skin tumor. It arises from distal excretory ducts of eccrine gland. Most common sites of nodular hidradenoma are face, upper extremity, axilla, trunk, thigh and scalp.² First case of nodular hidradenoma was described by Liu, in 1949, as clear cell papillary carcinoma of the skin.³ Nodular hidradenoma commonly affects middle aged women and presents as a solitary, slow growing, mobile and firm nodule.¹ In our case, a female patient of middle age presented with inguinal swelling and occasional watery discharge. Inguinal region is not a common site for this condition and very few cases have been reported.^{4,5} To the best of our knowledge ours is the first case of nodular hidradenoma in a patient who was clinically suspected to have secondary tuberculosis. Cytological smears are usually cellular contain polygonal and clear cells. Polygonal cells contain round to oval nuclei with faint eosinophilic cytoplasm. Sometimes these cells show squamoid spindle cell like appearance. Clear cells have round eccentric nuclei, granular chromatin with watery clear cytoplasm. Extracellular hyaline and amorphous material also present in the background.⁶ In present case similar cytological features were noted. In the literature diagnosis of nodular hidradenoma on cytology is rarely reported. Most of cases are inconclusive or misinterpreted or misdiagnosed on FNAC. HPE of classical nodular hidradenoma shows well circumscribed nodule in the dermis without any connection to epidermis. Both solid and cystic components are seen. Cystic spaces are filled with homogeneous eosinophilic material. In the solid area, tumor cells are arranged in lobules which can have tubular lumina lined with cuboidal to columnar epithelium. Different proportion of polyhedral and clear cells varies considerably from tumor to tumor. Polyhedral cells with a rounded nucleus and slightly basophilic cytoplasm. These cells may appear fusiform and show an elongated nucleus. Clear cells are round and contain watery clear cytoplasm with small and dark nucleus. These cells contain considerable amounts of glycogen which are PAS-positive and diastase-resistant material at the periphery. In some tumors, squamoid differentiation and horn pearls formation are seen. Immunohistochemical reactivity for keratin, EMA, CEA, S100 protein, and vimentin is characteristic for nodular hidradenoma.⁷ This case showed consistent CK and PAS positivity. However, IHC were negative for S-100 and vimentin while EMA and CEA showed patchy and focal positivity respectively. Search in literature showed a single case of nodular hidradenoma in inguinal lymph node reported by Tingaud C et al.⁴ But in our case, inguinal LN was not involved.

Conclusion

Fine needle aspiration cytology is not confirmatory for nodular hidradenoma but in view of round to ovoid cells with few spindle and squamoid cells at an unusual site from a swelling with history of oozing should arouse the suspicion of nodular hidradenoma. It should be kept as differential

which can be correlated and confirmed by histopathology, supported by IHC.

Conflict of Interest: None.

References

1. Calonje E, Brenn T, Lazar A, McKee PH. Mackee's pathology of the skin. 4th ed. Philadelphia: Elsevier Saunders; 2012. p. 1545-46.
2. Mote DG, Ramamurti T, Naveen Babu B. Nodular hidradenoma of the breast: A case report with literature review. *Indian J Surg* 2009;71(1):43-45.
3. Liu Y. The histogenesis of clear cell papillary carcinoma of the skin. *Am J Pathol* 1949;25:93-103.
4. Tingaud C, Costes V, Frouin E, Delfour C, Cribrier B, Guillot B et al. Lymph node location of a clear cell hidradenoma: report of a patient and review of literature. *J Cutan Pathol* 2016;43(8):702-706.
5. Rekhi B, Ingle A, Patil B, Jambhekar NA. Cytomorphological spectrum of a nodular hidradenoma in a young girl presenting with an inguinal soft tissue mass. *Cytopathol* 2011;22(2):135-137.
6. Nasit JG, Dhruva G. Nodular hidradenoma of the scalp: A cytomorphological evaluation on fine needle aspiration cytology. *Indian J Dermatol Venereol Leprol* 2014;80(6):569-572.
7. Elder DE, Elentisas R, Murphy GF, Johnson BL, Xu X. *Lever's Histopathology of the Skin*. 10th ed. Philadelphia: Lippincott Williams & Wilkins; 2019. p. 891-92.

How to cite this article: Kumar V, Raychaudhuri S, Singh K, Gole SG. A rare case of nodular hidradenoma in inguinal region with cytohistological correlation: A case report. *Indian J Pathol Oncol* 2019;6(1):161-163.