

Inflammatory myofibroblastic tumour of bladder: A case report

H.R. Chandrasekhar¹, Sunita Nyamagoudar^{2,*}, Seema Bijjaragi³

^{1,3}Professor, ²PG Student, Dept. of Pathology, JJM Medical College, Davanagere, Karnataka, India

*Corresponding Author: Sunita Nyamagoudar

Email: sunita.kims@gmail.com

Received: 24th April, 2018

Accepted: 28th July, 2018

Abstract

Inflammatory myofibroblastic tumour (IMT) is a rare tumour with an unknown malignant potential. IMTs are known to occur in many sites. These tumours very rarely noted in bladder. It is important to distinguish this tumor from other malignant spindle cell tumors, such as the sarcomatoid variant of urothelial carcinoma and leiomyosarcoma. This distinction has clinical consequences because IMT is generally considered benign and treated with conservative management. Here we report a case of IMT in bladder in a 23 years old female who presented with a lower abdominal mass and abdominal pain. Histopathology revealed that muscularis propria of the bladder, was widely infiltrated by loosely arranged plump spindle shaped cells and immunohistochemistry was positive for both SMA (smooth muscle actin) and ALK1 (Anaplastic lymphoma kinase 1). So we present this case for its rarity and diagnostic uncertainty.

Keywords: Inflammatory myofibroblastic tumour, Bladder.

Introduction

Inflammatory myofibroblastic tumour (IMT) is an uncommon neoplasm with an unknown cause. It is composed of myofibroblastic and fibroblastic spindle shaped cells associated with an inflammatory infiltrate.¹ IMT was previously considered to be a subset of inflammatory pseudotumor, but now considered to have their discrete diagnosis.²

IMT was first described by Brunn in 1939. Diagnosis is difficult to establish in these cases as the clinical and radiological features are diverse and non specific.³

Case Report

A 23 year old female presented to the department of Obstetrics and Gynecology with a lower abdominal mass and pain since 6 months. Clinically it was suspected as a desmoids tumour or pelvic fibromatosis. MRI pelvis was done which revealed urinary bladder wall thickening-suggesting an infective or inflammatory cause and mild collection of fluid in the pouch of douglas was noted. (Fig. 1) Cystectomy was done. Hysterectomy with bilateral salpingectomy and left sided oophorectomy was performed.

Grossly uterus and adnexa appeared unremarkable. Also received were multiple bladder tissue bits largest one measuring 8x8x3cm and smaller bits altogether measuring 9x7x1cm. Cut surface of all the bits was grey white. Histopathological examination revealed that muscularis propria of the bladder, was widely infiltrated by loosely arranged plump spindle shaped cells having vesicular nuclei with inconspicuous nucleoli and long wisps of cytoplasm in a myxoid and collagenous background (Fig. 2). Accompanied by infiltration of inflammatory cells composed of lymphocytes, plasma cells, neutrophils and eosinophils. (Fig. 3) Few areas also showed lymphoid follicle formation and infiltration into the surrounding adipose tissue. Immunohistochemistry showed positivity for

both SMA (smooth muscle actin) and ALK1 (Anaplastic lymphoma kinase 1). (Fig. 4) and (Fig. 5)

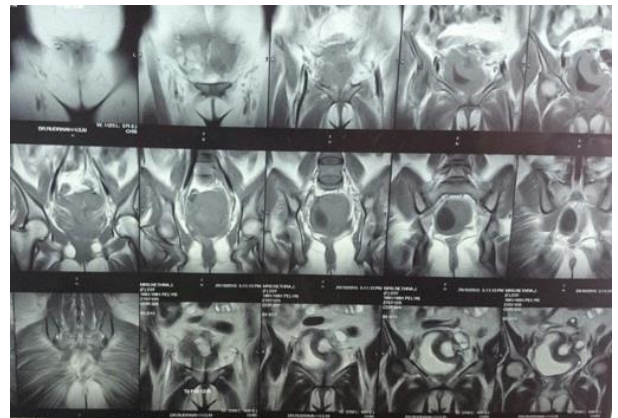

Fig. 1: MRI pelvis showing urinary bladder wall thickening and collection in pouch of douglas

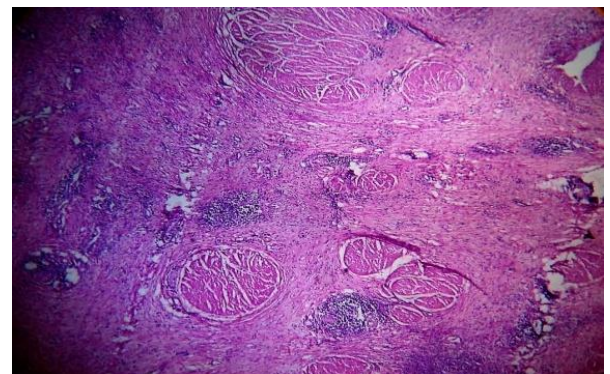


Fig. 2: Photomicrograph showing smooth muscle cells fibroblastic cells in a collagenous background (H&Ex100)

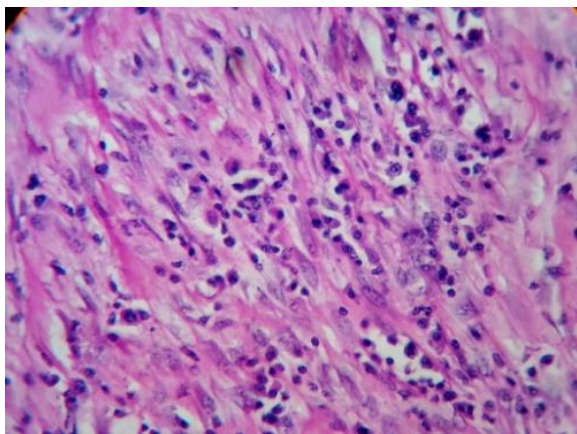


Fig. 3: Photomicrograph showing lymphocytes, plasma cells, neutrophils and eosinophils (H&Ex400)

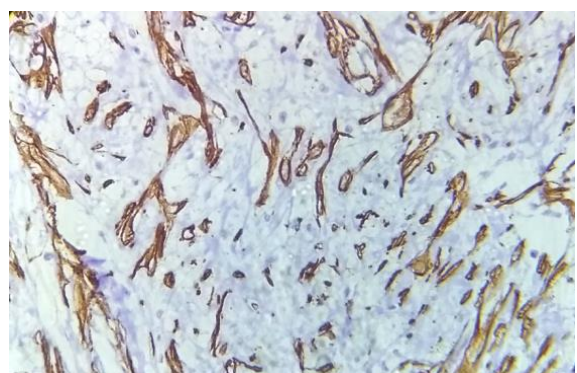


Fig. 4: Photomicrograph showing immunohistochemistry positivity for SMA (x400)

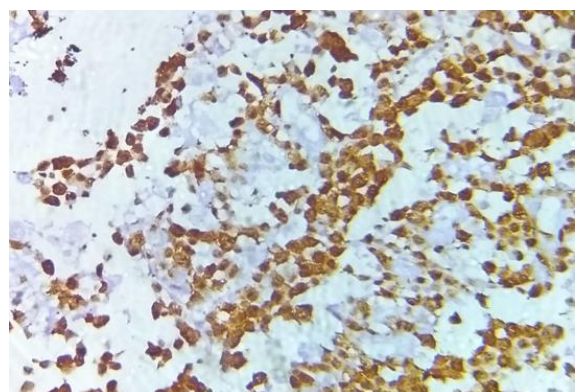


Fig. 5: Photomicrograph showing immunohistochemistry positivity for ALK1 (x400)

Discussion

IMT is a rare spindle cell neoplasm characterized by atypical spindle cell proliferation and an inflammatory infiltrate which consists of lymphocytes, plasma cells and eosinophils. Most of the cases occur in children and young adults with a slight female preponderance.⁴

IMT occurs most frequently in the mesentery, omentum, retroperitoneum, pelvis and abdominal soft tissue followed by lung, mediastinum and head and neck. Unusual locations include gastrointestinal tract, uterus, bladder,

pancreas and CNS. IMT was referred to by different names such as plasma cell granuloma, inflammatory myofibrohistiocytic proliferation, omental mesenteric myxoid hamartoma, inflammatory pseudotumor, inflammatory fibrosarcoma, inflammatory myofibroblastic sarcoma.¹

Etiology of these neoplasms remains unknown but various initiative factors such as reactive, infections, autoimmune and neoplastic processes are considered in the pathogenesis. Inflammatory mediators such as cytokines and interleukin-1 (IL-1) are released in response to an insult causing proliferation of fibroblasts, leaky and pro-coagulant endothelium and extravasation of polymorphous cellular infiltrate into the extracellular spaces.⁵

Histologically three patterns are recognised. First is a myxoid or vascular pattern. In this pattern the spindle shaped cells are loosely arranged in an edematous or myxoid stroma and the stroma has prominent vasculature. Mixed inflammatory infiltrate are seen, consisting of neutrophils, eosinophils and few plasma cells. Second is a compact spindle cell pattern consisting of proliferating spindle cells with a fascicular or storiform architecture. Plasma cells and lymphocytes intermixed with spindle cells are seen. Third is hypocellular fibrous pattern with elongated spindle cells with densely collagenous stroma and scattered lymphocytes, plasma cells and eosinophils.⁶

Immunohistochemically, these tumours are positive for SMA (tram track staining pattern) in 90% of cases. ALK expression is seen in 50% of cases and is variable. They may focally express pancytokeratin in 50% cases. Other markers like desmin and h-caldesmon show variable expression.⁶

IMT in bladder can be misdiagnosed as postoperative spindle cell nodule, rhabdomyosarcoma, leiomyosarcoma or sarcomatoid urothelial carcinoma, and as a result, unnecessary radical surgery, adjuvant therapy and its complications, is a major problem of contemporary IMT diagnostics.⁷

Conclusion

Inflammatory myofibroblastic tumour is a rare spindle cell tumour. It is important to distinguish this tumour from other malignant spindle cell tumours, such as the sarcomatoid variant of urothelial carcinoma and leiomyosarcoma. This distinction has clinical consequences because IMT is generally considered benign and treated with conservative management. Diagnosis can only be confirmed after histological and immunohistochemical studies. These tumours require complete surgical excision because of tendency for recurrence and local invasion.

Conflict of Interest: None.

References

1. Coffin CM, Fletcher JA. Inflammatory myofibroblastic tumour. In: Fletcher C, Bridge JA, Hogendoorn P, Mertens F. WHO classification of tumours of soft tissue and bone 4th edition. International agency for research on cancer, Lyon 2013. p. 83-85.

2. Firat O, Ozturk S, Akalin T, Coker A. Case note: Inflammatory myofibroblastic tumour. *Can J Surg* 2009;52:E60-61.
3. Hammas N, Chbani L, Rami M. A rare tumour of the lung: inflammatory myofibroblastic tumour. *Diagn Pathol* 2012;7:1-4.
4. Deshmukh M, Pagey R, Galani KS, Joshi P, Bitey A, Kotwal M. Inflammatory myofibroblastic tumour of the urinary bladder- a case report with review of literature. *Open J Pathol* 2014;4:176-180.
5. Palaskar S, Koshti S, Maralingannavar M, Bartake A. Inflammatory myofibroblastic tumour. *Contemp Clin Dent* 2011;2:274-277.
6. Alderman M, Kunju LP. Inflammatory myofibroblastic tumour of the bladder. *Arch Path Lab Med* 2014;138:1272-1277.
7. Dobrosz Z, Rys J, Palen P, Wlaszczuk P, Ciepiela M. Inflammatory myofibroblastic tumour of the bladder – an unexpected case coexisting with an ovarian teratoma. *Diagn Pathol* 2014;9:1-5.

How to cite this article: Chandrasekhar HR, Nyamagoudar S, Bijjaragi S. Inflammatory myofibroblastic tumour of bladder: A case report. *Indian J Pathol Oncol* 2019;6(1):164-166.