

## Recurrent frontal sinus mucocele in a loner frontal cell

Raman Wadhwa<sup>1</sup>, Aarushi Vashist<sup>2,\*</sup>, P Sahana<sup>3</sup>, Keshav Gupta<sup>4</sup>

<sup>1</sup>Professor ENT, <sup>2,4</sup>Resident, Pandit Bhagwat Dayal Sharma University of Health Sciences, Rohtak, Haryana, India

**Corresponding Author: Aarushi Vashist**

Email: aaavashist@gmail.com

### Abstract

A frontal sinus mucocele is a cystic lesion full of thick mucus in the frontal sinuses. It develops when the opening of a paranasal sinus becomes obstructed because of trauma, infection, chronic sinusitis, polyps, malignancy, bony tumors, or congenital anomalies. As it increases in size, a mucocele can make its way through the surrounding bone or discharge through the skin. Here we present a case of 45-year-old male who developed swelling in the left supraciliary region. CECT scan and MRI was done. It revealed soft tissue enhancing lesion in the left frontal sinus region. Marsupialization was done previously but the swelling recurred after 3 months. Open frontal sinus exploration under general anaesthesia was done removing all the walls of the sac along with affected frontal bone. Patient improved symptomatically after this operation.

**Keywords:** Frontal sinus, Diabetic, Loner frontal cell, Mucocele.

### Introduction

A frontal paranasal sinus mucocele is a cystic lesion full of thick mucous in the paranasal sinuses. It develops when the opening of a paranasal sinus becomes obstructed because of trauma, infection, chronic sinusitis, polyps, malignancy, bony tumors, or congenital anomalies. As it increases in size, a mucocele can make its way through the surrounding bone or discharge through the skin.

The majority of paranasal sinus mucoceles are frontal sinus mucoceles. They are generally benign but if they expand, the pressure they exert on the surrounding areas can cause problems.

Mucoceles tend to expand to where there is least resistance, often through the thin bone of the superior orbital wall. If a mucocele becomes infected, it can form epidural abscesses, meningitis, subdural empyema (pus), or intracerebral abscesses.

### Case Report

A 45-year-old male presented to otolaryngology outpatient department with the chief complaint of swelling over left upper eyelid for past 3 months (Fig. 1). It was insidious in onset and gradually progressive in nature. The patient had no history of decrease in vision, blurring of vision or watering of eyes. There was no history of nasal discharge, post nasal drip, nasal bleed, no history of any alteration of smell. The patient had no history of any trauma to eye or nose. History of headache, facial pain, up rolling of eyeballs, neck stiffness, fever was also absent. The patient is a known case of diabetes for past 6 months with currently normal blood sugar levels. The patient had a similar history of swelling 6 months back for which marsupialization of loner frontal cell was done under general anaesthesia. The patient is nonsmoker and non-alcoholic. General physical examination of the patient was within normal limits. On local examination, swelling of size 2\*2 cm was present just below the left supraciliary region, 4 cm lateral to glabella. It was non-fluctuant, non-pulsatile, non-translucent and non-tender. Local temperature over the

swelling was not raised and overlying skin was also normal. On anterior rhinoscopy of nose, mild right sided deviated nasal septum was present. Paranasal sinus examination revealed mild tenderness in left frontal sinus region. Contrast enhanced computed tomography of paranasal sinuses revealed ill-defined subtle soft tissue enhancing lesion in nasal bone involving the lateral wall of left frontal sinus and left orbital roof with thinning and destruction of inner and outer cortex without any intracranial extension of lesion.(Fig. 2) MRI brain revealed a lobulated heterogeneously enhancing lesion with multiple cystic areas within it expanding the frontal bone on left side extending in roof of orbit with small extraconal lesion. Frontal sinus exploration under GA was planned. Neurosurgeon and ophthalmologist were also called. Lynch Howarth incision was given which was extended further laterally. Frontal sinus exposed and anterior wall of frontal sinus punched with Kerrison's bone punch (Fig. 3). Pus came out from lateral aspect of frontal sinus which was suctioned. Bony septations were broken. Dura was exposed in posterior wall of frontal sinus which was covered by fascia lata patch by neurosurgeon. Orbital periosteum was intact. Drain was kept in the frontal sinus cell which was removed after 5 days post-operatively. The patient improved symptomatically and the swelling subsided. (Fig. 4).



Fig. 1



Fig. 4

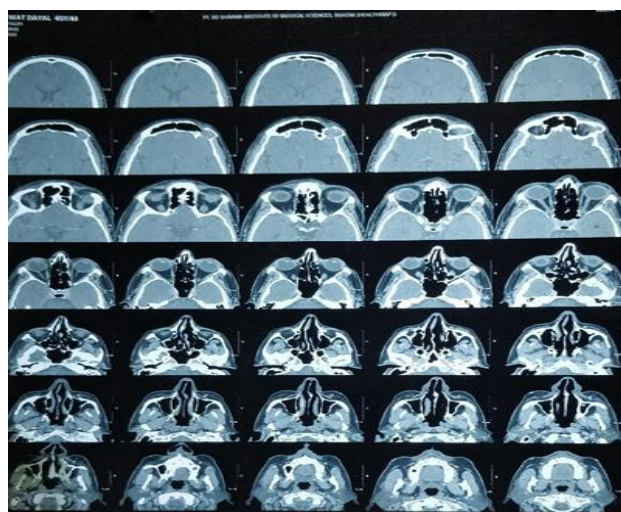


Fig. 2

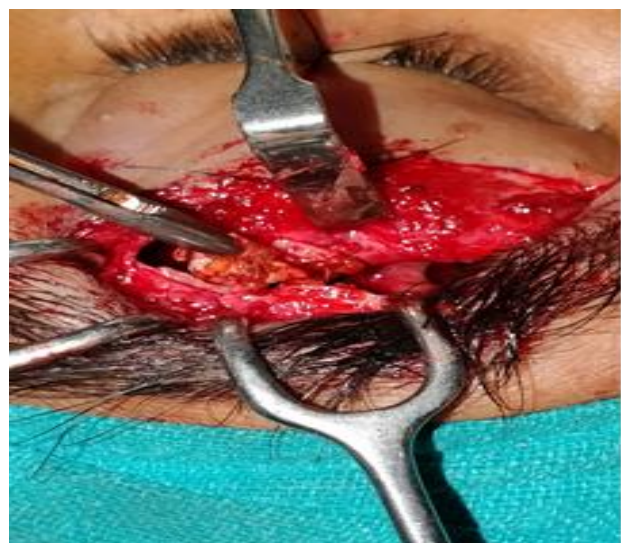

Fig. 3

**Discussion**

Mucoceles of the frontal sinus are relatively uncommon lesions of benign entity that occur with approximately equal frequencies in adult males and females, with the highest incidence in the third and fourth decades. They are uncommon in pediatric subjects.<sup>1,2</sup>

Mucoceles are slow growing and locally aggressive lesions that occur as a result of accumulation and retention of mucous secretions in the sinus caused by the loss of draining properties of the mucous epithelium of the sinus.<sup>2-6</sup> The fluid content progressively obliterates the sinus, and the pressure so generated leads to gradual erosion and distortion of the anterior and posterior bone walls.<sup>7-10</sup> The lesion may extend to the orbital and intracranial structures and lead to meningitis, brain abscess, or cerebrospinal fluid (CSF) fistulas.<sup>9,11,12</sup>

Because of the proximity of mucoceles to the brain, progress in volume may cause morbidity and potential mortality.<sup>13</sup>

The etiology may be multifactorial: trauma, allergy, inflammation, anatomic abnormality, previous surgery, osteoma, fibrous dysplasia, or ossifying fibroma.<sup>2-4,6,9</sup>

The main symptoms of orbital involvement are pain, swelling, exophthalmos, diplopia, and loss of vision. Proptosis is usually the main complaint. Oculomotor nerve palsy with ptosis is rare, but it can be seen in patients with frontal mucocele.<sup>14</sup>

Diagnosis is based on a clinical investigation conducted with the aid of computed tomography (CT) scans and magnetic resonance imaging (MRI). The CT scan is the main diagnostic assessment tool used for determining regional anatomy and extent of the lesion, in particular the intracranial expansion and the scope of bone erosion.<sup>7</sup> MRI is helpful in making a definitive diagnosis because gadolinium enhancement on MRI differentiates mucoceles from neoplasms.<sup>15</sup> Surgery is the only effective treatment and may range from functional endoscopic sinus surgery to craniotomy and craniofacial exposure with or without obliteration of the sinus.<sup>13,16-22</sup>

**Conflict of Interest:** None.

## References

1. Iqbal J, Kanaan I, Ahmed M, al Homsy M. Neurosurgical aspects of sphenoid sinus mucocele. *Br J Neurosurg* 1998;12:527-530.
2. Diaz F, Latchow R, Duvall AJ III, Quick CA, Erickson DL. Mucoceles with intracranial and extracranial extensions. Report of two cases. *J Neurosurg* 1978;48:284-288.
3. Lunardi P, Missori P, Di Lorenzo N, Fortuna A. Giant intracranial mucocele secondary to osteoma of the frontal sinuses: Report of two cases and review of the literature. *Surg Neurol* 1993;39:46-8.
4. Nakajima Y, Yoshimine T, Ogawa M, Takanashi M, Nakamuta K, Maruno M, Hasegawa H. A giant intracranial mucocele associated with an orbitoethmoidal osteoma. Case report. *J Neurosurg* 2000;92:697-701.
5. Iannetti G, Cascone P, Valentini V, Agrillo A. Paranasal sinus mucocele: diagnosis and treatment. *J Craniofac Surg* 1997;8:391-398.
6. Doyle CS, Simeone FA. Mucocele of the sphenoid sinus with bilateral internal carotid artery occlusion. *Case report. J Neurosurg* 1972;36:351-354.
7. Perugini S, Pasquini U, Menichelli F, Salvolini U, de Nicola M, Valazzi CM, Benedetti S. Mucoceles of the paranasal sinuses involving the orbit. *Neuroradiol* 1982;23:133-139.
8. Perie S, Sequert C, Cabanes J, Visot A, Krastinova D, Derome P, et al. Frontal mucoceles of orbital or cerebral extension: therapeutic strategy. *Ann Otolaryngol Chir Cervicofac* 1996;113:384-90.
9. Delfini R, Missori P, Iannetti G, Ciappetta P, Cantore G. Mucoceles of the paranasal sinuses with intracranial and intraorbital extension: report of 28 cases. *Neurosurgery* 1993;32:901-906.
10. Hashim AS, Asakura T, Awa H, Yamashita K, Takasaki K, Yuhi F, et al. Giant mucocele of paranasal sinuses. *Surg Neurol* 1985;23:69-74.
11. Voegels RL, Balbani AP, Santos RC, Butigan O. Frontoethmoidal extension of intracranial mucocele: A case report. *Ear Nose Throat J* 1998;77:117-120.
12. Nakayama T. Giant pyocele in the anterior intracranial fossa-case report. *Neurol Med Chir* 1998;38:499-502.
13. Weitzel EK, Hollier LH, Calzada G, Manolidis S. Single stage management of complex fronto-orbital mucoceles. *J Craniofac Surg* 2002;13:739-745
14. Lin CJ, Kao CH, Kang BH, Wang HW. Frontal sinus presenting as oculomotor nerve palsy. *Otolaryngol Head Neck Surg* 2002;126:588-590.
15. Lanzieri CF, Shah M, Krauss D, Lavertu P. Use of gadolinium-enhanced MR imaging for differentiating mucoceles from neoplasm in the paranasal sinuses. *Radiol* 1991;178:425-428.
16. Chiarini L, Nocini PF, Bedogni A, Consolo A, Gianetti L, Merli GA. Intracranial spread of a giant frontal mucocele: case report. *Br J Oral Maxillofac Surg* 2000;38:637-640.
17. Kennedy DW, Senior BA. Endoscopic sinus surgery. A review. *Otolaryngol Clin North Am* 1997;30:313-30.
18. Benninger MS, Marks S. The endoscopic management of sphenoid and ethmoidal mucoceles with orbital and intranasal extension. *Rhinol* 1995;33:157-161.
19. Bordley JE, Bosley WR. Mucoceles of the frontal sinus: Causes and treatment. *Ann Otol Rhinol Laryngol* 1973;82:696-702.
20. Rinehart GC, Jackson IT, Potparic Z, Tan RG, Chambers PA. Management of locally aggressive sinus disease using craniofacial exposure and the galeal frontalis fascia-muscle flap. *Plast Reconstr Surg* 1993;92:1219-1225.
21. Costantinidis J, Steinhart H, Schwerdtfeger K, Zenk J, Iro H. Therapy of invasive mucoceles of the frontal sinus. *Rhinol* 2001;39:33-38.
22. Stiernberg CM, Bailey BJ, Calhoun KH, Quinn FB. Management of invasive fronto-ethmoidal sinus mucoceles. *Arch Otolaryngol Head Neck Surg* 1986;112:1060-1063.

**How to cite this article:** Wadhera R, Vashist A, Sahana P, Gupta K, Recurrent frontal sinus mucocele in a loner frontal cell. *J Otorhinolaryngol and Allied Sci* 2019;2(1):28-30