

Inflammatory granuloma of larynx mimic as malignancy of larynx –A case report and review literature

Harendra Kumar Gautam^{1,*}, Ajay Pratap Singh², Aastha Singh³

¹Associate Professor, ²Consultant ENT, ³Junior Resident, ^{1,3}Dept. of ENT, ^{1,3}Ganesh Shankar Vidyarthi Memorial Medical College, Kanpur, ²Lal hospital and research centre, Lucknow, Uttar Pradesh, India

***Corresponding Author: Harendra Kumar Gautam**

Email: harendragautam34@yahoo.in

Abstract

Laryngeal granulomas are benign (noncancerous) masses that usually occur on the vocal processes of the arytenoids. Their presence on the right pyriform fossa with right arytenoid fixity is rarely encountered mimicking clinical symptoms and signs of malignancy larynx. We encountered a female with history of difficulty in swallowing food and pain in the throat. HRCT I. Neck & thorax shows a mass lesion involving right side of laryngopharynx with cartilage and strap muscles invasion. On fiber optic laryngoscopy it was found deep ulcers on right pyriform fossa with right arytenoid fixity and biopsy taken. Histopathological examination shows inflammatory granulation tissue. Hence any suspected malignancy larynx should be thoroughly evaluated.

Keywords: Inflammatory granuloma, Mimic and malignancy.

Introduction

Inflammatory granulomas are masses that develop as a result of chronic irritation and inflammation of the area. The source of irritation can be from chronic laryngopharyngeal reflux, during intubation, direct trauma to the larynx or vocal misuse/abuse. Laryngeal granulomas are benign (noncancerous) masses that usually occur on the vocal processes of the arytenoids.^{1,2} Granulomas also can occur in other regions of the larynx, including the portion of the larynx above the vocal folds (referred to as the supraglottic larynx), the portion of the larynx below the vocal folds (referred to as the subglottic larynx), and on the portions of the vocal folds that vibrate during phonation (referred to as the muscular membranous vocal fold). Here we are going to discuss a case of inflammatory granuloma of pyriform fossa of a 56 year old female, how she presented to us and how we managed the case.

Case report

A 56 year old female presented to our outpatient department with progressive dysphagia and odynophagia since 8 days. There was no regurgitation, dyspnea, hoarseness of voice or generalized symptoms such as fever and fatigue. Patient had no previous history of tuberculosis. She was not addicted to tobacco or alcohol. On examination, patient is of normal built with normal vitals, no pallor, icterus, cyanosis, clubbing, edema and lymphadenopathy. On examining the oral cavity and oropharynx, adequate mouth opening present with normal structures. On indirect laryngoscopy, it was found that right vocal cord not mobile with ulcerative lesion on right pyriform fossa rest structures seems normal. On fiber optic laryngoscopy and upper gastrointestinal endoscopy it was found deep ulcers with white cheesy exudate on right pyriform fossa with right arytenoid fixity with no reflux, no mucosal pathology and no duodenal ulcer. [Fig.1-2] HRCT neck & thorax shows a mass lesion involving right side of laryngopharynx with cartilage and strap muscles invasion. [Fig. 3-4]

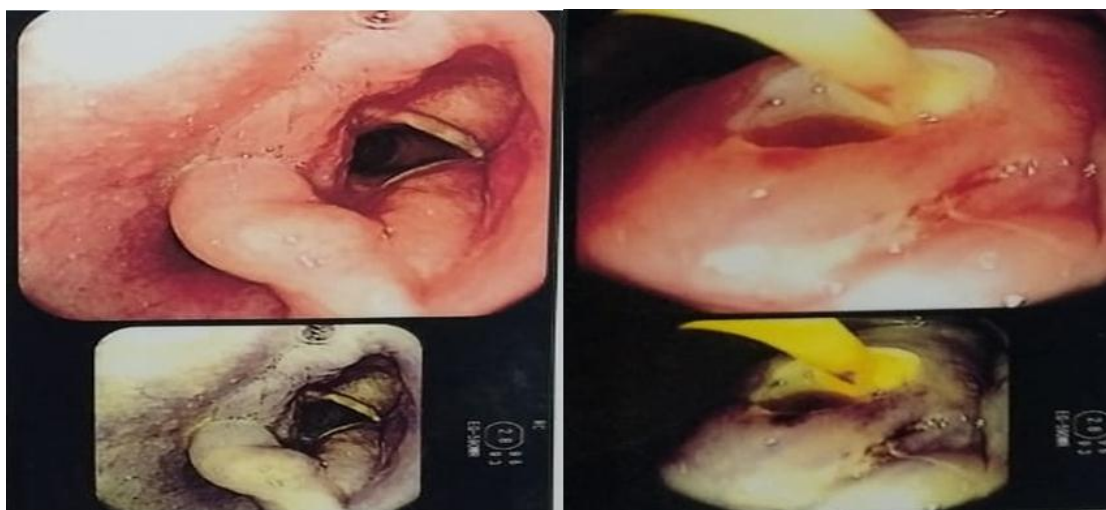

Fig. 1-2: Pretreatment fiber optic laryngoscopy pictures showing ulcerative lesion.

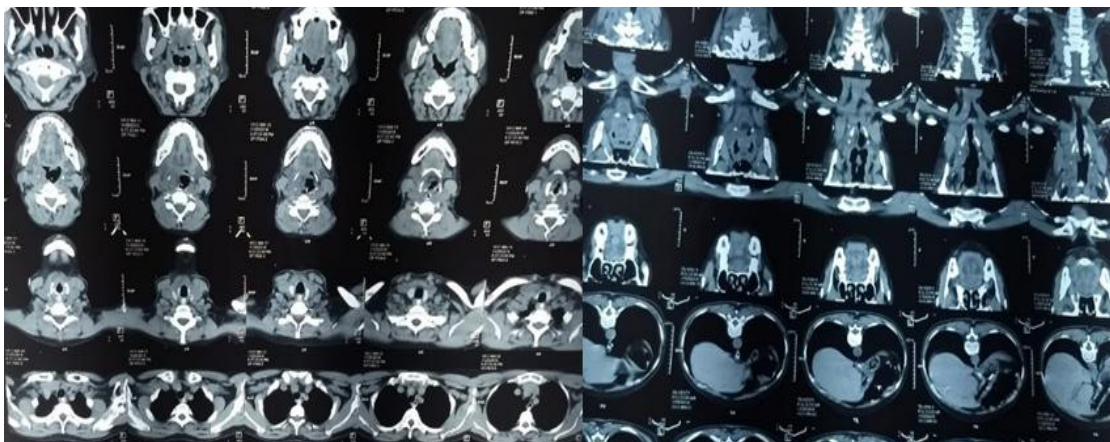


Fig. 3-4: Axial and Coronal view CT scan larynx showing mass lesion involving laryngopharynx.

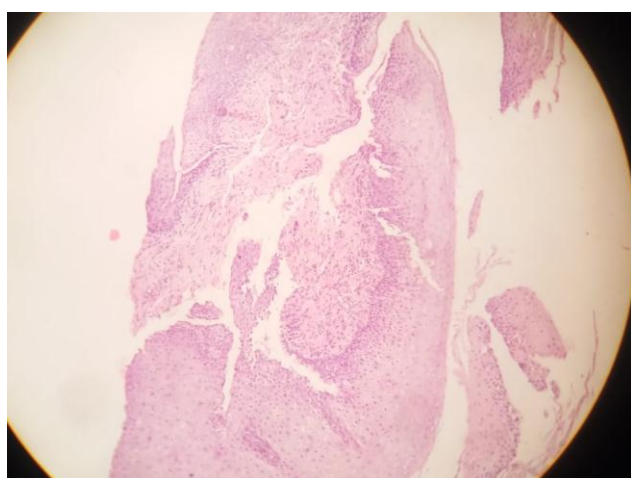


Fig. 5: Histopathological picture of ulcerative lesion showing inflammatory granulation tissue.

After examining the patient, she was planned for tissue biopsy and biopsy sample sent for histopathological examination. Histopathology suggestive of inflammatory granulation tissue. [Fig. 5]. Once it was confirmed that the

lesion present on the pyriform fossa is a benign lesion not malignant we had taken her on medications (antibiotics, proton pump inhibitors, antacid and anti-inflammatory) and voice rest. After taking 4 weeks of medical treatment patient symptoms get resolved and repeat fiber optic laryngoscopy reveals completely healed ulcer on right pyriform fossa with right arytenoid fixity which may be due to fibrosis. [Fig. 6].

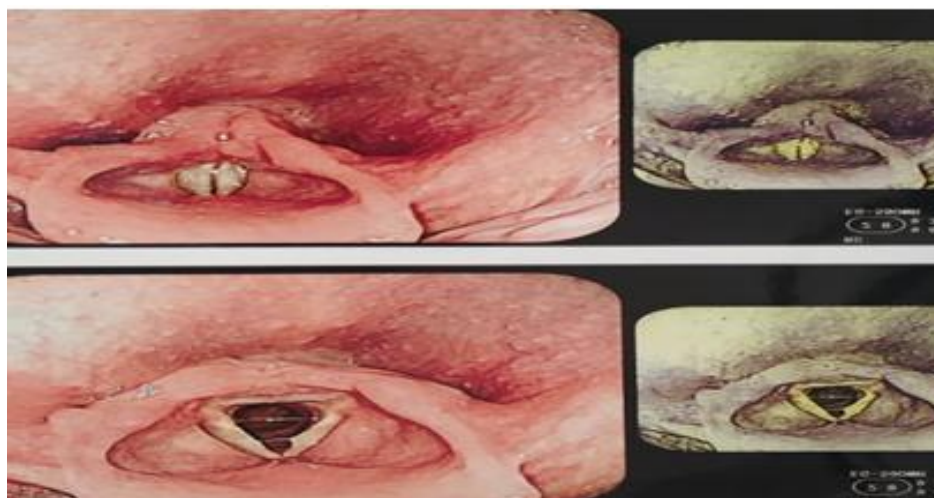


Fig. 6: Post treatment picture of fiberptic laryngoscopy showing complete remission.

Discussion

Granulomas are inflammatory lesions that can occur anywhere in the larynx, but typically occur in the posterior regions of the vocal folds on the vocal process of the arytenoid cartilage. Granulomas can form as a result of

direct trauma to the larynx.³ other causes are vocal abuse, vocal misuse, laryngopharyngeal reflux, intubation, or surgical or other trauma. Granulomas can cause a variety of symptoms namely throat pain dysphagia change in voice, sensation of lump in throat, and sometimes may cause no

symptoms at all. The inflammation that causes the formation of granulomas may cause irritation of the nerve endings underneath. This irritation of the nerve endings may result in the sensation of pain, either constantly or with eating, talking, or singing, depending on the proximity of the nerves to the inflamed area. The pain may be perceived as throat or ear discomfort. Ear pain occurs because of a phenomenon called "referred pain." The irritation of the nerve endings may also result in the sensation of a lump in the throat, the sensation that something is stuck in the throat, the sensation of a chronic tickle with or without chronic cough, or the persistent sensation that the throat needs to be cleared.⁴ Because granulomas are the result of an intense inflammatory reaction, they can continue to get bigger, if they remain untreated and exposed to repeated trauma. Rarely, they can grow to a size that is large enough to reduce significantly the amount of air that is able to go through the larynx and into the trachea and lungs the diagnosis of granulomas is made Examination of the larynx and the hypopharynx may be performed initially with a light and mirror. If an abnormal lesion is found, then perform either flexible or rigid laryngoscopy, or both, with atypical-appearing lesions at the time of the initial examination, a biopsy, which is sampling of the tissue for microscopic examination and diagnosis, is warranted. There are several other lesions that can mimic granulomas, and these usually will not resolve with the treatments that are used to treat granulomas. The other possibilities include cancer, benign tumours (noncancerous abnormal growths), tuberculosis (infection with the tuberculosis bacteria), fungal infections, papilloma's (abnormal growths in response to infection by the Human Papilloma Virus), and granulomatous diseases (conditions in which the body recognizes itself as foreign and has an abnormal reaction to itself not to be confused with granulomas which are inflammatory responses to injury).⁵ Biopsies are performed as The presence of lymphocytes (the blood cells that help with wound healing), thickened mucosa, ulcers, collagen (scar tissue), fibroblasts (the cells that make collagen), and an increased number of blood vessels are all elements of chronic inflammation that help the make the diagnosis of granuloma.^{2,3,6,7} The mainstay of treatment of granulomas involves identification and removal of the inciting irritant, speech and voice rehabilitation, and treatment of laryngopharyngeal reflux. Atypical lesions and for patients with lesions that do not respond to treatment. Patients with recalcitrant, symptomatic lesions may require more aggressive treatment, including the use of steroids, repeated excision of granulomas, abdominal surgery for reflux, and botulinum toxin injections into the laryngeal muscles. In our case history, symptoms, fiber optic laryngoscopy and

computerize tomography suggests a malignant lesion but biopsy and HPE finding made the diagnosis as inflammatory granuloma. For this conservative treatment was done in the form of antibiotics, proton pump inhibitors, antacid and anti-inflammatory and voice rest. Patient signs and symptoms was completely cure after 4 weeks of treatment.

Conclusion

The various benign and malignant lesions of larynx can mimic inflammatory granuloma or vice versa. So that the proper history, clinical examination, fiber optic laryngoscopy and histopathological findings confirm the diagnosis and plan of further treatment.

Conflict of Interest: None.

Reference

1. R. T. Sataloff, "Common Medical Diagnoses and Treatments in Professional Voice Users," in R. T. Sataloff, ed., *Vocal Health and Pedagogy* (San Diego, CA: Singular Publishing Group, 1997;108.
2. W. Lehmann and J. J. Widman, "Nonspecific Granulomas of the Larynx," in J. A. Kirchner, ed., *Vocal Fold Histopathology: A Symposium* (San Diego, CA: College-Hill Press, 1986; 97-107.
3. W. J. Gould, J. S. Rubin, and E. Yanagisawa, "Benign Vocal Fold Pathology Through the Eyes of the Laryngologist," in J. S. Rubin, R. T. Sataloff, G. S. Korovin, and W. J. Gould, eds., *Diagnosis and Treatment of Voice Disorders* (New York: Igaku Shoin). 1995; 146-148.
4. D. G. Hanson, P. L. Kamel, and P. J. Kahrilas, "Outcomes of Anti reflux Therapy for Treatment of Chronic Laryngitis," *Ann Otol Rhinol Laryngology* 1995;104 550-555.
5. R. T. Sataloff, D. O. Castell, P. O. Katz, and D. M. Sataloff, "Reflux Laryngitis and Other Otolaryngologic Manifestations of Laryngopharyngeal Reflux," in R. T. Sataloff, D. O. Castell, P. O. Katz, and D. M. Sataloff, eds., *Reflux Laryngitis and Related Disorders* (San Diego, CA: Singular Publishing Group, 1999; 41-53.
6. Mossallam et al. "Histopathological Aspects of Benign Vocal Fold Lesions Associated with Dysphonia," in J. A. Kirchner, ed., *Vocal Fold Histopathology: A Symposium* (San Diego, CA: College-Hill Press, 1986; 65-80.
7. O. Kleinsasser, *Microscopic and Histologic Appearances of Polyps, Nodules, Cysts, Reinke's Oedema, and Granulomas of the Vocal Cords*, in J. A. Kirchner, ed., *Vocal Fold Histopathology: A Symposium* (San Diego, CA: College-Hill Press, 1986; 51-55.

How to cite this article: Gautam HK, Singh AP, Singh A, Inflammatory granuloma of larynx mimic as malignancy of larynx –A case report and review literature, *J Otorhinolaryngol and Allied Sci* 2019;2(1):31-33