

Mixed malignant mullerian tumor: A rare case report

Naina Kumar^{1,*}, Himani Agarwal²

¹Associate Professor, ²Post Graduate, Dept. of Obstetrics and Gynaecology, ¹All India Institute of Medical Sciences Mangalagiri, Guntur, Andhra Pradesh, ²Maharishi Markandeshwar Institute of Medical Sciences and Research, Ambala, Haryana, India

***Corresponding Author: Naina Kumar**

Email: drnainakumar@gmail.com

Received: 3rd November, 2018

Accepted: 16th January, 2019

Abstract

Malignant mixed mullerian tumour of uterus also called carcinosarcoma is a very rare and also very aggressive type of tumour involving both epithelial and mesenchymal component thus is considered as a metaplastic carcinoma. Common presentation of these patients is post-menopausal bleeding with uterine enlargement. Here we present the case of 55 year old women with post-menopausal bleeding. Total abdominal hysterectomy with good vaginal cuff with bilateral salpingo-oophorectomy with bilateral pelvic lymphadenectomy was done and a diagnosis of malignant mixed mullerian tumour with Genital Tuberculosis was made.

Keywords: Mixed Malignant Mullerian Tumor.

Introduction

Carcinosarcomas though rare, represents less than 5% of all uterine tumours,¹ and account for 16.4% of all deaths caused by uterine malignancy.² It is a biphasic neoplasm as it has both epithelia and mesenchymal component. It is divided into 2 histological subtypes, homologous and heterogeneous. Homologous; where the sarcomatous component is made up of endometrial stroma and fibrous or smooth muscle tissue, and heterogeneous where the sarcomatous component is made up of cartilage, skeletal muscle and/or bone.³ Here we report a rare case of malignant mixed mullerian tumour of uterus of homologous type with genital Tuberculosis.

Case Report

55 year old P6L6 post-menopausal women since 8 years presented to the outpatient department of Obstetrics and Gynaecology of rural tertiary care centre of Northern India with complaints of heavy bleeding per vaginum since 1 year. There was no associated history of any pain in abdomen or lump in abdomen. She was previously showing to some private practitioner, from where she received symptomatic treatment, but got no relief.

On general examination, the patient was calm, conscious well oriented to time place and person, average in built with pallor present. There was no icterus, oedema or generalized lymphadenopathy. On abdominal examination, abdomen was soft and non-tender with no obvious lump or mass seen or felt. No organomegaly was felt and there was no lymphadenopathy. On local examination, an isolated growth of 3x2 cm was present over the inner upper aspect of left sided labia minora. It was friable in nature. On per speculum examination, cervix was found to be hypertrophied. A fleshy highly vascular, fungating, polypoidal growth of size 4x5 cm was seen coming through the os which was bleeding on touch. On vaginal examination, uterus was erect, 12-14 week in size. Mobility was slightly restricted, bilateral parametrium were free, and

no adenexal mass was felt in either of the fornices. Pap smear was taken which revealed squamous cell carcinoma. On per rectal examination, rectal mucosa and parametrium were free.

The outside ultrasound of patient revealed bulky uterus 11x10cms with normal bilateral adenexa. Magnetic resonance imaging (MRI) was advised which showed cystic adenomyosis with adenomatous polyp prolapsing through cervix. Also, uterus was markedly bulky with multiple large cystic areas with haemorrhagic content appearing hyperintense. Largest haematoma measured 5.2x3.4cms. So fractional curettage along with the biopsy of isolated vulval growth was done which revealed poorly differentiated malignant tumour (Fig. 1). After all the blood investigations and pre-anaesthetic check-up the patient was posted for exploratory laprotomy. The intra-operative findings were uterus was uniformly enlarged upto 14 week size with bilateral tubes and ovaries normal. Peritoneal fluid was taken and sent was cytological examination. There was no enlargement of bilateral Pelvic or Para-aortic lymph nodes. A total abdominal hysterectomy with good vaginal cuff with bilateral salpingo-oophorectomy with bilateral pelvic lymphadenectomy was done and the specimen was sent for histopathological examination.

On gross examination the uterus was 14 weeks size, on cut section the whole of the myometrium was replaced by fungating friable growth with areas of massive haemorrhage and necrosis in between. A growth was identified originating from the endometrium and obliterating it and protruding out of cervical canal, measuring 10.5x6x4.5 cms. The growth was seen to be infiltrating focally more than half of the myometrium, with an invasion depth 1.9cms. Bilateral tubes and ovaries were normal on naked eye appearance (Fig. 2). Microscopic examination revealed tumour cells of polygonal to oval shape with focal spindling in sheets, exhibiting moderate to marked nuclear pleomorphism, bizarre nuclei, tumour giant cells and moderate to abundant amount of eosinophilic cytoplasm.

Brisk mitosis was found. Many necrotizing epitheloid cell granulomas were present (Fig. 3).

Tumour cells were found to be immunopositive for Epithelial Membrane Antigen (EMA) while negative for Pan Cytokeratin (Pan-CK). Features suggested of carcinosarcoma (Malignant Mixed Mullerian Tumour) which was poorly differentiated. Bilateral ovaries, fallopian tubes, vaginal cuff and pelvic lymph nodes were not involved. The final histological opinion was carcinosarcoma (malignant mixed mullerian tumour) with necrotizing

granulomatous inflammation, suggestive of tuberculosis (stage PT3bNoMx). The post-operative period was uneventful and the patient tolerated the surgery well. The patient was planned for adjuvant chemoradiotherapy for 6 cycles of paclitaxel 180mg and carboplatin 450mg along with anti-tubercular treatment category 1 according to direct observation treatment short course (DOTS).

The patient tolerated the full course of chemoradiotherapy well and is coming to Gynaecological OPD for regular follow-up.

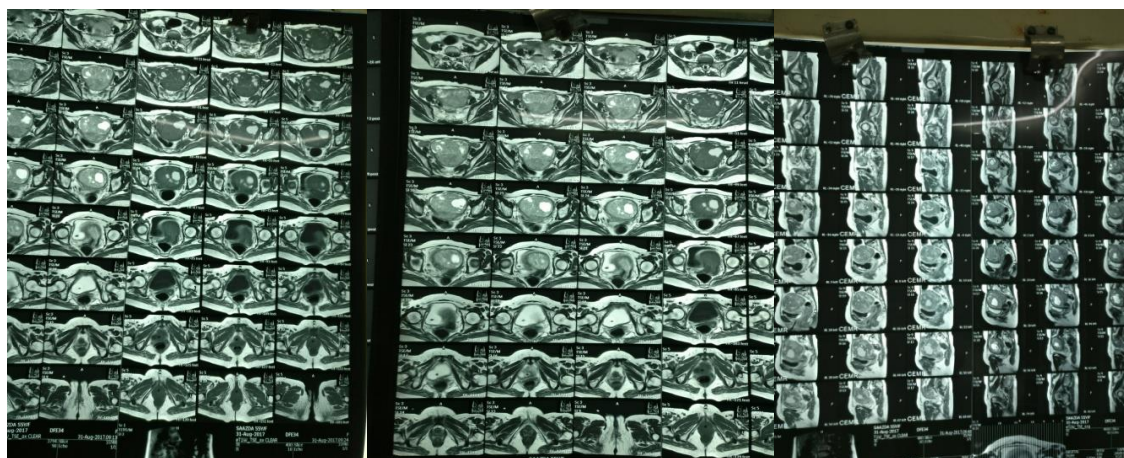


Fig. 1

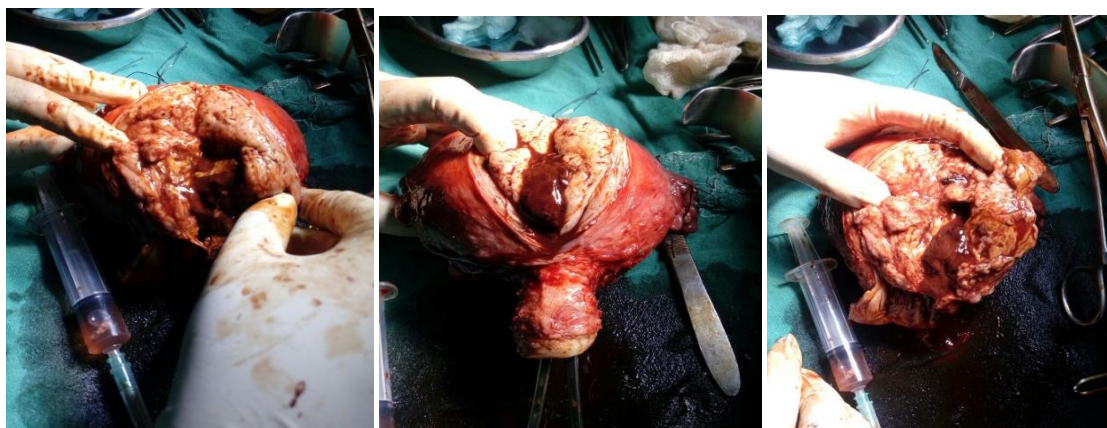


Fig. 2

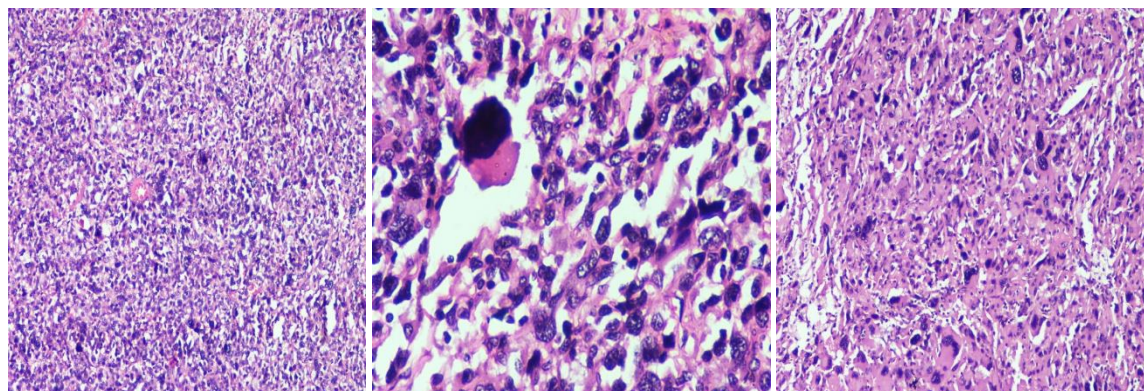


Fig. 3

Discussion

Malignant Mixed Mullerian Tumour is a high grade neoplasm accounting for 2-5% of tumors derived from the body of uterus.³ Risk factors for its development are nulliparity, advanced age, obesity, exposure to exogenous estrogens, and long term use of tamoxifen (increases the risk by 2-7 times).^{4,5} On the contrary, oral contraceptives are reported to be protective against it.

The classical triad of symptoms that is indicative of malignant mixed mullerian tumor consists of pain, heavy vaginal bleeding, and passage of necrotic tissue per vaginum. In this case, patient presented with heavy post-menopausal bleeding. Most of the patients present in 5th decade of life but lowest age of presentation at 15-17 years have been reported.⁶ In our case, the patient was a 55 year old female.

Malignant Mixed Mullerian tumor is divided into 2 histological subtypes, homologous and heterogeneous, depending on the sarcomatous part of the tumor.² The subtypes occur in equal frequency. In our case, endometrial adenocarcinoma with homologous type was seen.

Grossly, tumor presents as large, soft, broad based and polypoid mass which involves the endometrium and myometrium with fleshy surfaces. Areas of necrosis and haemorrhage are commonly seen.

Surgical management includes total abdominal hysterectomy with bilateral salpingo-oophorectomy with bilateral pelvic lymphadenectomy followed by either chemoradiotherapy or radiotherapy. Multiple chemotherapeutic regimens have been studied, with response rate ranging from 12-100%.⁷

In our case, total abdominal hysterectomy with good vaginal cuff with bilateral salpingo-oophorectomy with bilateral pelvic lymphadenectomy was done. Post-operatively, the patient received 6 cycles of chemoradiotherapy along with anti-Tubercular Treatment category 1 according to DOTS and is being followed regularly on OPD basis.

Conclusion

Post-menopausal bleeding should always raise a high suspicion in the mind of the clinician. Though MMT is a rare disease, surgery is the only treatment. The prognosis of patient primarily depends on the extent of disease, the mitotic index and the time of diagnosis. Maximum diameter more than 5cm of tumour has a bad prognosis.

Conflict of Interest: None.

References

1. T. Banik, D. Halder, N. Gupta and P. Dey. Malignant mixed mullerian tumour of the uterus: diagnosis of a case by fine needle aspiration cytology and review of literature, *Diagn Cytopathol* 2012;40(12):653-657.
2. N.K. Sharma, J.I. Sorosky, D Bender, M.S. Fletcher, and A.K.Sood, "malignant mixed mullerian tumour of the cervix. *Gynaecol Oncol* 2005;97(2):442-445.
3. Tekwani DT, Joshi SR, Pathak S, Nagare M, Bihade A, Kendre d. Malignant Mixed Mullerian Tumour of the uterus: a case report. *Ind J Basic Appl Med Res* 2003;3:3-6.
4. R.A.de Jong, H.W. Nijman, T.F. Wijibrandi, A.K. Reyners, H.M. Boezen, and H. Hollema. Molecular markers and clinical behaviour of uterine carcinoarcomas: focus on the epithelial tumour components. *Modern Pathol* 2011;24(10):1368-1379.
5. P. Arora, S. Rao, N. Khurana, D. Talwar and R. Talwar. Malignant mixed mullerian tumour of broad ligament with synchronous ovarian and endometrial carcinoma: a rare association. *J Cancer Res Ther* 2011;7(1):88-91.
6. Barani K, Padmavathi R. Two rare cases of malignant mixed mullerian tumor. *Internet J Pathol* 2013;15:1-8.s
7. Thawal YA, Tambe SG, Tania A, Chavan RR, Patel JA. A rare case of malignant mixed mullerian tumor of uterine corpus. *Int J Med Appl Sci* 2014;3:100-102.

How to cite this article: Kumar N, Agarwal H. Mixed malignant mullerian tumor: A rare case report. *Indian J Obstet Gynecol Res* 2019;6(1):105-107.