

## A successful management of ileal volvulus in pregnancy

C Mamatha<sup>1\*</sup>, M. G. Dhanalakshmi<sup>2</sup>, K.S. Rajeswari<sup>3</sup>

<sup>1</sup>Post Graduate, <sup>2,3</sup>Professor, <sup>1,2</sup>Dept. of Obstetrics and Gynaecology, <sup>3</sup>Dept. of General Surgery, Sriramachandra Institute of Higher Education and Research, Chennai, Tamil Nadu, India

**\*Corresponding Author: C Mamatha**

Email: mamatha.cjs20@gmail.com

Received: 9<sup>th</sup> October, 2018

Accepted: 28<sup>th</sup> January, 2019

### Abstract

The detection of small bowel volvulus becomes strenuous as the symptoms resemble the pregnancy related symptoms. Early recognition of small bowel obstruction in pregnancy is crucial for affording a timely intervention as it is related with high maternal morbidity and mortality. We report a successful management of a 37 year old second gravida at 12 weeks of gestation who presented to us with acute pain abdomen and vomiting. Ultrasound abdomen revealed dilated bowel loops with inter loop fluid collection and sluggish bowel peristalsis. Diagnostic laparoscopy was proceeded which revealed a gangrenous ileal volvulus. The patient underwent a successful right limited hemicolectomy. Her Antenatal period was uneventful and she delivered a live term healthy baby.

**Keywords:** Small bowel obstruction, Ileal volvulus, Gangrenous bowel, Acute pain abdomen, Laparotomy.

### Introduction

Intestinal obstruction occur due to adhesions (54.6%), intestinal torsion (25%), colorectal carcinoma (3.7%), hernia (1.4%), appendicitis (0.5%) and others (10%).<sup>6</sup>

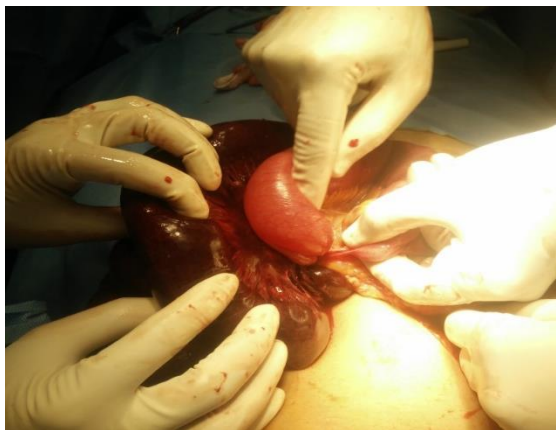
Volvulus is a closed loop mechanical bowel obstruction. It occurs as a result of abnormal twisting of a loop of bowel more than 180 degree around the axis of its own mesentery. The usual site of volvulus being the Sigmoid colon.<sup>1,2</sup> Volvulus of small bowel is rare. The incidence of volvulus in pregnancy is reported as 1 in 1,500 to 1 in 66,000 deliveries.<sup>3</sup>

Volvulus is most common between 16 to 20 weeks of pregnancy when the uterus becomes the abdominopelvic organ and at term when the engagement of presenting part occurs. Presenting symptoms include acute abdominal pain with distension, vomiting and constipation. Imaging such as Ultrasonography and MRI aid in diagnosing small bowel volvulus and are considered safe in pregnancy. Diagnostic laparoscopy should be performed to confirm the diagnosis. We report a case of a successfully managed gangrenous ileal volvulus in pregnancy.

### Case Report

A 37 year old lady, Gravida 2, Para 1, Live 1 at 12 weeks of gestation, with a previous history of term caesarean section done 2 years back reported to our casualty with a history of diffuse abdominal pain for the past 36 hours and an episode of bilious vomiting with constipation for the past 3 days. On general examination, her vitals were stable. Perabdominal clinical examination demonstrated an abdominal distention more evident on left side of abdomen. Diffuse abdominal tenderness was noted with local guarding to the left abdomen. Bowel sounds were sluggish. Obstetric examination was normal. Rectum was empty on examination. Admission Laboratory investigations showed Leucocytes of 11,900 cells /mm<sup>3</sup> with 80% poly and Hematocrit of 36%. All other blood parameters were

normal. Surgeons consultation was obtained. Patient was managed conservatively by keeping her Nil per oral, Ryle's tube application for decompression and Intravenous fluids. NT scan done was normal. There was a gradual deterioration in the general condition of the patient later. Her repeat leucocyte count was raised 18,800 cells /mm<sup>3</sup> with 92% polymorphs and an raised C-reactive protein of 6.2 mg/dL. A Transabdominal ultrasonography revealed a dilated small bowel loops with sluggish peristalsis and mild interloop fluid with free fluid in the pouch of Douglas. Patient underwent an emergency diagnostic laparoscopy, which revealed a gangrenous ileal volvulus. Hence the procedure was converted into emergency laparotomy through a midline vertical incision. A total volvulus torsion (360°) was noted at the terminal ileum adjacent to the valve of varolius (Fig. 1). A gangrenous change in the ileum about 30 cm in length involving the caecum was noted. Adhesion bands were seen at the ileocolic region. No bowel perforation was noted. The gangrenous bowel was resected and right limited hemicolectomy was performed with end-to-end ileotransverse anastomosis using staplers and mesentery was closed with 2-0 vicryl. A thorough peritoneal wash was given and patient was covered with appropriate antibiotics perioperatively. Postoperative period was uneventful. The histopathology report showed a gangrenous ileum and caecum. On gross examination. The resected specimen measured 90 cm and diffuse hemorrhage was noted. Only 5 cm of the resected ileum appeared normal while the remaining ileal mucosa was diffusely eroded with gangrenous change. Later a repeat ultrasonography was done to confirm the wellbeing of the pregnancy. Her antenatal period was uneventful and she delivered a live healthy male neonate at 38 weeks of gestation by a repeat elective lower segment caesarean section.



**Fig. 1: Gangrenous ileal volvulus**

### Discussion

Midgut volvulus is a rare complication of pregnancy occurring more commonly in second and third trimester. Since the past two decades, Less than fifteen cases of small bowel volvulus in pregnancy have been reported.<sup>13</sup> The severity of abdominal pain depends on the duration of vascular compromise but is not related to the degree of bowel obstruction. In our case report, patient presented to us unusually at an early second trimester, the diagnosis of small bowel obstruction was made only after imaging and was confirmed as gangrenous ileal volvulus only after diagnostic laparoscopy and an adhesive band was noted at ileocolic region on laparotomy. Previous history of abdominal surgeries are prone to intestinal obstruction in pregnancy. The incidence of Adhesive intestinal obstruction is more common nearing term (6% - I trimester, 28% - II trimester, 45% - III trimester, 21% - puerperium).<sup>4-6</sup> The maternal mortality associated with small bowel volvulus has been reported as high as 42–67%.<sup>10-12</sup> Ischemia and gangrene of intestine due to volvulus can be prevented by an early diagnosis with imaging and an appropriate surgical treatment. Tocolytics can be administered if preterm labour is suspected postsurgery.<sup>8,9</sup> Unal et al presented a 20 case series of acute pain abdomen in pregnancy where the Ultrasonography findings were consistent with surgical findings in only 55%, whereas MRI was successful in 83%.<sup>7</sup>

### Conclusion

An early referral with a critical team approach involving surgeons and obstetricians is crucial to curtail maternal and fetal morbidity and mortality. An early surgical intervention is recommended in making an appropriate diagnosis through laparoscopy and providing a prompt treatment through laparotomy.

**Conflict of Interest:** None.

### References

1. Ghebrat K. Trend of small intestinal volvulus in north western Ethiopia. *East Afr Med J* 1998;75:549-552.
2. Duke JH, Yar MS. Primary small bowel volvulus: Cause and management. *Arch Surg* 1977;112:685-688.

3. Connolly MM, Unti JA, Nora PF – Bowel obstruction in pregnancy. *Surg Clin North Am* 1995;75:101–113.
4. A. Kulusari, M. Kurdoglu, E. Adali, R. Yildizhan, H. G. Sahin, and C. Kotan - Sigmoid volvulus in pregnancy and Puerperium: a case series. *Cases J*, 2009;2(9):9275.
5. P. W. Perdue, H. W. Johnson, and P. W. Stafford. Intestinal obstruction complicating pregnancy. *Am J Surg*, 1992;164(4):384–388.
6. A. Gaikwad, D. Ghongade, and P. Kittad. Fatal midgut volvulus: a rare cause of gestational intestinal obstruction. *Abdominal Imaging* 2010;35(3):288–290.
7. A. Unal, S. E. Sayharman, L. Ozel. Acute abdomen in pregnancy requiring surgical management: a 20-case series. *Eur J Obstet Gynecol Reprod Biol* 2011;159(1):87–90.
8. T. Kuwahata, I. Iwamoto, T. Fujino, and T. Douchi. Mechanical ileus in a pregnant woman at term pregnancy accompanied by labor pains. *J Obstet Gynaecol Res* 2007;33(4):549–551.
9. K. R. Birchard, M. A. Brown, W. B. Hyslop, Z. Firat, and R. C. Semelka. MRI of acute abdominal and pelvic pain in pregnant patients. *Am J Roentgenol* 2005;184(2):452–458.
10. Fenn SS, Kuruvilla JT. Small bowel volvulus. *Indian J Surg* 1964;26:270.
11. Sankaran V. Volvulus in South India. *Indian J Surg* 1962;24:784.
12. Andersen DA. Volvulus in Western India; a clinical study of 40 cases, with particular reference to the conservative treatment of pelvic colon volvulus. *Br J Surg* 1956;44:132.
13. Ojha OZ. Volvulus of small intestine. *Am J Surg* 1973;126:661-664.

**How to cite this article:** Mamatha C, Dhanalakshmi MG, Rajeswari KS. A successful management of ileal volvulus in pregnancy. *Indian J Obstet Gynecol Res* 2019;6(1):108-109.