

Rapidly progressing bilateral proptosis in a young boy as initial manifestation of acute myeloid leukemia

Neha Singh^{1,*}, S.K. Satsangi², Himanshu Kumar³

¹Assistant Professor, ²Professor, ³Professor and Head, ¹⁻³Department of Ophthalmology, ¹KD Medical College and research Institute, Mathura, ^{2,3}SN Medical College, Agra, Uttar Pradesh, India

Corresponding author: Neha Singh

Email: nhsngh.89@gmail.com

Abstract

We present a case of 10 year old boy who came to us with rapidly progressing bilateral proptosis. Computed tomography showed ill defined homogenous mass in bilateral orbits. Total leucocyte count was raised and peripheral smear showed presence of blasts confirming diagnosis of acute myeloid leukaemia. This case of ours highlights that leukaemia is an important differential diagnosis in children presenting with bilateral proptosis. Along with orbital imaging peripheral blood smear is a useful and inexpensive tool to aid in early diagnosis of the disease and for eventual favourable outcome.

Keywords: Proptosis, Acute myeloid leukemia, Peripheral smear.

Introduction

Acute myeloid leukaemia (AML) accounts for nearly 15% of all leukemias in children.¹ Any extramedullary site can be infiltrated by these leukemic cells, the tumorous accumulations being named granulocytic sarcoma. Granulocytic sarcoma [GS] of orbit is an unusual manifestation of AML accounting for about 3% cases.² The natural history of these tumours can be variable. They can present prior to, concomitantly or even during remission of systemic leukaemia.^{3,4} A patient with orbital GS without any known haematological malignancy presents a diagnostic challenge for the physician. In cases where the orbital tumour is the initial manifestation, peripheral blood and bone marrow involvement usually occurs within a year of the occurrence of orbital disease. Alternatively the tumour can also develop in an established case of systemic leukaemia.

We report a case of bilateral proptosis in a young male who was subsequently diagnosed to have AML on the basis of peripheral smear.

Case Report

A 10 year old boy presented with sudden onset and rapidly progressing protrusion of eyes from 10 days. He also gave history of occasional fever from 1 month. On general examination patient appeared to be lean built and was conscious and oriented. There was no organomegaly and

lymphadenopathy. On ocular examination there was bilateral proptosis and visual acuity was 6/6 in both eyes. On palpation firm ill defined swelling was felt below brow in right eye which had pushed the right eyeball downwards (Fig. 1). Ocular motility was limited in upgaze in right eye. Fundus examination was normal in both eyes. CT scan revealed an evidence of a uniform, ill defined lesion occupying the orbit. (Fig. 2). Based on these clinical features differential diagnosis of leukemia, lymphoma, metastatic neuroblastoma and orbital pseudotumor were made.

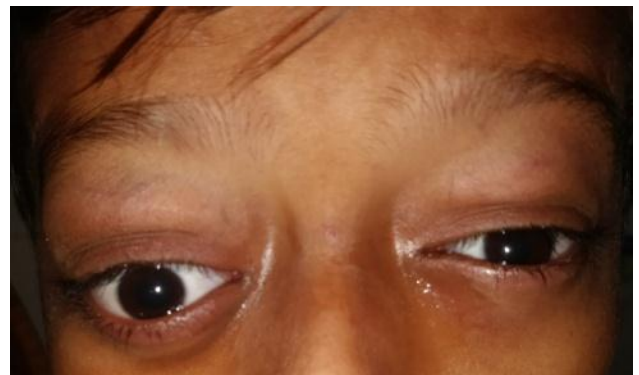

Fig. 1: Bilateral proptosis and mass below brow in right eye causing inferior dystopia of right eye.

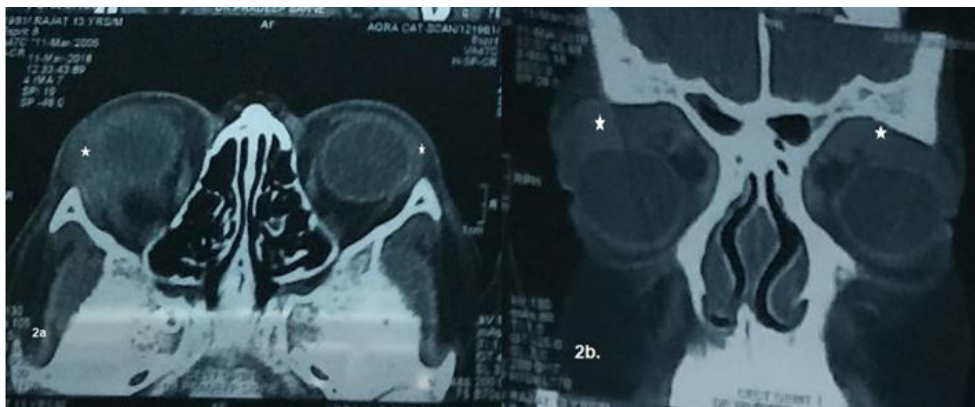


Fig. 2: CT scan (2a.axial view, 2b coronal view) showing mass in bilateral orbits. (☆)

Initial hematological investigations revealed blood cell count of $22.9 \times 10^3/\mu\text{L}$, with a differential count of 4% segmented neutrophils, 51% lymphocytes, 18% monocytes, 5% promyelocytes, and 22% blast cells (Fig. 3), which was strongly suggestive of leukaemia. No anaemia or thrombocytopenia was found. Serum chemistry studies disclosed a markedly elevated lactate dehydrogenase level of 1100 U/L. On the basis of above findings diagnosis of AML was confirmed. Due to rapid worsening of patient's symptoms he was referred to pediatric oncology department for initiation of treatment.

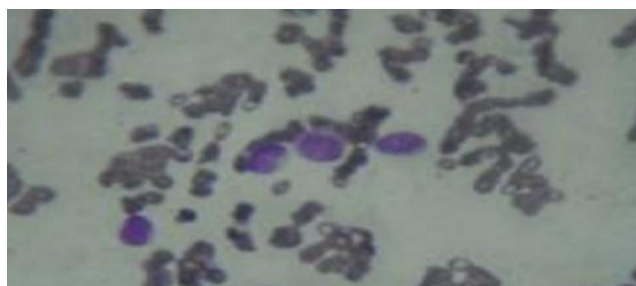


Fig. 3: Peripheral smear showing presence of blasts.

Discussion

When faced with orbital mass in a child, the ophthalmologist should consider a variety of benign and malignant conditions like dermoid cyst, capillary hemangioma, lymphangioma and idiopathic orbital inflammation.⁵⁻⁷ Most of these conditions present in one orbit.^{5,6} Benign conditions like dermoid cyst, capillary hemangioma and lymphangioma are mostly unilateral. Rhabdomyosarcoma the most common malignant orbital tumor of childhood is also usually unilateral.⁷

The main considerations in children presenting with bilateral orbital masses are idiopathic nongranulomatous orbital inflammation,⁸ metastatic neuroblastoma,⁹ and myeloid sarcoma. Pediatric idiopathic nongranulomatous orbital inflammation is initially unilateral in 10% of cases, but it can eventually show bilateral involvement in 46%.⁸ The involvement of the second eye is usually sequential and not simultaneous. Orbital metastasis is the initial sign of abdominal neuroblastoma in 3% to 4% of patients and is bilateral in 50%.¹⁰

Our patient had bilateral orbital involvement. Although granulocytic sarcomas are relatively uncommon pediatric tumor it becomes a major diagnostic consideration in presence of bilateral orbital involvement. Literature shows 60-80% of orbital granulocytic sarcomas are bilateral.¹¹

Evaluation of the peripheral smear was an invaluable tool in the diagnosis in our patient. Previous reports have highlighted the role of this inexpensive investigation in all cases of childhood proptosis.^{12,13} The peripheral smear reveals the presence of immature blast cells. The total leucocyte count is usually high with a relative neutropenia. Bone marrow examination and flow cytometry confirms the diagnosis. In presence of normal peripheral smear biopsy of the mass aids in diagnosis. Prognosis of patients with granulocytic sarcoma depends on status of systemic malignancy. Chemotherapy is the mainstay of treatment. Initiating early treatment can improve the prognosis and the eventual outcome. Hence it is important to diagnose these cases early.

Thus to conclude granulocytic sarcoma is an important cause of bilateral childhood proptosis. A peripheral blood smear is a useful and inexpensive tool to aid in early diagnosis of the disease and for eventual favourable outcome.

Conflict of Interest: None.

References

- Stein-Wexler R, Wootton-Gorges SL, West DC: Orbital granulocytic sarcoma: an unusual presentation of acute myelocytic leukemia. *Pediatr Radiol* 2003;33(2):136-139.
- Stockl FA, Dolmetsch AM, Saornil MA: Orbital granulocytic sarcoma. *Br J Ophthalmol* 1997;81:1084-1088. 10.1136/bjo.81.2.084.
- Davis JL, Park DW, Font RL: Granulocytic sarcoma of the orbit. A histopathologic study. *Ophthalmol* 1985;92:1758-1762.
- Zimmerman LE, Font RL: Ophthalmic manifestations of granulocytic sarcoma (myeloid sarcoma or chloroma). The Third Pan American Association of Ophthalmology and Journal of Ophthalmology Lecture. *Am J Ophthalmol* 1975;80:975-990.
- Bullock JD, Goldberg SH, Rakes SM: Orbital tumors in children. *Ophthalm Plast Reconstr Sur* 1989;5:513-516.

6. Shields JA Bakewell BAugsburger JDonoso LA Bernardino V Space-occupying orbital masses in children: a review of 250 consecutive biopsies. *Ophthalmol* 1986;93:379-384Google Scholar Crossref
7. Shields CL Shields JAHonavar SG Demirci H The clinical spectrum of primary ophthalmic rhabdomyosarcoma. *Ophthalmol*
8. Mottow LS Jakobiec FA Idiopathic inflammatory orbital pseudotumors in childhood, I: clinical characteristics. *Arch Ophthalmol*. 1978;96:1410- 1417Google Scholar Crossref
9. Albert DMRubenstein RAScheie HG Tumor metastases to the eye, II: clinical studies in infants and children. *Am J Ophthalmol*. 1967;63:727- 732Google Scholar
10. Musarella MChan HSLDe Boer GGallie BL Ocular involvement in neuroblastoma: prognostic implications. *Ophthalmology*. 1984;91:936- 940
11. Shields JA, Stopyra GA, Marr BP. Bilateral Orbital Myeloid Sarcoma as Initial Sign of Acute Myeloid Leukemia: Case Report and Review of the Literature. *Arch Ophthalmol* 2003;121(1):138. doi:10.1001/archophth.121.1.138
12. Sethi A, Ghose S, Gujral S, Jain P, Kumar R: Childhood proptosis: the invaluable but overlooked peripheral blood smear. *Indian J Ophthalmol*. 2001, 49 (2): 121-3.
13. Panda A, Dayal Y: Acute proptosis in myeloid leukaemia. *Indian J Ophthalmol* 1984;34:239-241.

How to cite this article: Singh N, Satsangi SK, Kumar H, Rapidly progressing bilateral proptosis in a young boy as initial manifestation of acute myeloid leukemia, *Int J Ocul Oncol Oculoplasty*. 2019;5(1):41-43