

## Assessment of angle of anterior chamber with SD-OCT in patients presenting to tertiary health care center

Nida Khan<sup>1\*</sup>, Saroj Gupta<sup>2</sup>, Prakash Agrawal<sup>3</sup>

<sup>1</sup>Assistant Professor, <sup>2</sup>Additional Professor, <sup>3</sup>Associate Professor, Dept. of Ophthalmology, <sup>1</sup>Indian Institute of Medical Sciences & Research Center, Maharashtra, <sup>2</sup>All India Institute of Medical Sciences, Bhopal, Madhya Pradesh, <sup>3</sup>RKDF Medical College Hospital & Research Center, Bhopal, Madhya Pradesh, India

**\*Corresponding Author: Nida Khan**

Email: dr.nidak88@gmail.com

### Abstract

**Purpose:** To evaluate the angle of anterior chamber with SD-OCT in patients above 40 years of age presenting to tertiary health care center in central India.

**Materials and Methods:** 120 Consecutive patients (240 eyes) above 40 years of age presenting to ophthalmology OPD of tertiary health care center were enrolled in a cross-sectional study. All patients underwent comprehensive ocular examination with included best corrected visual acuity, slit lamp, fundus, gonioscopy, intraocular pressure (IOP), evaluation of angle (i.e. AOD, TISA, TIA) of anterior chamber with SD-OCT. The duration of study was one year six months.

**Result:** The mean age was 53.94 years. There were 61 males & 59 females. It was noted that mean nasal & temporal AOD was less in females (0.4175  $\mu$ m, 0.4142  $\mu$ m) as compared to males (0.4583  $\mu$ m, 0.4613  $\mu$ m). We found that older people have a narrower anterior chamber angle i.e. from 40-60 years of age mean TIA nasal & temporal was 29.13, 27.53 degree & above 60 years of age mean TIA nasal & temporal was 24.13, 22.63 degrees.

**Conclusion:** We found that AOD is less in female as compared to male. It was also noted that older people have a narrower anterior chamber angle as compared to younger people. The gonioscopy has been considered as the gold standard for characterizing the ACA, but it is contact procedure, subjective and requires the expertise while the OCT is rapid, quantitative, reproducibility, non-contact procedure with less interobserver variability will help us to accurately assess anterior chamber angle.

**Keywords:** Anterior chamber angle measurement, Gonioscopy, Narrow angle, SD-OCT, Normal population.

### Introduction

Angle of anterior chamber assessment is the key to classification and definitive management of glaucoma. Imaging of anterior chamber by various methods such as gonioscopy, ultra-biomicroscopy (UBM), anterior segment OCT (AS-OCT) can be used to understand the anatomy and physiology in patients. Based on this assessment, patients can be identified with narrow or open anterior chamber angles.<sup>1</sup> Optical coherence tomography (OCT) is noncontact imaging technology and relatively newer modality that provides detailed cross-sectional images (tomography) of internal structures in biological tissues. OCT imaging has improved the diagnostic performance to detect angle closure.<sup>2</sup> ASOCT have several advantages over gonioscopy as it is rapid, non-contact (can be used in post-operative cases), quantitative, qualitative, no interobserver variability, reproducible, it provide rapid estimation of the various anterior segment parameters, including corneal thickness, anterior chamber depth and also helps in examination of posterior segment parameters and provide its measurement.

### Materials and Methods

**Material:** 120 Consecutive patients (240 eyes) presenting to ophthalmology out patient department of tertiary health care center were enrolled in a cross-sectional study. All patients underwent comprehensive ocular examination with included best corrected visual acuity, slit lamp, dilated fundus examination, gonioscopy, intraocular pressure (IOP) measured by Goldmann applanation tonometer, evaluation of angle (i.e. AOD, TISA, TIA) of anterior chamber with

SD-OCT was done. The duration of study was one year six months. The data were analyzed by using SPSS 16.0. This study was approved from the research and ethics committee of the institute. Informed consent was obtained.

Inclusion criteria were age >40 years, patients with written informed consent.

Exclusion criteria were patient with Intumescent, mature and hyper mature cataract, high myopia, glaucoma, ocular trauma, major intra ocular eye disease.


**Methods of Evaluation:** Eyes that fulfilled both exclusion and inclusion criteria were selected for analysis. After complete clinical examination details of the patient including age, sex, race (Asian) specific examination modes were selected.

**Method of Measurement of Angle of Anterior Chamber (AOD, TIA, TISA):** Scleral spur identification is the first step for calculating anterior chamber parameters by OCT. Inbuilt digital calipers of Topcon OCT machine are then used to mark a point on posterior corneal surface 500 microns anterior to sclera spur.

Now a transparent plastic sheet is placed on the computer screen and these 2 points (From scleral spur and posterior surface of cornea i.e. 500 microns) are marked on the sheet. Using digital caliper of Topcon OCT Machine a line is drawn perpendicular from posterior corneal point to the surface of iris. This line is AOD 500 (angle opening distance) is measured by machine itself. A line parallel to AOD500 is drawn from sclera spur to surface of iris. The 2 points on the iris are connected to each other. The quadrilateral (trapezoid) thus formed is called TISA

(trabecular iris space area). All these points are marked on the transparent sheet by tracing method. Now the plastic sheet is removed from the screen and using normal scale the lines along cornea and iris are drawn backwards to meet at a point in the angle depth. This defines the apex of anterior

chamber angle and the gives TIA (trabecular iris angle) in degrees measured by protractor. The area of trapezoid (TISA) is measured with the help of applying formula of trapezoid i.e.  $area = (b1+b2/2) h$  where  $b1$  length of 1<sup>st</sup> base  $b2$  is height of 2<sup>nd</sup> base and his height of trapezoid.



**Fig. 1: Method of measurement of angle of anterior chamber**

Fig. 1 description

- a. Scleral spur - observed as an inward protrusion or change in curvature at the inner angle surface.
- b. AOD 500 - line is drawn perpendicular from posterior corneal point to the surface of iris.
- c. TISA - A line parallel to AOD500 is drawn from sclera spur to surface of iris. The 2 points on the iris are connected to each other. The quadrilateral (trapezoid) formed is TISA.
- d. TIA - lines along cornea and iris are drawn backwards to meet at a point in the angle depth. This defines the apex of anterior chamber angle i.e. TIA.

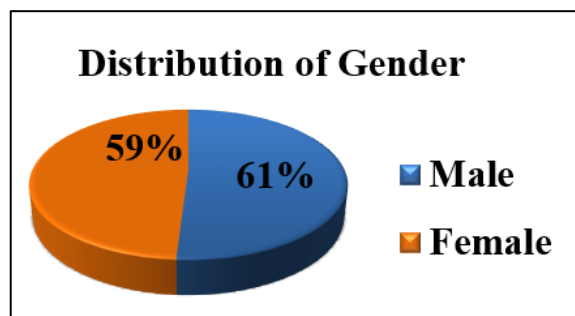
**Result**

**Table 1: Comparison of various parameters of nasal & temporal angle of anterior chamber between different age groups**

	Age Group	Number of eyes	Mean Nasal	Mean Temporal	P value Nasal & Temporal
AOD μm	40-60 Years	124	.4675	.4412	<0.0001 & 0.070
	More Than 60 Years	116	.3797	.3922	
TISA μm	40-60 Years	124	.3883	3922	0.336 & 0.110
	More Than 60 Years	116	.4240	4892	
TIA (Deg)	40-60 Years	124	29.1346	27.5385	<0.0001&<0.0001
	More Than 60 Years	116	24.1354	22.6354	

To study age related changes in anterior chamber by AS-OCT the data was divided into two groups for analysis group 1 from 40-60 years (124 eyes) and group 2 above 60 years (116 eyes). On comparing both the groups mean AOD nasal in group 1 is 0.46 μm and group 2 is 0.37 μm (P value <0.0001), mean TIA nasal in group 1 is 29.13° and in group 2 is 24.13° (P value- <0.0001). In temporal quadrant the mean AOD in group 1 is 0.44 μm and in group 2 is 0.39 μm, mean TIA in group 1 is 27.53° and in group 2 is 22.63°(P value- <0.0001). Therefore with increasing age there is significant narrowing of angle in both nasal and temporal quadrant. (Table 1)

In our study we have studied the AS-OCT parameters among normal subjects and results of 120 subjects (240 eyes) were analyzed. The mean age of subjects was 53.94 years with a SD ± 8.05 years. In our study there were 61 males and 59 females. (Fig. 2)



**Fig. 1**

**Table 2: Mean parameters of nasal and temporal quadrant on OCT**

Parameter	Mean Nasal	Mean Temporal
AOD μm	0.430 ± 0.137	0.433 ± 0.177
TISA μm	0.405 ± 0.261	0.408 ± 0.278
TIA (Deg)	26.904 ± 7.691	26.016 ± 7.781

In our study the mean angle opening distance (AOD) was 0.430 μm in nasal quadrant and 0.433 μm in temporal quadrant. The mean trabecular iris space area (TISA) in nasal quadrant was 0.405 μm and temporal quadrant was 0.408 μm. While the mean trabecular iris angle (TIA) was 26.9° in nasal and 26.01° in temporal quadrant. (Table 2)

**Table 3: Comparison of different parameters on OCT nasal & temporal quadrant between Male and Female subjects**

Parameter	Mean nasal	Mean temporal
AOD μm Male	0.4583	0.4613
AOD μm Female	0.4175	0.4142
TISA μm Male	0.3847	0.4569
TISA μm Female	0.4258	0.4926
TIA (Deg) Male	28.2626	27.3979
TIA (Deg) Female	26.3434	25.5054

On evaluation of AS-OCT parameters, it is noted that mean nasal AOD was less in females (0.4175 μm) as compared to males (0.4583 μm) and similar trend is seen in temporal AOD values (males=0.4613 μm and females=0.4142 μm). Also TIA in degrees was less in females (Nasal=26.34° & Temporal=25.51°) as compared to males (Nasal=28.26° & Temporal=27.39°). (Table 3)

The angle measured (in degrees) by gonioscopy correlated with TIA (in degrees) measured by ASOCT. The value of TIA is measured in degree so that it can be compared with that of gonioscopy. The smaller the value of TIA the shallower will be the angle.

Patients with narrow angles on gonioscopy (<Grade 2 Shaffer’s Grade) had TIA values < 20 degrees on OCT i.e. they were comparable. (Fig. 3)

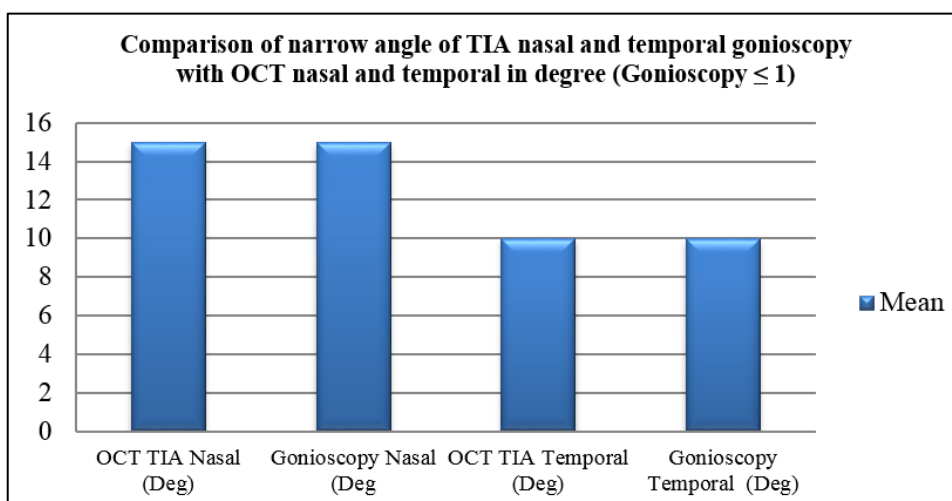


Fig. 3

**Table 4: Comparative data of our study with OCT values from other studies**

	Number of subjects	Quadrant	Mean AOD 500 μm	Mean TISA 500 μm	Mean TIA degree
Present study	120	Nasal	0.43	0.40	26.90
		Temporal	0.43	0.40	26.01
Yuko maruyama	130	Nasal	0.42	0.16	Not done
		Temporal	0.44	0.17	Not done
D S Grewal	265	Nasal	0.48	0.33	Not done
		Temporal	0.49	0.32	Not done
Nishant amersingh	239	Nasal	0.27	0.11	Not done
		Temporal	0.26	0.10	Not done
Sunita radhakrishnan	43	Nasal	0.44	0.15	Not done
		Temporal	0.44	0.17	Not done

These studies help us to conclude that there may be mild variation in values of different study that may be due to racial difference, machine type & different methods of measurement. Large Indian studies will help to give more information. (Table 4)

**Discussion**

Over the last decade there has been an increasing emphasis on newer modalities of anterior chamber imaging such as Anterior Segment OCT and Ultra-biomicroscopy (UBM). These recent technologies can provide useful additional qualitative information with high accuracy

compared to those obtained with the traditional tools such as slit-lamp and gonioscopy. The AS-OCT helps in objective measuring angle of anterior chamber and provides actual readings.

Anterior segment imaging has a vital role in diagnosis and management of glaucoma. Identification of narrow anterior chamber angle is important for glaucoma screening and prophylactic treatment prevents acute angle closure glaucoma event.<sup>1</sup>

On evaluation of AS-OCT parameters, it is noted that mean nasal AOD was less in females (0.4175  $\mu\text{m}$ ) as compared to males (0.4583  $\mu\text{m}$ ) and similar trend is seen in temporal AOD values (females=0.4142  $\mu\text{m}$  & males=0.4613  $\mu\text{m}$ ). In the study of Malay population, angle width measured by AS-OCT was smaller in women than in men. Mean AOD 500 was smaller in women than in men, both nasally (0.255 vs. 0.293 mm,  $P=0.026$ ) and temporally (0.245 vs. 0.286 mm,  $P=0.023$ ).<sup>3</sup> The Beijing Eye study reported the association between age, ACD, and angle characteristics measured with slit lamp AS-OCT. This study found that older people had a narrower anterior chamber angle (measured in degrees) and shallower ACD (measured in millimeters).<sup>4</sup>

Singh A et al in their study of 239 subjects found that mean AOD 500  $\mu\text{m}$  is less in women as compared to men, which is comparable with our study.<sup>5</sup> The Liwan Eye Study, a population-based study in Chinese subjects, also found that women had a narrower iridotrabecular angles as measured by gonioscopy.<sup>6</sup> Most of the studies related to angle closure glaucoma mention that women are more likely to have angle closure attack due to narrow angles.<sup>7</sup>

Yuko Maruyama et al studied an AS-OCT in 130 subjects where they found mean AOD nasal was 0.42  $\mu\text{m}$  and mean AOD temporal was 0.44  $\mu\text{m}$ . While in our study the mean AOD nasal and temporal values are 0.43  $\mu\text{m}$  so, it is showing correlation.<sup>8</sup>

D S Grewal et al did a study using SD-ASOCT (spectral domain ASOCT) in 265 eyes where the mean AOD nasal was 0.48  $\mu\text{m}$  and AOD temporal was 0.49  $\mu\text{m}$ . While the value of TISA nasal was 0.33  $\mu\text{m}$  and temporal was 0.32  $\mu\text{m}$ .<sup>9</sup> These values are correlating with the values of our study (nasal and temporal AOD 0.43  $\mu\text{m}$ , TISA nasal and temporal 0.40  $\mu\text{m}$ ).

Radhakrishnan et al studied 43 subjects and found mean AOD nasal and temporal was 0.44  $\mu\text{m}$  and mean TISA nasal was 0.15  $\mu\text{m}$  and TISA temporal was 0.17  $\mu\text{m}$ .<sup>10</sup>

Amersingh et al in their study of 239 subjects they found mean value of AOD nasal was 0.27  $\mu\text{m}$  and temporal was 0.26  $\mu\text{m}$  while mean TISA nasal was 0.11  $\mu\text{m}$  and TISA temporal was 0.10  $\mu\text{m}$ .<sup>11</sup>

In our study the angle measured (in degrees) by gonioscopy correlated with TIA (in degrees) measured by ASOCT. This is comparable with the study of Nolan WP et al where all patients who have closed angles on gonioscopy also showed closed angles on ASOCT.<sup>12-14</sup>

AS-OCT has been used to image the anterior segment and its utility to identify anterior segment pathologies has been discussed in various studies. However due to lack of

measurement tools(calipers) in OCT machine, in-built software and standard measurement protocols, the parameters such as AOD, TISA and TIA are not discussed in most of these studies. Due to lack of normative data on anterior segment parameters, it is difficult to grade angles on the basis of AS-OCT. Such a grading or cut off value may help us objectively identify subjects with narrow angles which are prone for angle closure attack.

In our study, 8 patients with narrow angles (identified on gonioscopy Grade <2) have AOD values less than 0.33 (cut off value given by Grewal et. al.) Thus our study correlates with the findings of Grewal et al [8].

We collected the normative data values of anterior chamber angle using anterior segment OCT. The mean value of AOD nasal was 0.430  $\pm$  SD, TISA nasal 0.405  $\pm$  SD, TIA nasal 26.90 degree  $\pm$  SD. The mean value of AOD temporal 0.433  $\pm$  SD, TISA temporal 0.408  $\pm$  SD, TIA temporal 26.01 degree  $\pm$  SD.

## Conclusion

Our study is the first study in India done with SD-OCT to give normative data of anterior chamber parameters among normal subjects. These normative values will help us identify patients with abnormal values signifying anterior chamber abnormalities. The advantages of OCT being a rapid, non-contact procedure with less interobserver variability will help us to accurately assess anterior chamber and it can be included as a standard investigation in glaucoma management. Anterior segment imaging plays an important role in diagnosis and management of glaucoma. Identification of narrow anterior chamber angle is important for glaucoma screening and prophylactic treatment prevents acute angle closure glaucoma event. Thus, irreversible loss of sight can be prevented by early diagnosis of suspected cases.

**Conflict of Interest:** None.

## References

1. Claudio Campa, Luisa Pierro, Paolo Bettin. Anterior Chamber Angle Assessment Techniques, Department of Ophthalmology, University Vita-Salute, Scientific Institute San Raffaele, Milan, Italy.
2. H.A. Quigley. Number of people with glaucoma worldwide. *Br J Ophthalmol* 1996;80(5):389–393.
3. Amerasinghe N<sup>1</sup>, Foster PJ, Wong TY. Variation of angle parameters in asians: an anterior segment optical coherence tomography study in a population of singapore malays. *Invest Ophthalmol Vis Sci* 2009;50(6):2626–2631. doi: 10.1167/iovs.08-2582
4. Xu L, Cao WF, Wang YX, et al, Anterior chamber depth and chamber angle and their associations with ocular and general parameters: The Beijing Eye Study. *Am J Ophthalmol* 2008;145(5):929–936.
5. Nishant Amerasinghe, Paul J. Foster, Tien Yin Wong. Variation of Angle Parameters in Asians: An Anterior Segment Optical Coherence Tomography Study in a Population of Singapore Malays Aungl,4,6. *Invest Ophthalmol Vis Sci* 2009;50:2626–2631.

6. He M, Foster PJ, Ge J. Gonioscopy in adult Chinese: The Liwan Eye Study. *Invest Ophthalmol Vis Sci* 2006;47(11):4772–4779.
7. Sihota R, Lakshmaiah NC, Agrawal HC. Ocular parameters in the subgroups of angle closure glaucoma. *Clin Exp Ophthalmol* 2000;28(4):253–258.
8. Yuko Maruyama, Kazuhiko Mori, Yoko Ikeda. Morphological analysis of age-related iridocorneal angle changes in normal and glaucomatous cases using anterior segment optical coherence tomography. *Clin Ophthalmol Auckland, N.Z.* 2014;8:113-118.
9. Grewal DS, Brar GS, Jain R. Comparison of Scheimpflug imaging and spectral domain anterior segment optical coherence tomography for detection of narrow anterior chamber angles. *Eye (Lond)* 2011;25:603–611.
10. Radhakrishnan, S., Goldsmith, J., Huang, D. Comparison of optical coherence tomography and ultrasound biomicroscopy for detection of narrow anterior chamber angles. *Arch Ophthalmol* 2005;123(8):1053-1059.
11. Amerasinghe N<sup>1</sup>, Foster PJ, Wong TY. Variation of angle parameters in Asians: an anterior segment optical coherence tomography study in a population of singapore malays. *Invest Ophthalmol Vis Sci* 2009;50(6):2626-2631. doi: 10.1167/iavs.08-2582
12. Nolan WP, See JL, Chew PT. Detection of primary angle closure using anterior segment optical coherence tomography in Asian eyes. *Ophthalmol* 2007;114:33–39.
13. Wong HT, Chua JL, Sakata LM. Comparison of slitlamp optical coherence tomography and scanning peripheral anterior chamber depth analyzer to evaluate angle closure in Asian eyes. *Arch Ophthalmol* 2009;127:599–603.
14. Leung CK, Li H, Weinreb RN. Anterior chamber angle measurement with anterior segment optical coherence tomography: a comparison between slit lamp OCT and Visante OCT. *Invest Ophthalmol Vis Sci* 2008;49:3469–3474.

**How to cite this article:** Khan N, Gupta S, Agrawal P. Assessment of angle of anterior chamber with SD-OCT in patients presenting to tertiary health care center. *Indian J Clin Exp Ophthalmol* 2019;5(1):66-70.