

Meibomian gland probing in patients with meibomian gland dysfunction

D. Nirupama^{1,*}, B. Hymavathi², L. Prathima³, T. Sanjay Reddy⁴, G. Satyanarayana Reddy⁵

¹⁻³Assistant Professor, ⁴Professor and HOD, ⁵Professor, Dept. of Ophthalmology, Apollo Institute of Medical Sciences and Research, Hyderabad, Telangana, India

***Corresponding Author: D. Nirupama**

Email: drmandiganirupama@gmail.com

Abstract

Purpose: To evaluate the efficacy of Meibomian gland probing for obstructive Meibomian gland dysfunction (O-MGD) using intraductal Meibomian gland probe.

Materials and Methods: 30 patients with Obstructive MGD based on 1. Presence of lid tenderness/ lid margin congestion/ telangiectasia /viscous meibomian gland secretion on slit lamp examination; 2. Tear Film Breakup Time less than 10 seconds; 3. OSDI (Ocular Surface Disease Index) score more than 12, were taken up to intraductal meibomian gland probing. Patients were reviewed after 1 month, 3 months and 6 months. In each visit slit lamp examination was done to see for the improvement of lid margin congestion. TBUT was done and improvement in symptoms were assessed with OSDI questionnaire.

Results: At the end of 6 months 28 patients (93.3%) had improvement in TBUT and OSDI. Lid margin congestion decreased in all the patients. TBUT improved from 5.33 ± 1.56 sec to 9.87 ± 1.56 (p value 0.0001). OSDI score improved from 26 ± 7.49 to 13.5 ± 3.57 (p value 0.0001). 8 patients (26.6%) required retreatment after 3 months.

Conclusion: Intraductal probing had a substantial improvement in lid tenderness, TBUT and provided symptomatic relief for patients with Obstructive-MGD.

Keywords: Dry eye, Meibomian gland probing, Obstructive-meibomian gland dysfunction, Tear film breakup time (TBUT).

Introduction

Meibomian glands are modified sebaceous glands which are present in eyelids. They secrete meibum which contains lipids. This form the superficial layer of tear film and decreases the evaporation of tears.¹

The international workshop on MGD defined the disease as "A chronic, diffuse abnormality of the meibomian glands, commonly characterized by terminal duct obstruction and/or qualitative/ quantitative changes in the glandular secretion". MGD is an under diagnosed and undertreated disease.² The meibomian glands are obstructed because of hypertrophy of ductal epithelium and keratinization. It can be due to due to aging, or decreased expression of androgen receptors, or medications. This results in decreased secretion of meibum into the tear film resulting in obstructive Meibomian gland dysfunction.

Many factors play a role in MGD pathophysiology.³ Systemic factors involved in MGD include aging, androgen deficiency, atopy, menopause, Sjögren syndrome, rosacea. Ophthalmic factors include anterior blepharitis, use of contact lenses, and demodex folliculorum.⁴

Ocular manifestations of MGD include dry eye, lid margin tenderness and heaviness, foreign body sensation, redness. According to the International Workshop on Meibomian Gland Dysfunction the diagnostic workup for patients with MGD is as follows: For patients who are asymptomatic, digital pressure is applied to the central lower lid to assess the quality of meibum secreted from the glands. In symptomatic patients the diagnostic work up for patients with MGD include staining the ocular surface, Tear break up time (TBUT), Schirmer's test: <5 mm/5 min, expressibility of meibum, its quality and Meibography.⁵

Treatment

Primary treatment of MGD involves improving the quality and quantity of meibomian gland secretions. Eyelid hygiene is important in MGD treatment. It consists of two components: Warm compresses and eyelid massage.

Lid scrubs with dilute detergents decrease the seborrheic or bacterial load, thereby breaking the proinflammatory cycle of MGD.⁶ Lipid-containing eyelid sprays have been shown to relieve the symptoms of DED.⁷

Systemic and topical antibiotics are used in the treatment of MGD to reduce the bacterial load on the ocular surface. Systemic doxycycline 100mg B.D. for two weeks have been shown to decrease local inflammation and improve meibomian gland function after several weeks. Azithromycin, a broad-spectrum macrolide antibiotic, has antibacterial action as well as anti-inflammatory properties. It is most commonly prescribed for the treatment of MGD both topically and in oral form.⁹

Oral supplementation with omega-3 essential fatty acids causes improvement in symptoms of dry eye, tear stability in patients with MGD.^{6,9,10}

Despite the numerous treatment options, MGD cannot be completely cured. It is unlikely that a single treatment is the best option for all patients, so newer treatment modalities are needed.

In this study intraductal meibomian gland probing was done in patients with MGD who did not improve with the conventional management for MGD. The aim of intraductal probing is to clear the duct of the obstruction and let the meibum flow, reducing inflammation, and lid congestion with improvement of symptoms.

Materials and Methods

30 patients diagnosed with obstructive MGD were prospectively included in the study. All these patients were on medical treatment for MGD for 8 weeks with no improvement in signs and symptoms. Each patient signed an informed consent form, and local ethics committee approval was obtained.

All the patients underwent slit lamp examination to look for Lid tenderness/lid margin congestion and telangiectasia / expression of viscous meibum on digital pressure to the central lower lid. Tear break-up time (TBUT) was done as follows -Tear film stained with fluorescein was examined under slit lamp biomicroscope with a cobalt-blue light. The time to the appearance of the first dry spot on the corneal epithelium was measured. The average of 3 measurements was calculated and recorded. Values less than 10 seconds were considered to be abnormal. For the schirmer-I test, standard filter paper 35 mm in length and 5 mm in width was placed two-thirds laterally in the lower eyelids without applying topical anaesthesia. Five minutes later, moisture on the filter paper was measured and recorded in millimetres.

Patients were given Ocular Surface Disease Index (OSDI) Questionnaire for symptomatic evaluation of MGD.

The Ocular Surface Disease Index (OSDI), was developed by the Outcomes Research Group at Allergan Inc (Irvine, Calif).¹¹ The questionnaire consists of 12 components designed to assess the symptoms of ocular irritation which are consistent with dry eye disease and their effect on vision-related functioning.

Thus, the OSDI is scored on a scale of 0 to 100, with higher scores representing greater disability.¹⁴

The diagnosis of obstructive MGD was based on

1. Lid tenderness/lid margin congestion and telangiectasia / expression of viscous meibum on digital pressure to the central lower lid on slit lamp examination.
2. TBUT less than 10 seconds and
3. OSDI score more than 12.

The area of eyelid selected to be probed was the one with severe symptoms and with dilated ducts. The patency of gland orifices, length of glands, and signs of ductal dilation were evaluated using IR (Infrared) technique. An orifice that was absent with an atrophic gland was avoided.

Technique of Probing

After deciding the glands to be probed, topical anaesthetic Proparacaine 0.5% (Paracain) was applied as a drop to the inferior conjunctival fornix and allowed to ooze onto the lid margin. After obtaining adequate anaesthesia, intraductal probing was done in all the patients using 4mm sterile stainless steel probe (Maskin Meibomian probe, Rhein Medical). The lid to be probed was placed on tension by sliding to either side using a finger of one hand. With the fellow hand using a pencil type grip on the probe handle, the probe was passed through the orifice perpendicular to the lid margin. Some cases demonstrated epithelial growth across the orifice that on occasion offered mild resistance. Additional force was then used to penetrate through the

resistance. Once relieved of resistance, the probe was able to pass freely without difficulty. At times during probing, haemorrhage was noted at the orifice which was self-contained. After probing, all the patients were prescribed antibiotic eye drops for five days. They were also advised to apply warm compresses on eyelids twice a day for 4 to 5 minutes,¹² and lid massage with a cotton tip applicator to drain secretions.

The patients were reviewed after 1 month, 3 months and 6 months.

At each visit signs of obstructive MGD were observed under slit lamp examination including lid tenderness and lid margin congestion. TBUT and OSDI questionnaire were also done to see for improvement post probing. Conjunctival hyperaemia was rated as +1, mild; +2, moderate; +3, severe; Lid tenderness was graded as 0 if Tenderness is absent and 1 if tenderness is present.

Statistical Analysis

The variables of the groups were presented as mean±standard deviation. The SPSS software, Version24.0 for windows was used for statistical analyses. P <0.01 was considered statistically significant.

Results

Age of the patients ranged from 28 to 51 years, with average age of 39.53 (SD± 11.42) years. The average age of males was 34.7 years (SD±10.24). The average age of females was 42.6 years (SD±11.3). Male to female ratio was 19:11.

22 patients (73%) had improvement in lid margin congestion, TBUT as well as OSDI score by the end of 1st month after the procedure. 8 patients (27%) required reprobing after 3 months. At the end of 6 months 28(93.3%) patients had improvement in TBUT and OSDI score. Lid margin congestion decreased in all the patients.

Patients noted increased comfort in lid excursion. The surface of the eye was smoother and cooler as described by some of them.

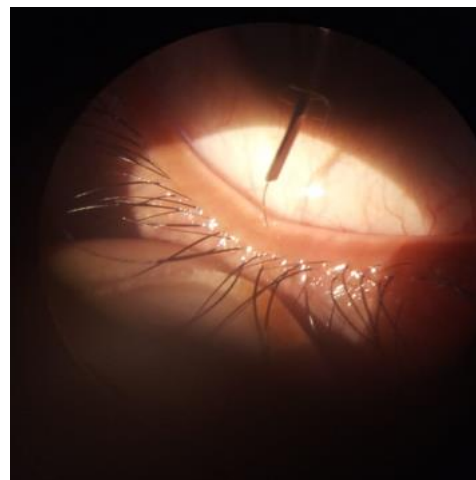


Fig. 1: Showing the meibomian gland probe being passed through the meibomian orifice

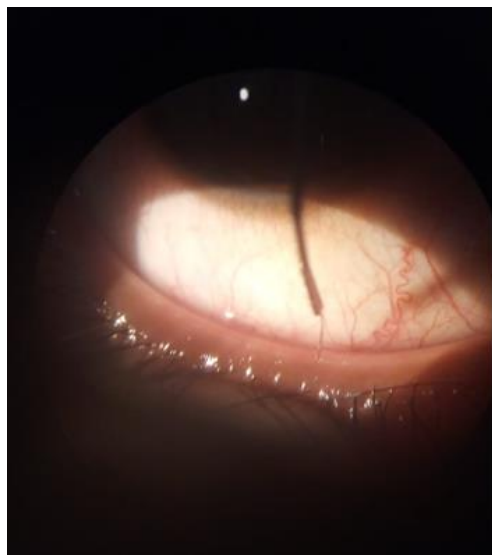


Fig. 2: Showing the meibomian gland probe being passed through the meibomian orifice

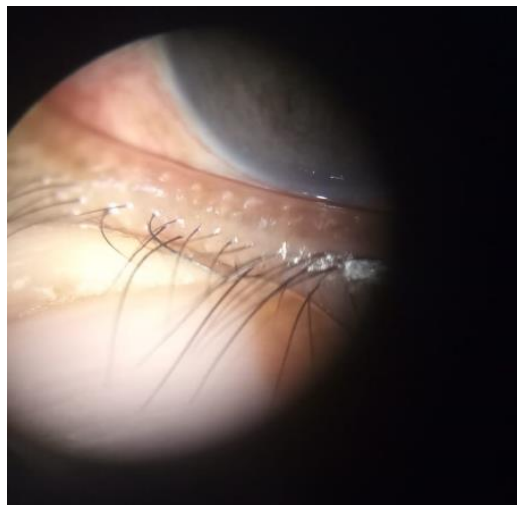


Fig. 3: Viscous secretion from meibomian glands on digital pressure




Fig. 4: Maskins meibomian gland probe

Table 1: OSDI & TBUT results pre and post probing

	Preprobing Mean±S.D	Postprobing Mean±S.D	P-value
OSDI	26±7.49	13.5±3.57	0.0001
TBUT	5.33±1.56	9.87±1.56	0.0001
Significance	P<0.01, Statistically highly significant at 1% Level of Significance		

Discussion

This interventional pilot study has shown that intraductal probing into the meibomian gland duct, with Maskins Meibomian gland probe is safe and reliable. After probing the orifice of the gland becomes patent and the sequestered meibum will release through the orifice. There were no adverse effects on follow-up for over 6 months.

Probing reduces intraductal pressure and removes stagnant abnormal meibum secretions, thus reducing symptoms of lid congestion and inflammation.¹³

A study was done by Maskin et al using Maskins Meibomian gland probe on 25 patients with a diagnosis of MGD, who had hyperemia, telangiectasia, thickening, tenderness, and edema along the eyelid margins. Then the effects of this treatment on tenderness and congestion of the eyelid margin were evaluated. 24 patients (96%) had immediate relief after probing. 20 patients (80%) underwent retreatment and were followed up for an average of 11.5 months.¹³ All the patients had relief of symptoms by 4 weeks after probing.

In another study done by Zuleyha Sik Sarman et al on 30 patients, with modified Maskin probes, showed favorable results on clinical and subjective symptoms.¹⁴

There was statistically significant post procedural decreases in conjunctival hyperemia ($P < 0.0001$) and eyelid margin vascularization ($P < 0.004$). There was a significant improvement in OSDI scores between preprobing and after 3 months.

Conclusion

Meibomian gland probing seems is a safe and effective method in patients with obstructive meibomian gland dysfunction. Following probing there is a significant improvement in signs and symptoms of the patients. However, further studies with long-term follow-up periods are needed.

Conflict of Interest: None.

References

1. Bron AJ, Benjamin L, Snibson GR. Meibomian gland disease. Classification and grading of lid changes. *Eye (Lond)* 1991;5(Pt 4):395-411.
2. J.D. Nelson, J. Shimazaki, J.M. Benitez-del-Castillo, J.P. Craig, J.P. McCulley, S. Den, et al. The international workshop on meibomian gland dysfunction: report of the definition and classification subcommittee. *Invest Ophthalmol Vis Sci* 2011;52:1930-1937.

3. Viso E, Rodriguez-Ares MT, Abelenda D, Oubina B, Gude F. Prevalence of asymptomatic and symptomatic meibomian gland dysfunction in the general population of Spain. *Invest Ophthalmol Vis Sci* 2012;53:2601-2606.
4. Nelson JD, Shimazaki J, Benitez-del-Castillo JM. The International Workshop on Meibomian Gland Dysfunction: report of the Definition and Classification Subcommittee. *Invest Ophthalmol Vis Sci* 2011;52:1930-1937.
5. Tomlinson A, Bron AJ, Korb DR. The International Workshop on Meibomian Gland Dysfunction: Report of the Diagnosis Subcommittee. *Invest Ophthalmol Vis Sci* 2011;52:2006-2049.
6. G. Geerling, J. Tauber, C. Baudouin, E. Goto, Y. Matsumoto, T. O'Brien, et al. The international workshop on meibomian gland dysfunction: report of the subcommittee on management and treatment of meibomian gland dysfunction. *Invest Ophthalmol Vis Sci* 2011;52:2050-2064.
7. S.Y. Lee, L. Tong Lipid-containing lubricants for dry eye: a systematic review. *Optom Vis Sci* 2012;89:1654-1661.
8. J. Qiao, X. Yan Emerging treatment options for meibomian gland dysfunction. *Clin Ophthalmol* 2013;7:1797-1803.
9. F. Brignole, Baudouin, C. Baudouin, P. Aragona, M. Rolando, M. Labetoulle, P.J. Pisella, et al. A multicentre, double-masked, randomized, controlled trial assessing the effect of oral supplementation of omega-3 and omega-6 fatty acids on a conjunctival inflammatory marker in dry eye patients. *Acta Ophthalmol* 2011;89:e591-e597.
10. Walt JG, Rowe MM, Stern KL. Evaluating the functional impact of dry eye: the Ocular Surface Disease Index [abstract]. *Drug Inf J.* 1997;31:1436.
11. Arita R, Morishige N, Shirakawa R. Effects of eyelid warming devices on tear film parameters in normal subjects and patients with meibomian gland dysfunction. *Ocul Surf* 2015;13:321-330.
12. Maskin SL. *Cornea* 2010;29(10):1145-1152.
13. Zuleyha Sik Sarman, Bulent Cucen, Nursen Yuksel, Abdulkadir Cengiz, and Yusuf Caglar. *Cornea* 2016;35(6).
14. Rhett M. Schiffman, Murray Dale Christianson, FRCSC; Gordon Jacobsen. *Arch Ophthalmol.* 2000;118(5):615-621. doi:10.1001/archophth.118.5.615.

How to cite this article: Nirupama D, Hymavathi B, Prathima L, Reddy TS, Reddy GS. Meibomian gland probing in patients with meibomian gland dysfunction. *Indian J Clin Exp Ophthalmol* 2019;5(1):78-81.