

## Study on long term effects and complications of 5-fluorouracil in trabeculectomy

Manjunath D Patil<sup>1</sup>, Jayaramulu H Sankaram<sup>2,\*</sup>

<sup>1</sup>Associate Professor, <sup>2</sup>Professor, Dept. of Ophthalmology, Ashwani Rural Medial College, Hospital & Research Centre, Kumbhari, Solapur, Maharashtra, India

\*Corresponding Author: Jayaramulu H Sankaram

Email: jayaram\_dr@rediffmail.com

### Abstract

**Introduction:** Various survey's reveal that 1-2% of the population over the age of 40 years have glaucoma and its incidence increases with age. It is the third most common cause of blindness next to the cataract and refractive errors. The present study was undertaken to assess long term effects on controlling intraocular tension by trabeculectomy with and without intraoperative use of 5 – fluorouracil.

**Materials and Methods:** The present study was undertaken in the Department of ophthalmology, ARMCH & RC, Kumbhari. In the present study, 50 cases were operated for trabeculectomy by using following two methods – with and without use of 5 – Fluorouracil. Informed written consent under guarded visual prognosis was obtained from all patients.

**Results:** Highest number of patients 17 (34%) were in the age group of 51-60 years, thus confirming that the glaucoma is more common in 6<sup>th</sup> decade. Intraoperative use of 5 – fluorouracil has resulted in stable control of intraocular tension over prolonged period of time while in trabeculectomy without 5 – Fluorouracil there was gradual loss of control of intraocular tension over prolonged period of time.

**Conclusion:** Intraoperative use of 5 – fluorouracil in trabeculectomy is useful an alternative to maintain the intraocular tension in lower teens over prolonged period of time by modifying the conjunctival bleb morphology, without causing any serious corneal complications.

**Keywords:** 5-Fluorouracil, Glaucoma, Intraocular tension, Trabeculectomy.

### Introduction

About 11-12 million Indians over the age of 40 years having glaucoma. Nearly 1.5 million Indians are blind due to glaucoma. In India percentage of blindness due to glaucoma is about 5.8%. It is the third most common cause of blindness next to the cataract and refractive errors. Prevalence of glaucoma is about 2.6 – 4.1% out of which 48% have open angle glaucoma and 33.1% having angle closure glaucoma.

In a country like India, where patient finds it difficult to stick to a strict regime of putting medicines in the eye at frequent intervals for the rest of their lives or are financially handicapped causing inability to buy medicines for a long period of time or do not enjoy the facility of a nearby eye centre for periodic check up. Surgery is preferred to medical treatment in many cases.

Any operation devised for the relief of glaucoma should ideally be such as to preserve the function of the eye, maintain the intraocular tension within normal limits and retain the integrity of the globe.<sup>1</sup> The various types of operations advocated from time to time proved that this idea has never been attained.

Trabeculectomy or removal of trabecular meshwork was first described by Cairns<sup>2</sup> in 1968. He reflected the corneo-scleral flap posteriorly. It allows the aqueous to flow through the now exposed cut ends of Schelmm's canal, and then leave the eye via normal exit channels.

Later in 1970, it was modified by P.G. Watson. He reflected the corneo-scleral flap anteriorly and advised iridectomy in all cases.<sup>3</sup>

It is observed that in trabeculectomy, there is failure to maintain the intraocular tension below target level over a prolonged period of time in eyes which are high risk for surgical failure, such as pseudoexfoliation glaucoma, topical

use of antiglaucoma drugs for more than three years and secondary glaucoma.

To prevent such scarring, intra-operative use of 5 – fluorouracil was first suggested by Heur et al 1984 as subconjunctival injections of 5 – fluorouracil, these subconjunctival injections were associated with serious corneal complications like corneal epithelial defect, ulceration and endophthalmitis.<sup>4</sup> To avoid these complications Doyle J et al first suggested the use of 5-fluorouracil as sponge application between conjunctival flap and sclera.<sup>5</sup>

Keeping above facts in mind, the present study was undertaken to assess long term effects on controlling intraocular tension by trabeculectomy with and without intraoperative use of 5 – fluorouracil.

This study was conducted to assess long term effects on controlling intraocular tension by trabeculectomy with and without intraoperative use of 5 – fluorouracil.

### Materials and Methods

The present study was undertaken in the Department of Ophthalmology, ARMCH & RC, Kumbhari. In the present study, 50 cases were operated for trabeculectomy by using following two methods – with and without use of 5 – fluorouracil. Informed written consent under guarded visual prognosis was obtained from all patients.

**Selection Criteria:** Cases which were diagnosed clinically as having primary glaucoma with raised intraocular tension were randomly selected to receive or not to receive intraoperative 5 – fluorouracil application between conjunctival flap and sclera for 1 minute duration.

Intraocular tension was recorded by using Schiotz tonometer. The success of method was assessed by achieving the mean intraocular tension, which is not harmful to the eye. i.e. less than 20 mmHg post operatively.

Detail history and clinical examination was done. Head posture, forehead, facial symmetry was noted. Detail eye examination was carried out in diffuse illumination with the help of torch. All the structures of the eye were examined in more details with the help of the slit lamp. Every patient was subjected for retinal examination by ophthalmoscopy of both eyes for optic disc changes.

### Surgical Management

Trabeculectomy operation,

1. Trabeculectomy with intra operative use of 5 – Fluorouracil.
2. Trabeculectomy without 5 – fluorouracil.

**5 – Fluorouracil:** The most common cause for failure of filtration surgery is excessive scarring at the filtration site resulting in a non – filtering bleb. 5 – Fluorouracil is a fluorinated pyrimidine analogue, a potent antimetabolic, antimetabolic agent. It competitively inhibits thymidylate synthetase and cell division thereby decreasing the fibroblast proliferation.

**Route of Administration:** To use 50 mg/ml concentration of 5 – Fluorouracil intraoperatively for 1 minute, the surgical sponge soaked in 50 mg/ml concentration of 5 – fluorouracil solution was placed between the conjunctival flap & sclera for 1 minute.

After 5 – fluorouracil application conjunctiva & sclera washed copiously with 20 ml Ringer Lactate solution.

**Procedure:** Procedure was performed under local Anaesthesia Facial and Retrobulbar block.

1. Facial block – 5 ml of 2% Lignocaine with or without adrenaline with hyaluronidase.
2. Retrobulbar block – 3 ml of 2% Lignocaine with or without adrenaline with hyaluronidase.
3. Ocular hypotony was achieved by ocular compression with digital pressure.

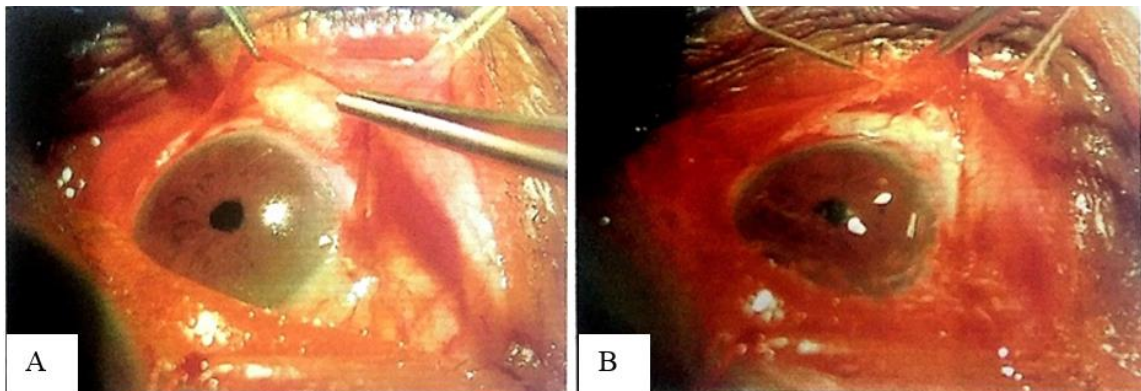
**Trabeculectomy:** Painting & draping was done. Superior rectus suture was taken. A limbal / Fornix based conjunctival flap was raised. A cellular sponge soaked in 50

mg /ml solution of 5 – fluorouracil was placed between conjunctival flap and sclera for 1 minute. After 5 – fluorouracil application conjunctival flap and sclera was copiously washed with 20 ml Ringer lactate solution. Triangular 2/3 thickness 4 mm x 3mm x 3 mm outer scleral flap was raised. Anterior chamber entry was done with 11 number blade & peripheral buttonhole iridectomy performed. An inner block of trabecular tissue 1 mm x 5 mm in size excised. Scleral flap re-apposed with interrupted 10-0 nylon sutures. The conjunctival flap was sutured with 8 – 0 black silk. Subconjunctival injection of gentamicin + dexamethasone + atropine was given in inferior fornix. Chloramphenicol eye ointment was put. Eye pad & shield was given.

**Post-operative Management:** In every patient of trabeculectomy post operatively systemic antibiotics such as capsule. Chloramphenicol 500 mg OID was given for 5 days. As anti-inflammatory drugs T. Prednisolone 10 mg bd was given post operatively. Antacids like T Ranitidine 150 mg bd was given. Every patient was given T. Vit C 500 mg per day. Locally Antibiotic & steroid eye drops was instilled. In cases of severe uveitis subconjunctival gentamicin + wymesone injection was given. Eye examination, visual acuity, funduscopy, slit lamp examination was done daily. Post-operative complications like hyphema, or shallow anterior chamber was treated accordingly.

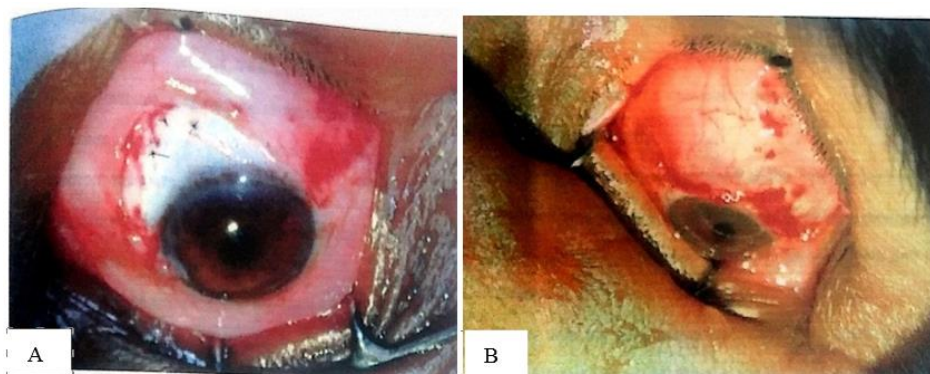
**Follow-up:** All the patients were examined at the time of discharge by routine eye examination, visual acuity funduscopy & slit lamp examination. Every patient was followed up weekly for one month and then monthly for 6 months. Every time the condition of eye, depth of anterior chamber, conjunctival bleb formed was noted.

### Clinical Photographs:



**A:** Surgical sponge soaked in 50 mg/ml concentration of 5-fluorouracil solution kept between conjunctival flap and sclera; **B:** Thorough irrigation of conjunctive and sclera with 20cc Ringer lactate solution

**Fig. 1:** Surgical sponge soaked in 50 mg/ml concentration of 5-fluorouracil solution kept between conjunctival flap and sclera & thorough irrigation conjunctiva and sclera with 20 cc ringer lactate solution



A: Scleral flap sutured with interrupted 8-0 black silk sutures; B: Watertight closure of conjunctival flap done with interrupted 8-0 black silk sutures

**Fig. 2: Scleral flap sutured with interrupted 8-0 black silk sutures & Waterlight closure of conjunctival flap done with interrupted 8-0 black silk sutures**

**Statistical Analysis**

Descriptive statistics such as mean, SD and percentage was used to present the data. Comparison between groups was performed by using t-test for quantitative data and chi-

square test for qualitative data. A p-value less than 0.05 were considered as significant.

**Results**

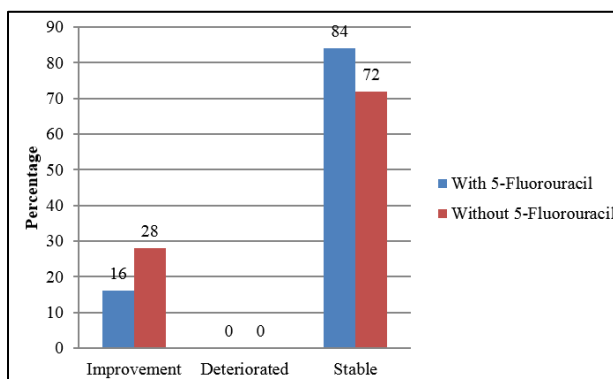
**Table 1: Age wise distribution of patients**

Age in years	Number of patients		Total
	Trab with 5 – fluorouracil	Trab without 5 – fluorouracil	
31 – 40	03	01	04
41 - 50	06	08	14
51 – 60	09	08	17
61 – 70	06	07	13
71 and above	01	01	02
Mean	57.32 ± 8.5	55.28 ± 10.20	
P Value	P > 0.05 Insignificant		

Most of the cases were evenly distributed in the Fifth, Sixth and Seventh decade. The age difference in both the groups was statistically not significant (p>0.05).

**Table 2: Visual acuity status after surgery**

Visual Acuity	Trab with 5 fluorouracil		Trab without 5 - fluorouracil	
	No. of cases	Percentage	No. of cases	Percentage
Improvement	04	16%	07	28%
Deteriorated	-	-	-	-
Stable	21	84%	18	72%



**Fig. 3: Visual acuity status after surgery**

As per above Table & Fig. 1, in Trab with 5 – fluorouracil group visual acuity was improved in 16% patients and was stable in 84% patients. In tab without 5 – fluorouracil group visual acuity was improved in 28%

patients and was stable in 72% patients.

### Control of Intraocular Tension

**Table 3: In trabeculectomy with 5 – fluorouracil**

Follow Up	Intraocular Tension Controlled (Schiotz)				Mean $\pm$ SD
	10-15 mmHg	18-20 mmHg	21-25 mmHg	>26 mmHg	
<b>With 5 fluorouracil</b>					
1 <sup>st</sup> Month	24	--	0	01	13.80 $\pm$ 2.25
2 <sup>nd</sup> Month	23	--	1	1	13.72 $\pm$ 2.57
6 <sup>th</sup> Month	23	--	1	1	13.78 $\pm$ 2.62
<b>Without 5 fluorouracil</b>					
1 <sup>st</sup> Month	20	04	0	01	15.17 $\pm$ 2.36
2 <sup>nd</sup> Month	19	05	01	1	15.47 $\pm$ 2.98
Last Visit	16	08	01	1	15.75 $\pm$ 2.86

About 96% patient in Trab. With 5 – fluorouracil had postoperative intraocular tension of 15 mmHg or less compared to 64% in Trab. Without 5 – fluorouracil group.

5 – fluorouracil patient showed stable control of intraocular tension in low teens post operatively. While gradual loss of intraocular tension control can occur in patients without 5 – fluorouracil over a period of time.

For 1<sup>st</sup> month, the difference noted in the intraocular tension of two groups was statistically significant ( $p=0.04$ ) i.e. patient in the trab with use of 5 – fluorouracil group had low levels of intraocular tension than trab without 5 – fluorouracil. At 1 month 96% success was noted in 5 – fluorouracil group compared to 80% success observed in trab without 5 – fluorouracil group.

For 2<sup>nd</sup> month, the difference noted in the intraocular tension of two groups was statistically significant ( $p=0.03$ ). Further, it is observed that intraocular tension was remained low in the 5 – fluorouracil group. At 2<sup>nd</sup> month 96%

success rate was seen in trab with 5 – fluorouracil group while in case of trab without 5 – fluorouracil success rate was 72% which is reduced from 80% in the 1<sup>st</sup> month. It indicates there was loss of control in 4% cases in trab without 5 – fluorouracil group in maintaining the intraocular tension below 15 mmHg.

For last visit, the difference noted in the intraocular tension of two groups was statistically significant ( $p=0.015$ ). It was observed that, there was constant maintenance of intraocular tension below 15 mmHg in the 5 – fluorouracil group, this occurred because in the trab without 5 – fluorouracil group 9 patients (36%) failed to maintain intraocular tension below 15 mmHg while 2 patient from trab with 5 – fluorouracil failed to control intraocular tension below 15 mmHg.

### Ophthalmoscopic Examination

**Table 4: In trabeculectomy with and without 5 - fluorouracil**

Grades of fundus	Pre-operative	Follow up		
		1 <sup>ST</sup> Month	2 <sup>ND</sup> Month	Last Visit
<b>With 5 – fluorouracil</b>				
WNL	05	05	05	05
0.4 – 0.6 cupping	01	01	01	01
0.7 – 0.9 cupping	10	10	10	10
Glaucomatous optic atrophy	01	01	01	01
Not visualized	08	08	08	08
<b>Without 5 – fluorouracil</b>				
WNL	09	09	09	09
0.4 – 0.6 cupping	01	01	01	01
0.7 – 0.9 cupping	12	12	12	12
Glaucomatous optic atrophy	03	03	03	03

In trab with 5 – fluorouracil group, fundus was visualized in 17 patients, in remaining 8 patients fundus was not visualized due to cataract changes.

In trab without 5 – fluorouracil group, fundus was visualized in all the patients.

None of the patients in both the groups has shown any progression of cupping post – operatively.

## Visual Acuity

**Table 5: In trabeculectomy with and without 5 – fluorouracil**

Follow up	Visual acuity		
	Improved	Deteriorated	Stable
<b>With 5 – fluorouracil</b>			
1 <sup>st</sup> Month	16%	--	84%
2 <sup>nd</sup> Month	16%	--	84%
Last Visit	16%	--	84%
<b>Without 5 – fluorouracil</b>			
1 <sup>st</sup> Month	28%	--	72%
2 <sup>nd</sup> Month	28%	--	72%
Last Month	28%	--	72%

The above table, in trabeculectomy with 5 – fluorouracil visual improvement occurred in 16% cases while visual acuity was stable in 84% cases, 1 patient of ACG improved from FC 3 mt to 6/36 and another patient of ACG improved from 6/60 to 6/18.

In trab. without 5 – fluorouracil visual acuity improved in 28% cases and visual acuity was stable in 72% of cases. 1 patient of ACG improved from FC 4 mt. to 6/60 while in other 6 cases improvement of visual acuity of 1 Snellen's line was observed.

**Table 6: Complications**

Complication	Trab. with 5 – fluorouracil (%)	Trab. without 5 – fluorouracil (%)
Shallow anterior chamber	06 (24)	--
HypHEMA	03 (12)	01 (4)
Corneal epithelial defect	--	--
Corneal ulceration	--	--
Severe hypotony	--	--
Endophthalmitis	--	--
Bleb leak	--	--
Cystic bleb	02 (8)	01 (4)

Most common complication observed was shallow anterior chamber in 24% with intraoperative use of 5 – fluorouracil which is due to overfiltration in the early post – operative period.

While minimal hypHEMA was observed in 3 cases (12%) with 5 – fluorouracil and 1 case (4%) without 5 – fluorouracil use, was cleared in two cases with conservative treatment and was persistent throughout post – operative period in one case of absolute glaucoma. Cystic bleb was observed in 2 patients (8%) with use of 5 – fluorouracil and in 1 patient (4%) without use of 5 – fluorouracil.

## Discussion

### Age Distribution

Most of the patients were from the fifth, sixth and seventh decade. Highest number of patients 17 i.e. (34%) were in the age group of 51-60 years. Mean age of the patients in the trabeculectomy with 5 – fluorouracil group was 55.28 + 10.20 years and 57.32 + 8.5 in the trabeculectomy without 5 – fluorouracil group.

Duke Elder reported that open angle glaucoma is more common in 6<sup>th</sup> & 7<sup>th</sup> decade.<sup>1</sup> According to Becker Shaffer's incidence of POAG increases after 40 years of age and most common in 5<sup>th</sup> & 6<sup>th</sup> decade.<sup>6</sup>

### Visual Acuity after Surgery

In this study with intraoperative use of 5 – fluorouracil, 16% had improvement in visual acuity of 1 or 2 Snellen's lines. Two patients of angle closure glaucoma had improvement in the visual acuity of 2 and 3 Snellen's lines respectively, while two patients of chronic simple glaucoma had improvement in visual acuity of one Snellen's line. 21 patients (84%) had stable visual acuity postoperatively.

In trabeculectomy without intraoperative use of 5 – fluorouracil (40%) had visual acuity in the range of 6/18 to 6/24, 7 patient (28%) had improvement in visual acuity of 1 or 2 Snellen's lines and was stable in 18 patients (72%) post operatively. Out of these 7 patients 6 were of angle closure glaucoma while one patient of chronic simple glaucoma showed improvement in visual acuity by 1 Snellen's line.

Our results are comparable to Lumina Lanigan et al. in their study visual improvement occurred in 12% patients, deterioration of visual acuity was seen in 21% cases and visual acuity was stable in 68% cases with intraoperative use of 5 – fluorouracil.<sup>7</sup>

Our results do not correlate to Mielke C who observed loss of visual acuity of more than two Snellen's line in 6 eyes (7.9%) in the 5 – fluorouracil group and in 4 eyes (5.17%) in the control group while in our study none of the patient had loss of visual acuity.<sup>8</sup>

Kuldev Singh noted improvement in visual acuity of more than 2 Snellen's lines in 3 patients (8.1%) and worsening of visual acuity by 2 Snellen's lines in 7 patients (18.9%) while visual acuity was stable in 27 patients (73%) with intraoperative use of 5 – fluorouracil.<sup>9</sup>

W.L. Membrey reported loss of 2 Snellen's lines of visual acuity in 15–20% cases with intraoperative use of 5 – fluorouracil due to progression of lens opacities and hypotonous maculopathy.<sup>10</sup> The reduced visual acuity was largely due to complications arising from extracapsular cataract extraction. Studies have shown that visual acuity may reduce after trabeculectomy.<sup>11</sup>

### Ophthalmoscopic Examination

In trab with 5 – fluorouracil group, out of 25 patients fundus was visualized in 17 patients. In remaining 8 patients ophthalmoscopic examination was not possible due to cataract changes. In 5 patients who had normal optic disc preoperatively, there was no evidence of optic disc cupping. One patient (6%) with 0.4 cupping with nasal shifting of vessels preoperatively had same findings throughout post – operative period, while 10 patients (58%) with cupping of 0.7 – 0.9 with nasal shifting of vessels had no progression of fundus findings and 1 patient (6%) had remained same with glaucomatous optic atrophy.

In trab without 5 – fluorouracil group, none of the patients out of 9 cases with normal fundus preoperatively had evidence of glaucomatous cupping post – operatively till last follow – up. 1 patient with 0.4 cupping with healthy patients (48%) with 0.7- 0.9 cupping with nasal shifting of vessels and 3 patients (12%) of glaucomatous optic atrophy had no progression of cupping.

### Intraocular Tension

**At 1 month:** Around 96% in the 5 – fluorouracil group had intraocular tension of less than 15 mmHg and 1 patient (4%) had intraocular tension more than 26 mmHg in the 5 – fluorouracil group.

In the control group without intraoperative use of 5 – fluorouracil, 20 patients (80%) had intraocular tension less than 15 mmHg while 4 patients (16%) had intraocular tension between 16-20 mmHg and 1 patient (4%) had intraocular tension more than 26 mmHg.

**2<sup>nd</sup> Month:** At the end of 2<sup>nd</sup> month postoperatively 24 patients (96%) in the 5 – fluorouracil group and 19 patients (72%) in the control group had intraocular tension of less than 15 mmHg. 5 patient (20%) of the trab without 5 – fluorouracil group had intraocular tension between 16-20 mmHg while 1 patient 4% from each the group had intraocular tension more than 26 mmHg.

**Last visit (6 month):** At 6 months, 23 patients (92%) in the trab with 5 – fluorouracil group and 16 patients (64%) in the trab without 5 – fluorouracil group had intraocular tension less than 15 mmHg. 1 patient (4%) in the 5 – fluorouracil group had intraocular tension between 16-20 mmHg compared to 8 patients (32%) in the trab without 5 – fluorouracil group. 1 patient (4%) from each group had intraocular tension more than 26 mmHg.

There was significant difference in intraocular tension control between two groups. i.e. in trab with 5 – fluorouracil group, there was constant maintenance of low intraocular tension throughout the post-operative period while in case of trab without 5 – fluorouracil group some patient failed to maintain the intraocular tension below 15 mmHg as a result difference in two groups intraocular tension was increased.

Mielke C, Dawda K, observed that the probability of maintaining intraocular tension of 14 mmHg or less was significantly greater in the 5 – fluorouracil group (64%) than in the control group (39%).<sup>8</sup>

Spiegel D, Sachs H, with intraoperative use of 5 – fluorouracil concluded that the low intraocular tension in the 5 – fluorouracil group is not just due to antiproliferative effect but might be of toxic origin of 5 – fluorouracil. They also stated that the intraoperative use of 5 – fluorouracil is to be a safe procedure with pronounced capacity to lower the intraocular tension in direct post – operative period.<sup>12</sup>

Our results do not correlate to Wong JS, YIP L, who observed that the probability of trabeculectomy survival (less than 22 mmHg) at 12 and 36 months was 54.3% and 36.4% in the control group and 75.8% and 65.8% in the 5 – fluorouracil group. Because, our trabeculectomy survival was 92% and 64% in the trab with 5 – fluorouracil group and control group at 6 months respectively.<sup>13</sup>

### Complications

Post-operative complications occurred in this study were, shallow anterior chamber and hyphema and it was observed in 6 cases (24%) with intraoperative use of 5 – fluorouracil and not seen in any case without intraoperative use of 5 – fluorouracil. It was seen in immediate post – operative period.

Our results are correlated to P.A. Lamba et al who observed shallow anterior chamber in 3 cases (27.3%) with intraoperative use of 5 – fluorouracil and 2 cases (16.8%) without use of 5 – fluorouracil.<sup>14</sup>

Our findings are not correlated with Binita Shelat who observed shallow anterior chamber in 2 cases (15.38%) with intraoperative use of 5 – fluorouracil while in our study shallow anterior chamber was observed in 6 cases (24%) with use of 5-fluorouracil.<sup>15</sup>

Lanigan have noted severe hypotony in 1 case with intraoperative use of 5 – fluorouracil while severe hypotony was not seen in any case in our study.<sup>7</sup>

In our study, Hyphema rarely reached more than one fourth of anterior chamber and usually absorbed post – operatively with conservative treatment with back rest and T.Acetazolamide 250 mg bid.

Our results are not correlated to Lamba et al who reported hyphema in 3 cases with intraoperative use of 5 – fluorouracil while in our study hyphema was present in 12% cases with use of 5 – fluorouracil and 4% cases without 5 – fluorouracil.<sup>13</sup>

Lanigan have reported the complications with intraoperative use of 5 – fluorouracil as punctuate corneal staining (7%), epithelial loss (35%), Chronic Hypotony (3.5% and cataract progression 3.5%.<sup>7</sup>

W.L. Membrey reported the complications with intraoperative use of 5 – fluorouracil were hyphema (16.7%), shallow anterior chamber (11.1%), early hypotny (25%), early leaking bleb (19.4%), choroidal effusion (19.4%) and hypotonous maculopathy in (2.8%) cases with intraoperative use of 5 – fluorouracil.<sup>10</sup>

We have not observed any corneal complications probably because of used the appropriate size of sponge and avoiding the touch of sponge to cornea. Also we did meticulous irrigation of trabeculectomy site with 20 cc Ringer lactate solution after 5 – fluorouracil application.

## Conclusion

To conclude, intraoperative use of 5 – fluorouracil in trabeculectomy is useful an alternative to maintain the intraocular tension in lower teens over prolonged period of time by modifying the conjunctival bleb morphology, without causing any serious corneal complications.

**Conflict of Interest:** None.

## References

1. Duke Elder. Volume of lens, vitreous and glaucoma 1976;379–388,528–538.
2. Cairns J.E. Trabeculectomy report of a new method. Symposium on glaucoma St. Louis C V Mosby Company. 1975:301-310.
3. Watson. P. G. Surgery of the Glaucomas. *Br J Ophthalmol* 1972;56:299.
4. Heuer DK, Parrish RK 2d, Gressel MG, Hodapp E, Palmberg PF, Anderson DR. 5-fluorouracil and glaucoma filtering surgery. II. A pilot study. *Ophthalmol* 1984;91(4):384–394.
5. Doyle J, Sherwood M, Khaw P. Intraoperative 5-Fluorouracil for filtration surgery in the rabbit. *Invest Ophthalmol Vis Sci* 1993;34(12):3313–3319.
6. Becker Shaffer's Diagnosis and therapy of glaucomas. Primary Open Angle Glaucoma. 7th Edition 2 1999;286–317.
7. Lumina lanigan, Jorg Sturmer, Karin A Baez, Roger A Hitchings, Peng J Khaw. Single intraoperative application of 5 – Fluorouracil during filtration surgery – early results. *Br J Ophthal* 1994;78:33–37.
8. Mielke C, Dawda NK, Anand N. Intraoperative use of 5 – Fluorouracil application during primary trabeculectomy in Nigeria, a comparative study. *Eye* 2003;17(7):829 –834.
9. Kuldev Singh, Peter R, Egbert, Sally Byrd. Trabeculectomy with intraoperative 5 – Fluorouracil Vs Mitomycin – C. *Am J Ophthalmol* 1997;123:48–53.
10. W.L. Membrey, D P Poinosawmy C. Bunce, R A Hitchings. Glaucoma surgery with and without adjunctive antiproliferatives in normal tension glaucoma. Intraocular pressure control and complication. *Br J Ophthalmol* 2000;84:586-590.
11. Sihota R, Gupta V, Agar Wal HC. Long-term evaluation of trabeculectomy in primary open angle glaucoma and chronic primary angle closure glaucoma in an Asian population. *Clin Exp Ophthalmol* 2004;32(1):23-28.
12. Spiegel D, Sachs H, Yanes G. Single dose intraoperative administration of 5 – Fu in trabeculectomy. Long term results of Pilot study. *Ophthalmol* 1996;93(5):561–566.
13. Wong JS, Yip Z, Tan C, Chew P. Trabeculectomy Survival with and without intraoperative 5 – Fluorouracil application in an Asian Population. *Aust N Z J Ophthalmol* 1998;26(4):283-288.
14. Lamba P A, Pandey P K, Raina U K, Krishna V. Short term results of initial trabeculectomy with intraoperative or Post – operative 5 – Fluorouracil for primary glaucomas. *Indian J Ophthalmol* 1996;44(3):157–160.
15. Shelat B, Rao B S, Vijaya L, Revathi B, Garg D. Results of intraoperative 5 – Fluorouracil in patients undergoing trabeculectomy – Pilot trial. *Indian J Ophthalmol* 1996;44 (2):91–94.

**How to cite this article:** Patil MD, Sankaram JH. Study on long term effects and complications of 5-fluorouracil in trabeculectomy. *Indian J Clin Exp Ophthalmol* 2019;5(1):95-101.