

An unusual case of scleral abscesses preceded by uveitis

Tanvi Poy Raiturcar^{1,*}, Ugam Usgaonkar², Marushka Aguiar³

¹Senior Resident, ²Professor and Head, ³Junior Resident, Dept. of Ophthalmology, Goa Medical College, Goa, India

***Corresponding Author: Tanvi Poy Raiturcar**

Email: tanvi1491@gmail.com

Abstract

Ocular tuberculosis is a very rare clinical presentation. The limited specimen size available for investigation makes it difficult to reach an accurate diagnosis. Here is a case of uveitis which did not show any improvement with topical steroids and progressively worsened to develop scleral abscesses. The only positive history was contact with a patient of pulmonary tuberculosis and the only positive investigation was a strongly positive Mantoux test. Based on these the patient was started on anti-tuberculosis therapy and showed a dramatic improvement.

This is only the second such case reported in the literature.

Keywords: Ocular tuberculosis, Scleral abscesses, Uveitis.

Introduction

Ocular tuberculosis is a rare presentation of extra pulmonary tuberculosis, and can involve the uvea, orbit, lacrimal gland, lids, conjunctiva, sclera, optic nerve and retina. The prevalence of ocular tuberculosis in endemic areas is around 10%, and that of Tuberculous uveitis is 9.86%.¹ Infectious scleritis constitutes 5-10% of all scleritis, and most common causative organism is *Pseudomonas aeruginosa*.^{2,3} Infectious scleritis caused by tuberculosis is very rare. Here is an unusual case of tuberculous scleritis, which was preceded by uveitis. Only one such case has been reported earlier in the literature; where the patient presented with tuberculous uveitis and later developed scleral abscesses, showing improvement with anti-tuberculosis treatment.

Case History

A fifty seven year old male patient of Indian origin presented to the Ophthalmology out-patient Department with history of sudden onset of decreased vision in the left eye since seven days. There was history of severe throbbing type of pain in the eye which was referred to the left side of the forehead. He also gave history of redness in the eye and complained of intolerance to ambient light.

All the above symptoms had been progressively worsening over the past two days.

On examination, there was episcleral and scleral congestion with dilated episcleral and scleral vessels, severe anterior chamber reaction (four + according to the standardisation of uveitis nomenclature), and pigments in the anterior chamber (Fig. 1). Fundus examination using indirect ophthalmoscopy revealed vitritis. Visual acuity was reduced to 6/36 according to the Snellen's distance vision chart. Intraocular pressure was normal (10 mm of Hg) by Goldmann applanation tonometry.

Patient was started on topical prednisolone eye drops (1%) four times a day and topical moxifloxacin eye drops (0.5%) four times a day. Oral antibiotics (levofloxacin 500 mg) were started twice a day.

Over the next five days the condition of the patient began to worsen. He now developed two scleral abscesses (Fig. 2, 3). The intraocular pressure also began to decrease (6mm of Hg by Goldmann applanation tonometry). Indirect ophthalmoscopy at this stage revealed exudative retinal detachment and vitritis. The findings were confirmed by B-Scan ultrasonography.

Meanwhile blood investigations were done, which included a complete hemogram, RA factor, Anti-nuclear antibody testing, C-Reactive proteins, anti- Streptolysin O titres, ELISA for HIV, VDRL, HbSag, and sputum for Acid fast bacilli and CB-NAAT testing. All these were negative and inconclusive.

Chest X-ray was normal.

Mantoux test was done using purified protein derivative, and was checked after forty eight hours, to reveal a strongly positive reaction with induration of 12mm. This was the only positive investigation.

Swabs collected from the abscesses, abscesses were scraped using a No 15 surgical blade and conjunctival biopsy was done. All the material thus collected were sent for histopathological studies, Gram staining, and screening for Acid fast bacilli and CB-NAAT testing; however there were no positive results.

Upon repeated questioning the patient revealed history of pulmonary Tuberculosis in his brother.

Since there were no other positive findings other than a positive Mantoux test, the patient was started on empirical anti-tuberculosis treatment (ATT), which in accordance with the Directly observed treatment short course included; isoniazid, rifampicin, pyrazinamide, and ethambutol.

Within seven days of therapy the patient showed signs of improvement. The vision improved to 6/12 according to Snellen's distance vision chart, episcleral and scleral congestion reduced, the scleral abscesses began to reduce in size (Fig. 4), there was no anterior chamber reaction (Fig. 5), the exudative retinal detachment began to settle and there was a reduction in the vitritis.

The patient followed up again after another week of therapy (after 14 days of ATT), it was noted that the abscesses had healed with scleral thinning. (Fig. 6)

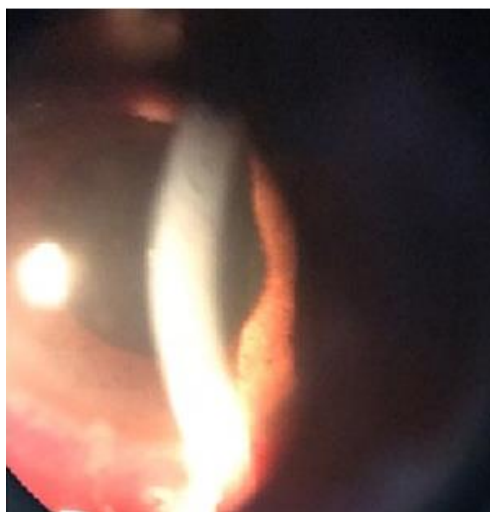

Fig. 1

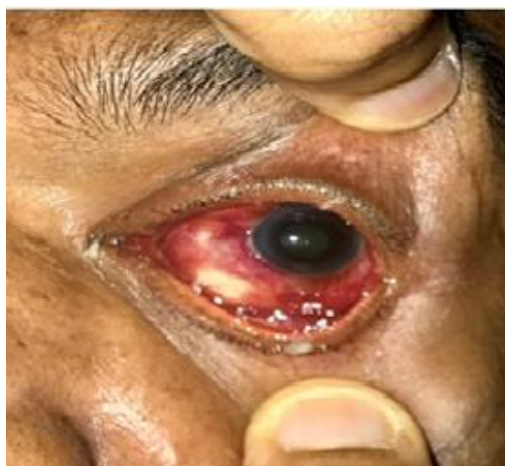

Fig. 2

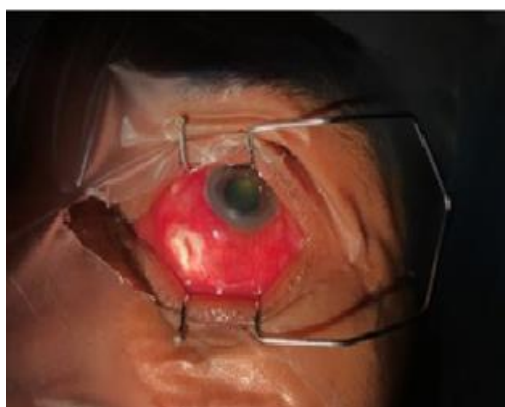

Fig. 3

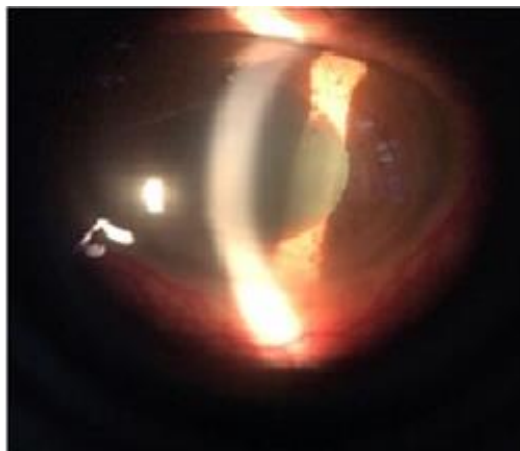


Fig. 4

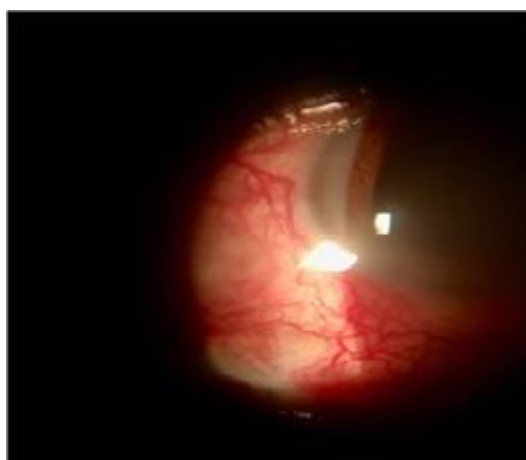


Fig. 5

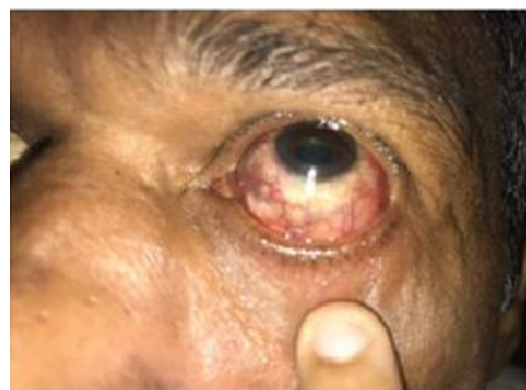

Fig. 6

Discussion

Tuberculosis is caused by mycobacterium tuberculosis, and happens to be a very important disease as far as India is concerned. It most commonly involves the lungs in the form of pulmonary tuberculosis. Extra-pulmonary tuberculosis affects 15-20% of immunocompetent and 50% of immunocompromised individuals. Extrapulmonary tuberculosis involves the lymphatic system, bone, gastrointestinal system, central nervous system, eyes, cardiovascular system, genito-urinary system and skin.^{7,8}

Ocular tuberculosis is a rare presentation, and occurs due to hematogenous spread. Primary ocular tuberculosis is even more rare, and the sites of involvement include the orbit, lacrimal gland, lids, conjunctiva, sclera, uvea, retina and the optic nerve.⁹ The prevalence of ocular tuberculosis is 10% in endemic areas, and that of Tuberculous uveitis is 9.8%.¹ Infectious scleritis accounts for 5-10% of all cases of scleritis. The most common organism causing scleritis is *Pseudomonas aeruginosa*. Other organisms include *Staphylococcus* and *Herpes Zoster* which cause necrotizing scleritis.^{2,3} Rare organisms implicated in the causation of infectious scleritis include, *Mycobacterium tuberculosis*, atypical mycobacteria, *Nocardia*, and *Acanthamoeba*.¹⁰ The case that we are reporting is a very unusual case where the patient presented with uveitis which was unresponsive to treatment with steroids, and the patient rapidly worsened and developed scleral abscesses. The only positive finding noted was a strongly positive Mantoux test and history of contact with a patient of pulmonary tuberculosis. Acid fast bacilli could not be identified from any other sample such as sputum, pus swabs, scrapings or conjunctival biopsy specimen. Chest X-Ray was normal and CB-NAAT testing was negative. However the patient was started on empirical anti-tuberculosis therapy and showed a dramatic improvement in signs and symptoms. There is only one such case reported so far in the literature by Chansangpetch S and Manassakorn A¹¹ where the patient presented with tuberculous uveitis and later developed nodular scleritis, which improved upon starting anti tuberculosis therapy.

10. Ebrahimi KB, Green WR. *Acanthamoeba* sclerokeratitis. *Graefes Arch Clin Exp Ophthalmol* 2009;247:283-286.

How to cite this article: Raiturcar TP, Usgaonkar U, Aguiar M. An unusual case of scleral abscesses preceded by uveitis. *Indian J Clin Exp Ophthalmol* 2019;5(1):131-133.

Acknowledgement

We would like to thank our junior residents who have helped us in collecting important clinical information relevant to this case.

Key Messages: Here is a very unusual case of uveitis that progressed to develop scleral abscesses, which improved upon starting anti-tuberculosis treatment.

Conflict of Interest: None.

References

1. Singh R, Gupta V, Gupta A. Pattern of uveitis in a referral eye clinic in North India. *Indian J Ophthalmol* 2004;52:121-125.
2. Jain V, Garg P, Sharma S. Microbial scleritis: experience from a developing country. *Eye* 2009;3:255-261.
3. Huang FC, Huang SP. Management of infectious scleritis after pterygium excision. *Cornea* 2000;19:34-39.
4. Yeh S, Sen HN, Colyer M. Update on ocular tuberculosis. *Curr Opin Ophthalmol* 2012;23:551-556.
5. Kesen MR, Edward DP, Rao NA, Sugar J. Atypical infectious nodular scleritis. *Arch Ophthalmol* 2009;127:1079-1080.
6. Damodaran K, George AE. Tubercular sclerouveitis masquerading as an ocular tumour: a case report. *Ocul Immunol Inflamm* 2012;20:368-371.
7. Sharma SK, Mohan A. Extrapulmonary tuberculosis. *Indian J Med Res* 2004;120:316-353.
8. Golden MP, Vikram HR. Extrapulmonary tuberculosis: an overview. *Am Fam Physician* 2005;72:1761-1718.
9. Tabbara KF. Tuberculosis. *Curr Opin Ophthalmol* 2007;18:493-501.