

Persistent red eye? Look out for conjunctival ulcers; eye opener for systemic differential diagnosis

Sandhya Ramachandra^{1,*}, Harshitha K.M², Darshan S.M³

¹Professor, ²Junior Resident, ³Senior Resident, Dept. of Ophthalmology, Sri Devaraj Urs Medical College, Kolar, Karnataka, India

***Corresponding Author: Sandhya Ramachandra**

Email: sanchina@rediffmail.com

Acute red eye is one of the commonest clinical conditions encountered in routine Ophthalmic out patient practice, invariably treated with topical antibiotics by general ophthalmologists. However, unresponsive or persistent acute red eye may be challenging to treat: it may be a manifestation of a systemic illness.

A 32 year old male presented to us with history of persistent redness after completion of a course of topical antibiotic eye drops (Gatifloxacin eye drops 6 times a day for 5 days) prescribed in the out patient department of a tertiary care Medical college hospital. Upon re-enquiry of the history, it was typical of conjunctivitis. There was no other significant ocular history or known drug allergy. Cornea was normal, no pre auricular lymphadenopathy was seen. Multiple conjunctival ulcers in the bulbar, palpebral and inter marginal conjunctiva of both eyes were found. They were 2 to 3 mm in diameter with whitish necrotic floor and surrounding intense congestion. Rest of the anterior segment, Visual acuity & fundus was normal. The patient was again quizzed in detail, when he revealed that he was actually attending the ENT out patient. His records revealed that he was under evaluation for laryngeal stricture and was scheduled for biopsy of a sub glottic nodule. The routine screening tests were normal except for elevated ESR. The patient was given lubricating eye drops, topical NSAIDS drops 4 times a day and topical gatifloxacin drops was continued 2 times a day. The patient was given a course of oral ciprofloxacin and NSAIDS, called for review after 1 week. Patient had an uneventful biopsy of the lesion by ENT surgeon and the histopathology report suggested an

acute inflammatory process. The conjunctival lesions had healed totally without any sequelae. Again the patient was asked regarding any other ulcerative lesions anywhere else by a male colleague when he revealed, for the first time, the history of genital ulcers in the past. The patient was counselled & advised further tests for Behcet's but was unfortunately lost to follow up.

Behcet's syndrome is a multi-system, relapsing illness with muco cutaneous, gastrointestinal, genitourinary, ocular, neurological, vascular, articular inflammation. It is diagnosed by ISG criteria (1 required criteria & 2 Minor criteria). Ocular inflammation like Uveitis or vasculitis are included under minor criteria and the ophthalmologists consider Behcet's as the differential diagnosis in these cases.

Recurrent aphthous ulcers are described over entire GIT¹ and on the larynx, pharynx² Conjunctival ulcers may be seen on the bulbar conjunctiva, limbus,³ or palpebral conjunctiva as seen in this patient.

Said to be associated with HLA B 5,⁴ the disease may have wide regional variation in manifestation. Aphthous ulcers are seen in almost all the patients (98%) while ocular manifestations may be seen in 79%⁵ to 36.8%.³ The occurrence of conjunctival ulcers is considered as an uncommon manifestation⁶ by some authors while it was found to be 26.3% by an Indian study.³

The purpose of this communication is to alert young ophthalmologists that Conjunctival lesions in acute red eye require thorough evaluation beyond Ophthalmology, requiring detailed history and cross referral.

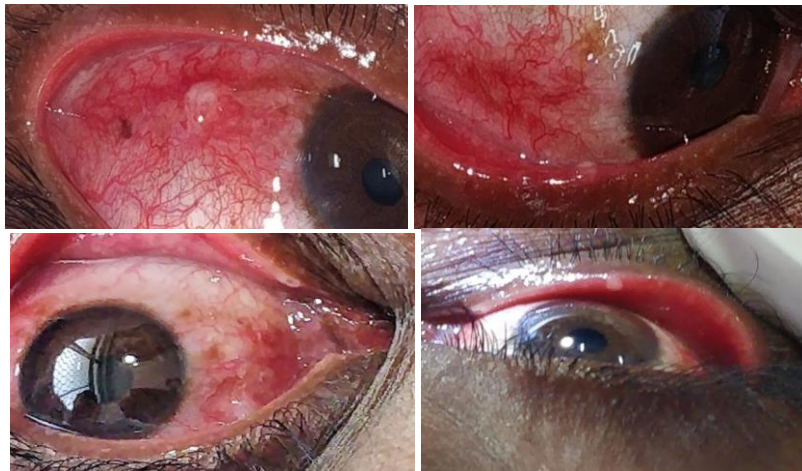


Fig. 1

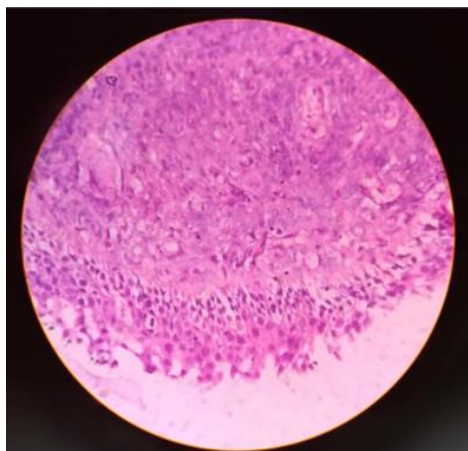


Fig. 2

Conflict of Interest: None.

Reference

1. Griffin JW, Harrison HB, Tedescor FJ, Mills LR. Behcet's Disease with multiple sites of gastro intestinal involvement. *South Med J* 1982;75:1405.
2. Lehner T. Progress Report: Oral Ulcerations & Behcet's syndrome. *Gut* 1977;18:491-511.

3. Jolly Rohatgi, Archana Singal. Ocular Manifestations of Behcet's Disease in Indian Patients. *Indian J Ophthalmol* 2003;51:309-313.
4. Yazici H, Akokan G, Yalain B, Mufatuoglu A. The high prevalence of HLA B5 in Behcet's disease. *Clin Exp Immunol* 1977;30:259-261.
5. Oshima Y, Shimuzu T, Yokohari R, Matsumoto T, Kano K, Kogami T. Clinical studies in Behcet's syndrome. *Ann Rheum Dis* 1963;22:36-45.
6. Toshihiko Matsuo, Masako Itami, Hideki Nakagawa, Mikio Nagayama. The incidence & pathology of conjunctival ulceration in Behcet's syndrome. *Br J Ophthalmol* 2002;86:140-143.

How to cite this article: Ramachandra S, Harshitha KM, Darshan SM. Persistant red eye? Look out for conjunctival ulcers; eye opener for systemic differential diagnosis. *Indian J Clin Exp Ophthalmol* 2019;5(1):138-139.