

***Nocardia brasiliensis* gluteal abscess in an immunocompetent young male: A case report and literature review of Nocardiosis**

M. Jane Esther^{1,*}, P. K. Rath², R. Arivazhagan³

¹Consultant, ²Pathologist, ³Physician, ¹Dept. of Microbiology, ²Dept. of Pathology, ³Dept. of General Medicine, ^{1,2}Diagnostic Centre, Trichy, Tamil Nadu, ³Manaparai, Trichy, Tamil Nadu, India

***Corresponding Author: M. Jane Esther**

Email: janesweety16@gmail.com

Abstract

Nocardiae are aerobic gram positive filamentous bacteria that are acid fast when stained by modified acid fast staining. They are called "Aerobic actinomycetes" because of their resemblance to actinomycetes in gram stain. They usually cause infections in immunocompromised individuals but can affect the immunocompetent as well. We have described here the report of an immunocompetent young male who presented with nocardial gluteal abscess. Nocardia must be considered in the differential diagnosis of any systemic illness and must be ruled out prior to making any other diagnosis. Correct suspicion of nocardiosis by the treating physician and the clinical microbiologist and early treatment of nocardiosis can be life saving to a great extent. Gram staining and modified acid fast staining performed together can definitely help in arriving at the exact diagnosis at the earliest.

Keywords: Nocardiosis, Nocardia, Nocardial abscess, Nocardia in immunocompetent, Nocardia brasiliensis infection.

Introduction

Nocardiosis is a rare opportunistic bacterial infection caused by Nocardia species. It is a gram positive and modified acid fast bacillus. Nocardiosis can infect any part of the body though the most common site of infection is the lungs. The incidence of nocardiosis is increasing due to improved survival of patients with malignancies, on immunosuppressive drugs, invasive surgical procedures and other immunocompromising states.¹ About a third of nocardia infections occur in immunocompetent individuals. However the condition is often misdiagnosed due to non specific clinical manifestations and lack of suspicion of the disease. Isolation of nocardia from appropriate clinical specimens can help in arriving at the accurate diagnosis.¹ Simple methods like gram staining and modified acid fast staining can help to a greater extent in arriving at an early diagnosis.² We have described here the case report of superficial nocardial infection in an immunocompetent young male to bring into light the importance of suspecting and diagnosing nocardiosis even in immunocompetent and healthy individuals. Nocardiosis has the potential to spread to all organs hematogenously and it can be fatal if not treated at an early stage. So, early suspicion, diagnosis and treatment of nocardiosis can save lives of patients.¹

Case Report

A 26 year old farmer came to the OPD with complaints of pain and swelling in the right side of his lower back since 2 weeks. He also gave a history of fever since a week. History of difficulty in adopting sitting posture due to pain was present. He was not a diabetic or hypertensive. History of occasional smoking and alcohol consumption were present. He had no history of similar illnesses in the past. He could not recollect any incident of having received thorn pricks in the area of swelling, but he said that he carries wooden logs over his back. On examination, the patient was moderately built. His blood pressure was 120/80mm Hg,

pulse rate was 80/ min. On auscultation of the chest, S1 and S2 were heard normally and normal vesicular breath sounds were heard. His central nervous system and abdomen were clinically normal. On local examination, a swelling of about 15*12 cm was found in his right gluteal region. The swelling was tender, fluctuant, warm. A presumptive diagnosis of right sided gluteal abscess was made. Incision and drainage of the abscess was carried out and frank pus was sent for culture and sensitivity testing to the microbiology laboratory. Gram stain smear of the pus sample showed many pus cells, long, filamentous and branched gram positive bacilli. Modified acid fast staining was carried out with 1% sulfuric acid to rule out *Nocardia*. Modified AFB staining showed many long, branched acid fast bacilli as shown in figure 1. A presumptive diagnosis of nocardiosis was made. Bacteriological culture of the organism was carried out in blood agar which showed dry, wrinkled colonies after aerobic incubation at 25°C and 37°C for 4 days. The blood agar plate incubated anaerobically showed no growth even after incubation for 2 weeks. Gram staining performed from the colonies on blood agar showed weakly gram positive filamentous rods. Modified AFB staining showed branched and filamentous acid fast bacilli. The bacterium was found to hydrolyse casein, tyrosine, xanthine and urea. Based on the above tests, the organism was identified as *Nocardia brasiliensis*. Hence the diagnosis of Nocardial gluteal abscess was made. The patient was treated with one cotrimoxazole double strength tablet 12 hourly for 2 weeks, following which the wound healed completely. One double strength tablet is continued everyday for 6 months with the patient being followed up regularly. The patient is doing well at present.

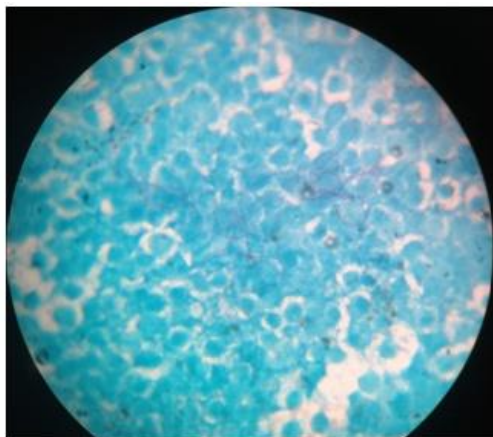


Fig. 1: Modified acid fast staining from pus sample of the patient showing long, branched, filamentous and fast bacilli



Fig. 2: White, dry and wrinkled colonies of Nocardia on blood agar

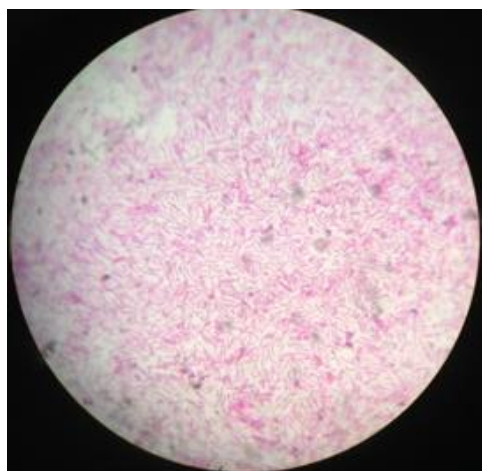


Fig. 3: Gram staining performed from Nocardia colony showing long, filamentous gram positive bacilli

Discussion and Literature Review

Nocardia are aerobic bacteria that are mostly found as saprophytes in soil, organic matter and water. They are ubiquitous environmental bacteria that usually cause infection in immunocompromised hosts.² *Nocardia* is also called 'aerobic Actinomycetes' because of their morphological similarities to actinomycetes. *Nocardia* are aerobic gram positive bacteria that appear filamentous with hyphae like branching while observed microscopically.³ They have mycolic acid in their cell wall which makes them acid fast. They resist decolourization when stained with strong carbol fuchsin and decolourized with 1% sulfuric acid. (Modified acid fast/ Modified Ziehl-Neelsen stain).

Risk Factors for Nocardiosis

Nocardia is usually an opportunistic pathogen. Most of the infections occur in immunocompromised patients. However about one third of the infections occur in immunocompetent individuals.⁴ Isolation of *Nocardia* from any clinical sample, at any site should be considered significant and not just regarded as a contaminant or commensal. Immunocompromised patients like those with lymphoma, malignancies, solid organ or stem cell transplant recipients, patients with human immunodeficiency viral infection, patients on steroids or other immunosuppressive medications are at a higher risk of acquiring *Nocardia* infection.⁴ Lung transplant recipients are found to be at a higher risk of infection compared to other solid organ transplant recipients. Patients with allogeneic hematopoietic stem cell transplants are at a higher risk than those who receive autologous stem cell transplants.³ Concurrent infections like cytomegalovirus infection, presence of diabetes and alcoholism also contribute to acquisition of *Nocardia* infection.⁴ Patients with chronic obstructive pulmonary disease with other associated immunocompromised states are at a higher risk of acquiring pulmonary nocardiosis. Primary cutaneous and soft tissue nocardiosis can result from traumatic injury to skin. They can occur in immunocompetent individuals as in our patient.⁴

Clinical Presentation of Nocardiosis

Clinical classification of nocardiosis comprises isolated pulmonary, central nervous system, cutaneous and disseminated or systemic nocardiosis.⁵

Pulmonary nocardiosis is the commonest clinical presentation of *Nocardia* infection because inhalation is the primary route of exposure. Pulmonary nocardiosis most commonly presents as lung abscess with typical respiratory symptoms like cough, chest pain, blood tinged sputum, chills, weakness, lack of appetite and breathlessness.⁵ Chest X-ray findings are variable with nodular lesions / consolidation / cavitation. Some patients can present with pleural effusion. All these clinical and radiological features can mimic tuberculosis and fungal infections.⁶ So suspicion of nocardiosis and performance of relevant tests are necessary to diagnose the condition. The differential diagnoses of pulmonary nocardiosis are tuberculosis, lung

malignancy, actinomycosis, other bacterial lung infections and fungal infections like aspergillosis, mucormycosis, histoplasmosis, blastomycosis and cryptococcosis. In patients with cystic fibrosis and bronchiectasis, *Nocardia* can be a colonizer of the respiratory tract and so clinical correlation is necessary.⁴

Central nervous system nocardiosis can occur due to hematogenous spread of *Nocardia* from lungs to brain. It can present as brain abscess with symptoms suggestive of intracranial space occupying lesion. Nocardial CNS infection can mimic many other diseases like tuberculosis, fungal or bacterial brain abscess, malignancy, toxoplasmosis and vascular infarct and must be differentiated correctly.⁴

Primary cutaneous or soft tissue nocardiosis usually results from traumatic injury where contamination of the wound with soil occurs. It can present as localized abscess or cellulitis, mycetoma or sporotrichoid lesion.⁴ Abscesses and cellulitis can mimic infections caused by *Staphylococcus*, *Streptococcus* and *Erysipelothrix*. Lymphocutaneous nocardiosis is also called sporotrichoid nocardiosis as it presents similar to sporotrichosis with involvement of linear chains of lymph nodes.⁴ *Nocardia brasiliensis* is the most common species associated with cutaneous disease though *N. asteroides* and *N. otitidiscavarum* can also be occasionally involved. Sporotrichoid lesions can mimic infections caused by *Sporothrix schenckii* or *Mycobacterium marinum*.⁴ *Nocardia* mycetoma can resemble actinomycotic or fungal mycetoma or botryomycosis (mycetoma like lesion caused by bacteria). Other differential diagnoses for cutaneous and subcutaneous nocardia infections are cutaneous leishmaniasis, cryptococcosis and other cutaneous atypical mycobacterial infections.⁴

Systemic or disseminated nocardiosis can occur due to hematogenous or contiguous spread of infection from lungs into pleura, pericardium, mediastinum and vena cava. *Nocardia* infection is characterized by abscess formation which is difficult to be distinguished clinically and radiologically from abscesses due to other bacteria.⁶

Nocardiosis can present with bacteremia less commonly. *Nocardia* has been found to be associated with central venous catheter infections. Polymicrobial bacterial infections with *Nocardia* and other gram negative bacilli have also been reported. *Nocardia* bacteremia can result in seeding of infection into eyes, liver, spleen, heart valves, adrenals, thyroid gland and other organs.⁴

Diagnosis of Nocardiosis

Establishing the diagnosis of *Nocardia* is often problematic due to the invasive procedures required for collection of samples and the slow growing nature of the organism. It is therefore important for the clinician to inform the laboratories when nocardiosis is suspected.⁵ Even if no clinical information on suspicion of nocardiosis is received, an astute clinical microbiologist examining gram stain of the sample must be able to pick up the filamentous gram positive bacteria, confirm it with modified acid fast stain and guide the treating doctor towards the

diagnosis of nocardiosis. Suspicion of the disease can help in early diagnosis and treatment of the patient.

Samples to be Collected

The recommended clinical sample to be collected for testing depends on the site of involvement pertaining to the symptoms. Sputum samples, bronchoalveolar lavage, pus from abscesses, cerebrospinal fluid, blood or tissue samples are commonly collected.⁴

Macroscopic and Microscopic Examination of Samples

The clinical samples must be examined macroscopically for the presence of granules. If there are granules, they must be crushed between the slides and examined microscopically after washing them with saline.⁷

It is a must to perform both gram staining and modified acid fast staining in clinical samples for making a presumptive diagnosis of *Nocardia*. Nocardiae are seen microscopically as beaded gram-positive, thin, branching, filamentous organisms. Actinomycetes also look alike in gram stain.⁷ Nocardiae are acid fast when stained with strong carbol fuchsin and decolourised with 1% sulfuric acid. So modified acid fast staining must be done to differentiate nocardiae from actinomycetes. The weak acid fastness and beaded appearance on microscopy differentiate *Nocardia* from mycobacteria which resist decolourization with 20% sulfuric acid.⁷

Histopathological examination of tissue sections stained with eosin and hematoxylin stain shows abscess with predominant neutrophilic infiltrates. A few foreign body giant cells, mononuclear cells and granuloma formation may be seen in mycetoma or other cutaneous infections. Rarely, the granules show peripheral intense eosinophilic material, representing Splendore-Hoeppli phenomenon. The filamentous nature of the bacterium is not appreciable in tissue sections stained with H & E. Stains like Fite-Faraco, Gomori methanamine silver and modified kinyoun's help to delineate the bacterial filaments.⁷

Culture of *Nocardia*

Nocardia grows readily on most of the non selective media used in laboratory. Growth occurs in 2-14 days. So the culture media has to be incubated in a sealed media for a minimum of two weeks before deciding that there is no growth.⁸ Fungal culture media also promotes growth of *Nocardiae*. Paraffin agar, agar containing antimicrobials, Thayer-Martin medium and charcoal-buffered yeast extract media can be used for selective isolation of *Nocardia*. The biochemical tests that can be used for species identification are hydrolysis of adenine, casein, tyrosine, xanthine, and hypoxanthine. Acetamide utilization and production of acid from L-rhamnose are other tests that can be used.⁸

Molecular methods like PCR and 16SrDNA sequencing help in correct identification of the species of *Nocardia*.⁷

CLSI has recommended broth microdilution method for antibiotic susceptibility testing of *Nocardia*.⁹

Other Supportive Investigations

Routine blood investigations show increased inflammatory markers, leukocytosis with neutrophilia. Radiological features are variable and depend on the site of infection.⁷

Treatment of Nocardiosis

Sulphonamides have been the antimicrobials of choice for treating nocardiosis since a long time. Trimethoprim-sulfamethoxazole is the most commonly used antibiotic for nocardiosis. Divided doses of 5 to 10 mg/kg/ day of the trimethoprim component or 25 to 50 mg/kg per day of the sulfamethoxazole component is the recommended dose.⁴ Cotrimoxazole is effective against most species of *Nocardia*. *N. otitidiscavarum* is commonly resistant to TMP-SMX.⁴

Other alternative antimicrobials with anti nocardial activity are amikacin, imipenem, meropenem, ceftriaxone, cefotaxime, minocycline, moxifloxacin, levofloxacin, amoxicillin-clavulanate, linezolid and tigecycline. Imipenem is more active than other carbapenems. Minocycline is the best anti nocardial tetracycline. Moxifloxacin has a considerable activity against *N. asteroides* complex. Linezolid has shown effective activity against all known pathogenic *Nocardia* species and has been used in the treatment of disseminated and CNS nocardiosis. Amoxycylav is moderately active against *N.asteroides*, *N.farcinica* and *N.brasiliensis*.³

Combination therapy is better than single drug treatment. The recommended combinations are imipenem and cefotaxime, amikacin and cotrimoxazole, imipenem and cotrimoxazole, amikacin and cefotaxime or amikacin and imipenem.⁴

For CNS nocardiosis, ceftriaxone and cotrimoxazole should be used. In severe nocardiosis, linezolid should be added to that combination. After the patient improves clinically, single drug therapy may suffice. The treatment has to be given for a longer duration to prevent relapse. Immunocompetent patients need 6 to 12 months of antimicrobial treatment.⁴ Immunocompromised patients or those with CNS disease need atleast 12 months of treatment with regular clinical monitoring. Cotrimoxazole can be used for prophylaxis against *Nocardia* infection in patients with advanced HIV infection.⁴ Patients with skin and soft tissue infections have been reported to have a complete cure following treatment compared to patients with respiratory nocardiosis or CNS nocardiosis where the cure rates are approximately 90% and 50% respectively. A higher mortality rate has been reported in patients on steroids and antineoplastic drugs.⁴

Conclusion

Nocardiosis is a relatively uncommon but a potentially life threatening infection which can affect any system of the body and present with non specific clinical manifestations. Though it more commonly affects the immunocompromised patients, it can affect the immunocompetent patients as well. Isolation of *Nocardia* from any clinical site should be

considered significant and correlated appropriately. Simple gram staining and acid fast staining by an astute clinical microbiologist can help in early accurate diagnosis. Nocardiosis must be considered in the differential diagnoses of any systemic infection and must be ruled out before making any other diagnosis. Early suspicion and diagnosis can prevent disease complications and mortality by institution of early treatment.

Conflict of Interest: None.

References

1. Yu S, Wang J, Fang Q, Zhang J, Yan F. Specific clinical manifestations of *Nocardia*: A case report and literature review. *Exp Ther Med* 2016;12(4):2021-2026.
2. Briciu VT, Flonta M, Lupse M, Damian L. Cutaneous nocardiosis manifesting as a frontal mass in a patient with giant cell arteritis. *Clujul Med* 2017;90(2):231-234.
3. Saubolle MA, Sussland D. Nocardiosis: review of clinical and laboratory experience. *J Clin Microbiol.* 2003;41(10):4497-501.
4. John W. Wilson, "Nocardiosis: Updates and Clinical Overview, 2012;87,4,403-407.
5. Alavi Darazam I, Shamaei M, Mobarhan M. Nocardiosis: risk factors, clinical characteristics and outcome. *Iran Red Crescent Med J* 2013;15(5):436-439.
6. Wadhwa T, Baveja U, Kumar N, Govil D, Sengupta S. Clinical manifestations of nocardiosis: Study of risk factors and outcomes in a tertiary care hospital. *J Lab Physicians* 2017;9(4):288-295.
7. Sagar R, Challa S. Pathology and Diagnosis of Nocardiosis. *JSM Foot Ankle* 2017;2(5):1040.
8. Barbara A. Brown-Elliott, June M. Brown, Patricia S. Conville, Richard J. Wallace Jr. Clinical and laboratory features of the *Nocardia* spp. based on current molecular taxonomy. *Clin Microbiol Rev.* 2006;19(2):259-282.
9. Lowman W, Aithma N. Antimicrobial susceptibility testing and profiling of *Nocardia* species and other aerobic actinomycetes from South Africa: comparative evaluation of broth microdilution versus the E test. *J Clin Microbiol* 2010;48(12):4534-4540.

How to cite this article: Esther MJ, Rath PK, R Arivazhagan. *Nocardia brasiliensis* gluteal abscess in an immunocompetent young male: A case report and literature review of Nocardiosis. *Indian J Microbiol Res* 2019;6(1):97-100.