

## Prevalence of ectopically erupted teeth in people from age 8 to 25 years- A prospective study

Jacob John<sup>1\*</sup>, Vinod Mathew Mulammoottil<sup>2</sup>, Geethu Jose<sup>3</sup>, Sheryl Kuriakose<sup>4</sup>, Anil Kurien<sup>5</sup>

<sup>1</sup>Reader, <sup>2</sup>Senior Lecturer, <sup>3</sup>Intern, <sup>4,5</sup>Lecturer, Dept. of Orthodontics, <sup>1-5</sup>Pushpagiri College of Dental Sciences, Thiruvalla, Kerala, India

**\*Corresponding Author: Jacob John**

Email: drjacob\_john@yahoo.com

### Abstract

**Aim of the study:** To determine the prevalence of ectopic teeth in randomly selected people in the age group from 8 to 25 years.

**Materials and Methods:** This prospective study was conducted 1) among patients visiting Pushpagiri College of Dental Sciences, Thiruvalla, and Kerala in the age group 8 to 25 years during a time period of 3 months 2) students of Christ Central School, Thiruvalla, and Kerala in the age group 8 to 18 years was determined through a screening camp. A total sample size of 460 people was selected randomly and was clinically examined for the presence of minimum of one ectopic tooth; from which this data was recorded.

**Results:** The result showed that 20.217% of patients examined had at least one ectopic tooth.

**Conclusion:** Disturbances of eruption may depend on systemic or local factors. The prevalence of ectopic eruption was moderately high. It is important to develop an early diagnosis in order to start treatment at the optimal time.

**Keywords:** Ectopic eruption, Eruption disturbance, Early diagnosis, Interception.

### Introduction

Malocclusion is a developmental condition and multifactorial. The specific causes of Malocclusion are a) Disturbances in Embryonic Development b) Growth Disturbances in the Fetal and Prenatal Period c) Progressive deformities in Childhood d) Disturbances arising in Adolescence or Early Adult life e) Disturbances of Dental Development.<sup>1</sup>

Eruption of teeth is a very complex process as it happens after the passing over of five stages. The stages are a) pre eruptive movements, intra-osseous stage, and mucosal penetration, pre-occlusal and post occlusal stages. Any disturbances in any of these stages lead to different forms of abnormality in occlusion.<sup>1</sup>

Eruption is defined as a developmental process responsible for moving a tooth from its crypt position through the alveolar process into the oral cavity to its final position of occlusion with its antagonist. It is a dynamic process that encompasses completion of root development, establishment of the periodontium, and maintenance of a functional occlusion.<sup>2</sup>

Ectopic eruption is one of the examples of disturbances of Dental Development; may happen due to the malposition of permanent tooth bud. Even though ectopic eruption happens in any tooth<sup>3</sup>, it seen most in the case of eruption of maxillary first molars.<sup>4</sup> Other than disturbances of dental development, the other reasons for Ectopic eruption are a) lack of space for normal tooth eruption, b) transposition of teeth,<sup>21,22</sup> c) Early loss of primary tooth. Ectopic eruption due to any of the above mentioned reasons will lead to space problems which in turn lead to deficient arch length. Early loss of one or both primary canines indicates the ectopic eruption of lateral incisors. This lead to a complex clinical situation like midline shift; and treatment for the correction of the same requires more complex Orthodontic treatment

methods. Ectopic eruption is manageable with early intervention treatment thereby prevent the loss of 6-8mm.<sup>5</sup>

The purpose of this prospective study was to determine the prevalence of ectopic teeth in people from age 8 to 25 years. Early diagnosis of eruption disturbances is important in order to start treatment at the optimal time and to minimize complications.

### Materials and Methods

In this prospective study, 77 patients selected randomly in Department of Oral Medicine at Pushpagiri College of Dental Sciences (PCDS), Thiruvalla; and 383 students randomly selected during the camp at Christ Central School (CCS), Thiruvalla. The selection of patients for the study were done in two places 1) at Pushpagiri College of Dental Sciences was three months starts from October 2014 to December and 2) also the students were selected during the Camp for a period of one month from 21<sup>st</sup> October 2014.

Total patients number of patients selected randomly for this prospective study was 460 among the age between eight to twenty five years. Criteria for the selection of ectopic eruption was the presence of at least one ectopically erupting tooth; and was evaluated clinically with the use of mouth mirrors and probes. To record the details of patient an evaluation chart was formed with columns for age, sex, presence or absence of ectopic eruption, FDI tooth number of ectopic eruption. This collected data of 460 samples was evaluated and percentage was calculated for the prevalence between 8 and 25 years.

## Results

**Table 1**

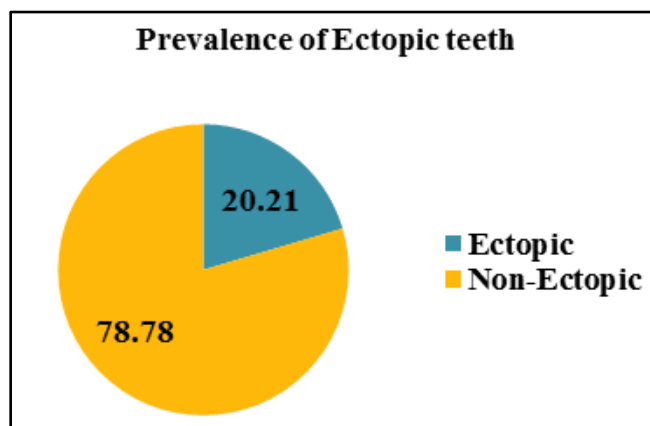
S. No	Name of the institution where samples collected	Number of samples taken	Number of Patients with one ectopic tooth
1	Pushpagiri College of Dental Sciences (PCDS)	77	15
2	Christ Central School	383	78

**Table 2**

1	Total number of patients examined	460
2	Total number of patients with at least one ectopic tooth	93

**Table 3**

Percentage of patients with atleast one ectopic tooth in the examined 460 patients	20.217%
--	---------



**Fig. 1**

## Discussion

Clinically an eruption is noticed as ectopic eruption as follows. 1) During the resorption of a primary tooth which is not supposed to resorb at that time. 2) Resorption of permanent tooth that is adjacent to the erupting tooth.

Resorption of primary canine happens during the eruption of the permanent lateral incisor<sup>6</sup>; may also indicate ectopic eruption other than due to the lack of space for incisors.<sup>7</sup> Even though ectopic eruption can happen in any tooth and also in both jaws; ectopic eruption happens commonly in the region of permanent maxillary first molars. Pulver suggested about the correlation between small distally positioned maxillary jaw and steeply angulated large permanent molars.<sup>8</sup> But Bjerklind K and Kurol J. suggested that there is no skeletal relationship relation for the maxillary first molar ectopic eruption.<sup>9</sup>

This prospective study of 460 patients showed that there was 20.21% patients had at least one ectopically erupted tooth. This study conducted with the help of clinical diagnostic methods. Usage of routine periapical or bitewing radiographs will give more clear idea in younger patients than clinical examination.<sup>7</sup> To reduce the multiple radiographs and for monitoring the entire eruption pattern, usage of Panoramic radiograph can be consider.

Similar to other studies, our study also showed that out of 20.21% prevalence the maximum number of ectopic eruption seen in the maxillary canines.<sup>10,11</sup>

The basic interceptive treatment of ectopically erupted permanent tooth is to move the same from the primary resorbed tooth and several treatment methods are also used. In case of Permanent first molars, one of the treatment options for the interception is the use of a 20 or 22 mil brass wire looped and contacted tightly between deciduous second molar and the permanent molar.<sup>12</sup>

## Conclusion

This prospective studied revealed that there was moderate prevalence of ectopic eruption seen in 460 patients. Maximum number of ectopically erupted tooth presented in the study was maxillary canines. To avoid the loss of normal arch length, early diagnosis, regular monitoring and timely interceptive orthodontic treatment procedures of developing ectopic eruption is required.

**Conflict of Interest:** None.

## References

- William R Proffit, Henry W Fields, David M Sarver. Contemporary Orthodontics: 5<sup>th</sup> Edition Elsevier, Page 114.
- Nolla CM. The development of the human dentition. *ASDC J Dent Child* 1960;27:254-66.
- Matteson SR, Kantor ML, Proffit WR. Extreme distal migration of the mandibular second bicuspid. *Angle Orthod* 1982;52:11-18.
- Bjerklind K, Kurol J, Valentin J. Ectopic eruption of maxillary first permanent molars and association with other tooth and developmental disturbances. *European J Orthod* 1992;14:369-375.
- Sim J M. *Minor Orthodontic tooth movement in children*. 2<sup>nd</sup> ed. Saint Louis: C V Mosby Co; 1977p 493.
- Cernochova P, Krupa P, Izakovicova-Holla LA. Root resorptions associated with ectopically erupting maxillary permanent canines: a computed tomography study. *Eur j Orthod* 2011;33: 483-491.
- Kanoknart Chintakanon, Patipat Boonipinon. Ectopic eruption of the first permanent molars: prevalence and etiological factors. *Angle Orthod* 1998; 68 (2):153-160.
- Pulver F. The etiology and prevalence of ectopic eruption of the maxillary first permanent molar. *J Dent Child* 35:138-146; 1968.
- Bjerklind K, Kurol J. Ectopic eruption of the maxillary first permanent molar: Etiologic factors. *Am J Orthod* 84:147-155, 1983.

10. Bishara SE. Clinical management of impacted maxillary canines. *Semin Orthod* 1998;4:87-98.
11. Ericson S, Kurol PL. Resorption of incisors after ectopic eruption of maxillary canines; A CT study. *Angle Orthod* 2000;70:415-423.
12. Kennedy DB, Turley PK. The clinical management of ectopically erupting first permanent molars. *Am J Orthod Dentofacial Orthop* 1987;92:336-345.

<p><b>How to cite this article:</b> John J, Mulammoottil VM, Jose G, Kuriakose S, Kurien A, Prevalence of ectopically erupted teeth in people from age 8 to 25 years- a prospective study. <i>Indian J Orthod Dentofacial Res</i> 2019;5(1):16-18</p>
---