

## Results of core decompression with biological and pharmacological augmentation in osteonecrosis of femoral head in sickle cell positive young adults

Arvind Kumar<sup>1</sup>, Cheraventhan Mani<sup>2</sup>, Smit Vadher<sup>3</sup>, Anirudh Bansar<sup>4</sup>, Sudhir Rawat<sup>5,\*</sup>

<sup>1</sup>Associate Professor and Unit Head, <sup>2-4</sup>Resident, <sup>5</sup>Assistant Professor, Dept. of Orthopaedics, SBKS Medical College, Sumandeep Vidyapith University, Vadodara, Gujarat, India

**\*Corresponding Author: Sudhir Rawat**

Email: sudheerkrawat11@gmail.com

### Abstract

**Introduction:** Osteonecrosis of Femoral head (ONFH) is a common and serious complication of sickle cell disease (SCD). Without early treatment intervention, incidence of femoral head collapse and secondary osteoarthritis is very high and occur early in these patients. Aim of this study is to relieve the symptoms, improve the functional outcomes for better activity of daily life (ADL) and delay the progression of head collapse.

**Materials and Methods:** In this prospective study, 32 hips in 20 pts were selected by exclusion and inclusion criteria. All selected cases were belonging to stage I, II and III according to *modified Ficat and Arlet classification*. Mean age of presentation was 25 years. We did core decompression by making two core tracks of 6 mm diameter each. Biological and pharmacological augmentation was done in the form of autologous cancellous bone graft (ACBG) and oral Alendronate respectively. Percutaneous adductor tenotomy was done in stage IIB and III. Functional and Radiological assessment was done by Harris Hip Score (HHS) and serial X-rays and MRI respectively. Follow up was done up to 96 weeks.

**Results and Discussion:** Average operative time, blood loss and hospital stay were 50 minutes, 40 ml, 7.5 days. Infection rate was only 6.25%. We observed 31.25% excellent, 43.75% good, 12.50% fair and 12.50% poor outcomes. Mean postoperative and preoperative HSS was 83 and 65 respectively.

**Conclusion:** We concluded that this technique is a relatively safe, cost effective, simple to perform, has very low complication rate and an effective treatment option for the younger patients.

**Keywords:** ONFH, SCD, Alendronate, ACBG, ADL, ASIC, HHS.

### Introduction

Osteonecrosis of femoral head (ONFH) has many aetiological factors. Sickle cell disease (SCD) is one of the common aetiological factors for osteonecrosis of femoral head. In SCD patients, ONFH is a cause of chronic severe pain and deterioration of activity of daily living (ADLs). In our study, all the selected patients had varying degree of restriction of ADLs. The first case of sickle cell anaemia was described by Herrick in 1910.<sup>1</sup> ONFH in SCD was first reported as an incidental finding by Huck in 1923.<sup>2</sup> Treatment of ONFH in young adults with SCD is a challenging subject. Without early treatment intervention, incidence of femoral head collapse and secondary osteoarthritis is very high and occur early in these patients (as compared to pts of ONFH due to other causes) which ultimately requires total hip replacement. Rate of femoral head collapse depends largely on site and extent of necrotic segment. Lesion which lies outside the normal stress trajectories may remain structurally intact or collapse slowly while those involving the weight bearing area collapse faster. SCD is a genetic disorder in which red blood cells (RBC) contain abnormal haemoglobin (HbS). In deoxygenated blood, aggregation of the haemoglobin molecules increases leading to distortion of RBC. Initially, this distortion is reversible and RBC regains their normal shape when blood is oxygenated. Eventually RBC membrane become damaged which leads to permanent distortion of RBC.

### Pathogenesis of ONFH in SCD:-

SCD  
↓  
Arteriolar occlusion  
↓  
Marrow oedema  
↓  
Sinusoidal compression  
↓  
Vascular stasis  
↓  
Osteonecrosis.

The exact mechanism of osteonecrosis is a subject of debate. According to Murphy and Shapiro and Diggs small vessel ischemia and arterial spasm may contribute to the destructive process.<sup>3,4</sup> According to Middlemiss and Raper the bone tends to be the common site of ischemia because of diminished circulation and high oxygen utilization.<sup>5</sup> Stockman et al (1972) have been able to demonstrate by angiography large vessel block in sickle cell disease.<sup>6</sup> Rate and course of progression of the disease are unpredictable and radiological picture may not correlate with the clinical symptoms. In SCD patients, clinical symptoms of ONFH appear at very early age compared to ONFH due to other causes. Bilateral involvement is very common and is approximately 40%-80%. Sex incidence is almost equal. Various treatment options exist for ONFH like physical therapy, pharmacotherapy, osteotomies, resurfacing, core

decompression and arthroplasty. Since patients of ONFH in SCD are young, incidence of infection and implant loosening rate are also very high, so the total hip replacement is not an ideal option in these young patients. So this is the study of a treatment modality which resolves the clinical symptoms, improves functional outcomes for better activity of daily life (ADL), delays the progression of femoral head collapse and have low complication rate.

With availability of MRI, it is possible to diagnose the patients of ONFH in the early stage of disease.

## Materials and Methods

This was the prospective analytical study of 32 hips in 20 patients conducted in Department of orthopaedics, SBKSMIRC, Vadodara, Gujarat (India) during the year 2014 to 2016. All cases were selected by inclusion and exclusion criteria. Age of the patients in this study ranged from 18 years to 32 years with mean age of 25 years. Modified Ficat and Arlet classification was used in this study. All selected patients belonged to stage I, II and III. 11 (55%) patients were male and 9 (45%) patients were female. In this study, 12 (60%) patients had bilateral involvement and 8 (40%) patients had unilateral involvement. Among 32 hips, 10 hips were had stage I, 18 hips in stage II and 4 hips in stage III. Functional outcome was assessed by Harris Hip Score (<70 = Poor, 70 – 79 = Fair, 80 – 89 = Good, 90 – 100 = Excellent) and radiological outcome by serial X-ray and MRI on regular follow up interval.

### Operative Procedure

Under spinal or general anaesthesia, patient was placed on standard operating table in supine posture. We made lateral longitudinal incision starting from greater trochanter to 3-5 cm distally. Two guide wires were placed targeting the most necrosed and depressed part of femoral head under c-arm control. Each guide wire was over reamed with 6 mm cannulated drill. Necrosed bone was removed out with help of 6 mm drill tap and small curette. Both track were packed with cancellous bone graft. Percutaneous adductor tenotomy was performed in all hips with stage IIB and III ONFH. Wound was closed in layers and antiseptic dressing applied. Sutures were removed on 13<sup>th</sup> postoperative day.

### Biological Augmentation

Biological augmentation had done in the form of *autologous cancellous bone grafting*. Required amount of autologous cancellous bone graft (ACBG) was taken from anterior superior iliac crest (ASIC). Both core tracks were tightly packed with autologous cancellous bone graft. Hernigou P. et al. reported that core decompression with autologous bone grafting yielded better results as compared to core decompression alone.<sup>7</sup> Cancellous bone grafts become incorporated more quickly and completely than cortical bone grafts.

### Pharmacological Augmentation

*Bisphosphonate (oral Alendronate 70 mg sachet) weekly started prior to surgery and continued for 48 weeks in all patients.* Bisphosphonate inhibits the osteoclastic activity in the osteonecrotic lesion site and thus promote

bone healing. It prevents the onset of subchondral fracture or collapse in early ONFH.

### Postoperative Protocol

On 1<sup>st</sup> postoperative day static quadriceps and ankle pump exercises were started. From 2<sup>nd</sup> postoperative day, all movements of hip, knee and ankle were started. Partial weight bearing was started at 6<sup>th</sup> postoperative week and full weight bearing at 12<sup>th</sup> postoperative week. Follow up visits were done at regular interval of 6<sup>th</sup> week, 12<sup>th</sup> week, 18<sup>th</sup> week, 24<sup>th</sup> week, 48<sup>th</sup> week and 96<sup>th</sup> week.

## Results and Discussion

This was the prospective analytical study of 32 hips in 20 patients conducted in The Department of orthopaedics, SBKSMIRC, Vadodara, Gujarat (India) during the year 2014 to 2016. We performed this operation through a small incision (3-5 cm). Average operative time was 50 minutes (40-60 minutes), average blood loss was 40 ml (30ml - 50ml), average hospital stay was 7.5 days (5-10 days). Pain was relieved in all patients immediately after surgery. Infection rate was very low in this study, only two (6.25%) patients had superficial infection which resolved within a week. All patients with stage I, showed excellent to good outcomes till final follow-up. Among 18 hips of stage II, 14 (77.77%) hips had excellent to good outcomes and 2 (11.11%) hips had fair and 2(11.11%) hips had poor outcome. All hips with stage IIIA had fair to poor outcomes and IIIB had poor outcome. Poor outcomes were observed in stage IIB and stage III. Out of 4 hips of grade III, 2 (50%) hips showed initial improvement in clinical findings up to 36<sup>th</sup> week and 2 (50%) hips up to 48<sup>th</sup> week and there after progressive deterioration was observed. In 2 hips of stage III total hip replacement was done after 20<sup>th</sup> postoperative week. Out of 20 patients on oral alandronate, 2 patients (one with stage II and one with stage III) were not taking regular alandronate. All patients were instructed for partial weight bearing after 6<sup>th</sup> postoperative week but one patient (with stage III) started full weight bearing after 6<sup>th</sup> postoperative week. Over all postoperative clinical outcomes according to HHS – 10 hips (31.25%) had excellent outcome, 14 hips (43.75%) had good outcome, 4 hips (12.50%) had fair outcome and 4 hips (12.50%) had poor outcome. The mean postoperative HSS was 83 (highest was 98 and lowest was 68) and the mean preoperative HSS was 65 (highest was 76 and lowest was 54). Result was shown in table 3.

In our study, among 10 hips of stage I, 6 (60%) hips had excellent and 4 (40%) hips had good outcomes. Among 18 hips of stage II, 4 (22.22%) hips had excellent, 10 (55.55%) hips had good, 2(11.11%) hips had fair and 2 (11.11%) hips had poor outcome. Among 4 hips of stage III, 2 (50%) hips had fair and 2(50%) hips had poor outcomes.

Gangii et al. reported 62.5% femoral head collapse who had core decompression alone while 10% femoral head collapse who had core decompression with bone grafting during two years follow up.<sup>8</sup> Sen RK et al. reported better result with core decompression augmented with autologous bone marrow mononuclear cell infiltration.<sup>9</sup> Stulberg et al.

reported approximately 70% success in patients with Ficat and Arlet stage I, II and III who were operated with core decompression.<sup>10</sup> Kim and associate demonstrated that the multiple drill hole technique for core decompression had a lower rate of collapse.<sup>11</sup> Mukisi-Mukaza et al. demonstrated delayed need for arthroplasty with early core decompression.<sup>12</sup> Studies suggested that core decompression with bone grafting yield better results compared to core decompression alone. Cancellous bone grafts become incorporated more quickly and completely than cortical bone grafts. Some studies have shown complete resolution of the cystic changes and full functional recovery with no pain thereafter.

Beneficial result of bisphosphonate in ONFH has been proved by many studies. Agrawala et al first reported the efficacy of alendronate in the treatment of ONFH and showed that it not only improved the symptoms, but also retarded progression of disease and reduced the rate of collapse of femoral head.<sup>13</sup> Lai et al reported efficacy of alendronate in the treatment of non traumatic ONFH in early stage.<sup>14</sup> Nishii T et al also found beneficial effect of bisphosphonates in treatment of ONFH.<sup>15</sup> Kang P. et al found

better result with multiple drilling and alendronate compare to multiple drilling alone.<sup>16</sup> Al-Jafar H.A et al observed potential benefits of bisphosphonate in ONFH in SCD.<sup>17</sup> Many studies had proved the beneficial effects of bisphosphonate in ONFH.<sup>13-17</sup> In our study, with CD + BG + Alendronate, 75% patients showed excellent to good result while 12.50% patients showed fair and 12.50% poor result. Poor result observed in stage II and stage III.

#### Radiological Observation (on serial MRI & X ray)

In majority of hips with stage I and II ONFH, postoperative follow up MRI showed marked improvement in bone marrow changes with subtle abnormal high signal intensity changes, reduced irregularities with smoothing of articular surface, disappearance of cystic area, and evidence of revascularization as compared to preoperative MRI. Out of 4 hip of stage III, 2 (50%) hip showed neither improvement nor deterioration up to 48<sup>th</sup> week but there after progressive deterioration was observed while in rest 2 (50%) hips progressive deterioration were observed after 12<sup>th</sup> postoperative weeks. Out of 18 hips of stage II, in 1 (5.55%) hip deterioration started after 48<sup>th</sup> week and in 1 (5.55%) hip after 72 weeks.

**Table 1: Showing age, sex and side affected incidence**

Age range	No. of Patients	Involvement U B/L		Sex incidence M F	
18 – 22 years	4	3	1	2	2
23 – 27 years	10	4	6	6	4
28 – 32 years	6	1	5	3	3
Total	20	8 (40%)	12 (60%)	11 (55%)	9 (45%)

U= unilateral, B/L= bilateral, M = male, F= female

**Table 2: Comparative results of different studies**

Studies	Treatment Methods	Results
Gangii et al <sup>8</sup>	CD with BG CD alone	10% pts had head collapse 62.5%pts had head collapse
Stulberg et al <sup>10</sup>	CD alone	70% success rate
Kim and Assoc. <sup>11</sup>	CD (MD)	Lower rate of head collapse
Mukisi-Mukaza <sup>12</sup>	CD	Delayed need for THR
Kang P et al <sup>16</sup>	CD (MD) + Alendronate	Better result compare to CD alone
Al-Jafar HA et al <sup>17</sup>	Bisphosphonate in SCD	Observed potential benefits
Our study	CD + BG + Alendronate	75% excellent to good result 25% fair to poor result

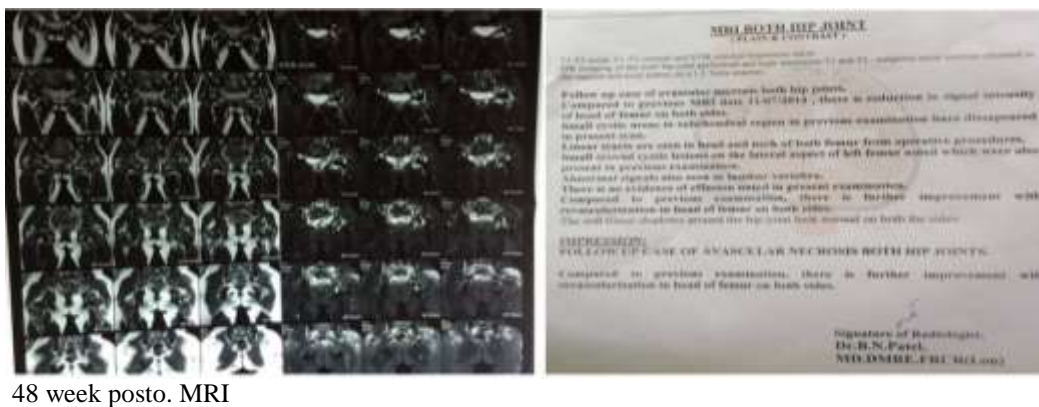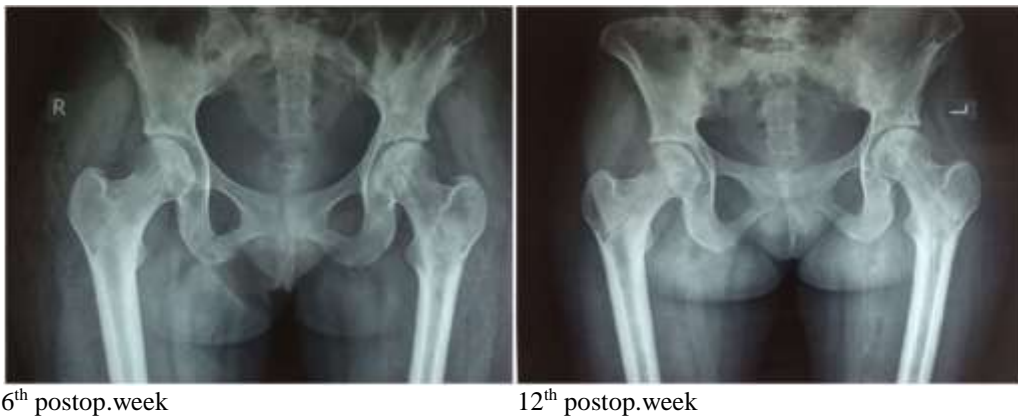CD = core decompression, BG = bone graft, MD= multiple drill

**Table 3: Showing stage by final outcomes (used HHS)**

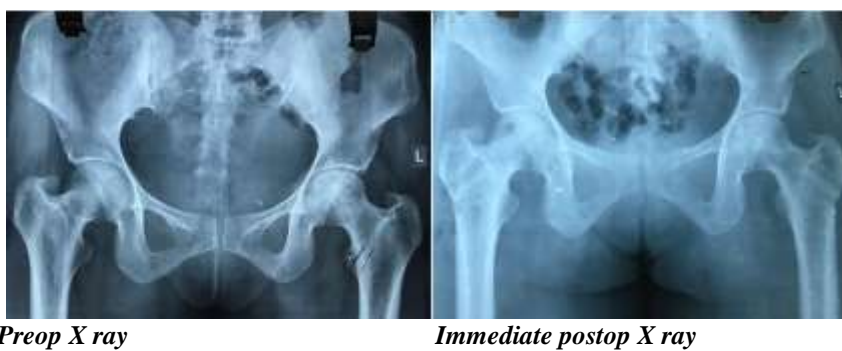Stage	No. of HIPS	Outcomes			
		E (90 -98)	G (80 – 89)	F (70 – 79)	P (<70)
Stage I	10	06	04	0	0
Stage II	18	04	10	02	02
Stage III	04	0	0	02	02
Total	32	10 (31.25%)	14 (43.75%)	04 (12.50%)	04 (12.50%)

E = Excellent, G = Good, F= Fair, P = Poor.

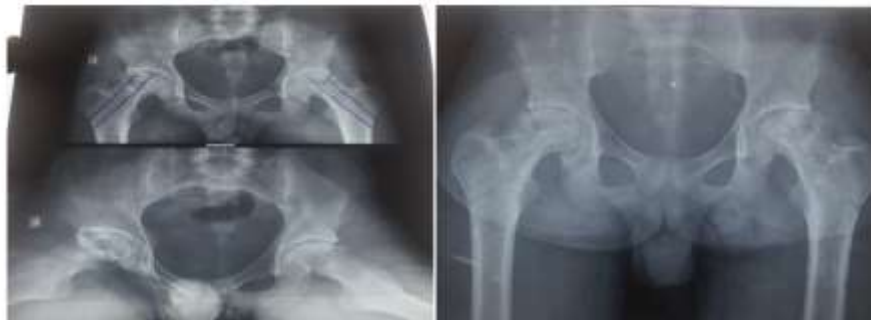**Case 1: 22 years old SCD patient with Stage II ONFH (B/L).**



**Case 2: 30 years old SCD pt with B/L ONFH**

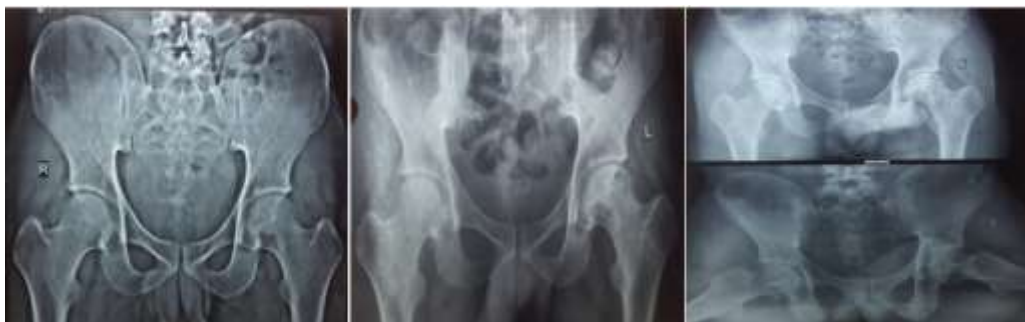

**Case 3: 20 years old SCD pt with B/L stage III ONFH**



Preop X ray 12 weeks postop X ray

**Case 3: 25 years old SCD pt with B/L ONFH**



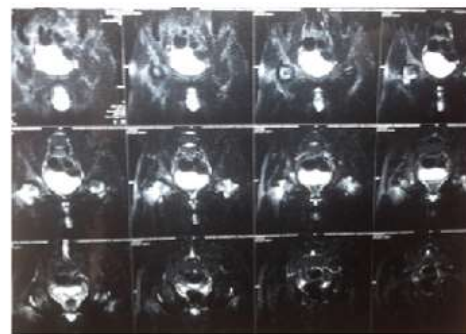
Preop. X ray

12 weeks postop.

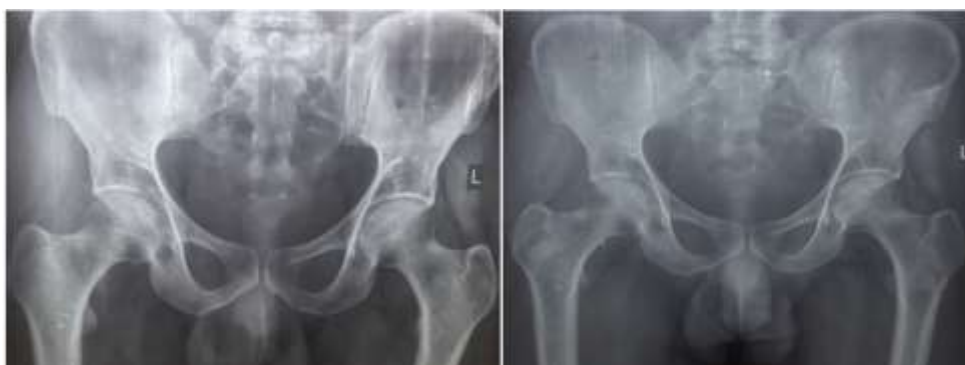24 week postop.



24 week postop. MRI



**Case 4: 26 years male SCD pt with U/L ONFH**



Preop. X ray

12 weeks postop. X ray

## Conclusion

In this study, it is observed that patients with stage I & IIA had excellent to good outcome, stage IIB had good to poor outcome while stage III had fair to poor outcomes. So from this study, it is concluded that in early stage (stage I and II) this method of treatment is a good alternative to relieve symptoms, increase range of movement for better ADL and delay the collapse of femoral head in young patients with osteonecrosis of femoral head in sickle cell disease. It was concluded that core decompression with biological and pharmacological augmentation in ONFH in SCD if done in early stage (stage I and II), outcomes are very impressive. We recommend use of bisphosphonates (oral alendronate 70 mg/week) along with core decompression and autologous cancellous bone grafting in patients with osteonecrosis of femoral head in sickle cell disease. This technique is a relatively safe, simple to perform, has very low complication rate and effective treatment option for the younger patients with osteonecrosis femoral head in sickle cell disease. The only limitation of our study is that our observation was only up to 2 years; so long term observations are still awaited.

**Conflict of Interest:** None.

## References

- Herrick. Peculiar elongated and sickle shaped red blood corpuscles in a case of severe anaemia. *Arch Int Med* 1910;6:517-521.
- Huck J.G. Sickle cell anaemia. *Johns. Hopkins Hosp Bull* 1923;34:335-344.
- Murphy R.C, Shaprio S. The pathology of sickle cell disease. *Ann Intern Med* 1945;23.
- Diggs L.W. sickle cell crisis. *Amer J Clin Path* 1945;44.
- Middlemiss J.H, Raper A.B. Skeletal changes in the haemoglobinopathies. *JBJS*, 1966;48B:693-702.
- Stockman J.A. Occlusion of large cerebral vessels in sickle cell anaemia. *N Engl J Med* 1972;287:846-849.
- Hernigou P, Beaujean F. Treatment of Osteonecrosis with autologous bone marrow grafting. *Clin Ortho Relat Res* 2000;(405):14-23.
- Gangii V, Hauzeur J.P. Treatment of Osteonecrosis of the femoral head with implantation of autologous bone marrow cells. *JBJS* 2005;87:106-112.
- Sen R.K, Tripathy S.K, Agrawal S. Early results of core decompression and autologous bone marrow mononuclear cell instillation in femoral head Osteonecrosis. *J Arthroplast* 2012;27:679-686.
- Stulberg B.N. Osteonecrosis of femoral head. A prospective randomized treatment protocol. *Clin Orthop Relat Res* 1991;(268):140-151.
- Kim S.Y, Kim D.H, Park I.H. Multiple drilling compared with standard core decompression for the treatment of Osteonecrosis of femoral head. *JBJS(Br)* 2004;86-B:149.
- Mukisi-Mukaza M, Manicom O, Alexis C. Treatment of sickle cell disease's hip necrosis by core decompression: a prospective case control study. *Orthop Traumatol Surg Res* 2009;95:498-504.
- Agrawala S, Shah S.B. Ten year follow up of avascular necrosis of femoral head treated with Alendronate for 3 years. *J Arthroplast* 2011;26,(7):1128-1134.
- Lai K.A, Shen W.J, Yang C.Y. Use of alendronate to prevent early collapse of femoral head in patients with nontraumatic Osteonecrosis. *JBJS Am* 2005;87:2155-2159.
- Nishii T, Sugano N, Miki H, Hashimoto J, Yoshikawa H. Does alendronate prevent collapse in Osteonecrosis of femoral head? *Clin Orthop Relat Res* 2006;443:273-279.
- Kang P, Pei F, Shen B, Zhou Z, Yang J. Are the result of multiple drilling and Alendronate for Osteonecrosis of the femoral head better than those of multiple drilling? A pilot study. *JBS* 2012;79(1):67-72.
- Al-Jafar H.A, Al-Ali NS, Ali A, Alobaid A. medical and surgical treatment options for early Osteonecrosis in sickle cell disease. *Ann Hematol Oncol* 2016;3(5):1092.
- Haddad, R.J. Sickle cell disease involvement of hip and its surgical treatment. *Clin Orthop* 1970;55:135-149.
- Epps C.H Jr, Castro O. Complication of total hip replacement in sickle cell disease. *Orthop Trans* 1978;2:236-237.
- Pierce, R.O. Aseptic necrosis of the hip in SCD. *J Natl Med Asso* 1979;71,1:45-48.
- Hanker C.J, Amstutz H.C. Osteonecrosis of the hip in the sickle cell disease: treatment and complication. *JBJS* 1988;70-A:499-506.
- Rajagopal M, Balch Samora J, Ellis TJ. Efficacy of core decompression as treatment for Osteonecrosis of hip: a systemic review. *Hip Int* 22:489-493.

**How to cite this article:** Kumar A, Mani C, Vadher S, Bansar A, Rawat S. Results of core decompression with biological and pharmacological augmentation in osteonecrosis of femoral head in sickle cell positive young adults. *Indian J Orthop Surg* 2019;5(1):4-9.