

Study of functional outcome of unipolar and bipolar hemiarthroplasty in fracture neck of femur

R. Sahaya Jose

Assistant Professor, Dept. of Orthopaedics, Sree Mookambika Institute of Medical Sciences, Kanyakumari, Tamil Nadu, India

***Corresponding Author: R. Sahaya Jose**

Email: drjose07@yahoo.co.in

Abstract

Introduction and Objectives: The Aim of this study is to evaluate the Short Term Functional Outcome of Unipolar and Bipolar hemiarthroplasty in Intracapsular neck of femur fracture.

Materials and Methods: 40 patients with Intracapsular fracture neck of femur were included in this study. 20 patients were treated with unipolar hemiarthroplasty and 20 patients with bipolar hemiarthroplasty, respectively. In both the groups, patients were evaluated for functional outcome by using Harris hip score. The Data was analysed by SPSS 20.00 using Chi-square test.

Results: Our overall mean Harris hip score pre operatively for unipolar hemiarthroplasty was 36.2 and bipolar hemiarthroplasty was 39.1 which increased to 81.8 for unipolar and 85.05 for bipolar hemiarthroplasty respectively, with p-value of <0.561. Our results also shows that we have 35% excellent result in Bipolar whereas we have 15% excellent result in unipolar Hemiarthroplasty group.

Conclusion: The results of our study shows that uncemented bipolar hemiarthroplasty gave better results when compared with uncemented unipolar hemiarthroplasty. Our results also shows that, cemented bipolar hemiarthroplasty gave better results when compared with cemented unipolar hemiarthroplasty clinically. Thus, Bipolar hemiarthroplasty did better when compared with unipolar hemiarthroplasty in general.

Keywords: Unipolar hemiarthroplasty, Bipolar hemiarthroplasty, Fracture neck of femur, Harris hip score.

Introduction

The hip joint forms connection between the lower limb and pelvic girdle. The hip joint is designed for stability as well as for a wide range of movements. This multiaxial ball and socket joint allows the entire lower extremity to move in three planes of motion, while providing an important shock absorption function to the torso and upper body.

Pain in the hip joint is one of the most important causes in disabling the human locomotion. There are many ways and methods by which this crippling pain in the hip can be treated.

Hemiarthroplasty is an operation to restore motion and stability to a joint and function to the muscle, ligaments and other soft tissue structures that control the joint. Implanting an artificial femoral stem to replace the fractured one exerted such a profound social impact and enjoyed such a dramatic early success.

Intracapsular fracture neck of femur account for a major share of fractures in the elderly. The primary goal of treatment is to return the patient to his or her pre-fracture functional status.¹

For displaced fractures of the femoral neck, reduction, compression, and rigid internal fixation are required if union is to be predictable. Because nonunion and osteonecrosis, develop frequently after internal fixation of displaced femoral neck fractures, many surgeons recommend primary prosthetic replacement as an alternative in elderly ambulatory patients.²

Prosthetic replacement allows immediate weight bearing to return elderly patients to activity and help avoid complications of recumbency and inactivity. When the concept of prosthetic replacement was first introduced, this perhaps was the most important advantage. As a primary

procedure, prosthetic replacement eliminates osteonecrosis and nonunion as complications of femoral neck fractures.

The complications of persistent pain and protrusioacetabuli with unipolar hemiarthroplasties have led many surgeons to choose a bipolar system. Studies suggest that the current generation of bipolar hemiarthroplasties have a lower incidence of protrusioacetabuli than do earlier designs. Some authors have found, however, that the motion of the inner bearing surface may not last, and that all bipolar hips functionally become unipolar implants.

The decision to perform hemiarthroplasty using a unipolar or bipolar prosthesis remains controversial, with proponents on either side. Advantages of the unipolar prosthesis include lower cost and no risk of polyethylene wear debris. Proposed advantages of the bipolar prosthesis include less acetabular wear and potentially less hip/groin pain.³

So in view of these varied opinions we desire to compare the efficiency of these two prosthesis unipolar and bipolar prosthesis for the management of intracapsular fractures of neck of femur in elderly people.

In our center both cemented and uncemented unipolar and bipolar hemiarthroplasties were done and we have decided to evaluate the short term functional outcome of unipolar and Bipolar hemiarthroplasty using Harris hip score (HHS) with a mean follow up of 44.85 months and 44.1 months respectively.

Materials and Methods

Study Design: Comparative study.

Study Settings: Orthopaedics outpatients and inpatients in Sree Mookambika Institute of Medical Sciences, Kulasekharam.

Duration of the Study: 18 months (December 2015 to April 2017).

Total number of groups: 2

Detailed description of the study groups

1. First Group: Unipolar Hemiarthroplasty
2. Second Group: Undergoing Bipolar Hemiarthroplasty.

Sampling

1. Sample size of each group: 20
2. Total sample size of the study: 40
3. Scientific basis of sample size used in the study:

$$\text{Sample size (n)} =$$

$$\left\{ Z_1 \sqrt{2 p(1-p)} + Z_2 \sqrt{p_1(1-p_1) + p_2(1-p_2)} \right\}^2$$

$Z_1 = Z$ value associated with set of $\alpha = 1.64$ [fixed]

$P_1 =$ probability of outcome in unipolar = 79.79

$P_2 =$ probability of outcome in bipolar = 86.18

$$p = \frac{P_1 + P_2}{2} = 0.82$$

Sample size = 19.5 = 20

So, sample size for unipolar = 20 and Sample size for bipolar = 20

Sampling Technique: Convenient sampling

Inclusion Criteria

1. Displaced Intracapsular fracture neck of femur with adequate calcar.
2. Male and female patients of age 60 years and above.
3. Neglected Intracapsular fracture neck of femur more than 3-4 weeks old in elderly patients.
4. Non-union of Intracapsular fracture neck of femur in elderly patients.
5. Unilateral fracture neck of femur.

Exclusion Criteria

1. Fracture neck of the femur in younger patients.
2. Extracapsular fracture neck of femur.
3. Patient with neurological disorders.
4. Patients associated with any other ipsilateral or contralateral fracture of upper and lower extremities.
5. Pathological fracture neck of femur.
6. Fracture neck of femur with shaft of femur fracture.
7. Bilateral fracture neck of femur.

Table 1: Comparison between Unipolar and bipolar prosthesis

	Unipolar	Bipolar
Total No. of Patients	20	20
Total No. of Hips	20	20
Age	64 to 82 years (mean 69.45 years)	65 to 88 years (mean 74.6 years)
Cemented / Uncemented	Cemented = 10 Un cemented = 10	Cemented = 10 Un cemented = 10
Right/Left	Left = 11 Right = 9	Left = 12 Right = 8
Approach	Posterior	Posterior
Unilateral / Bilateral	20/0	20/0
Study	Retrospective and Prospective	Retrospective and Prospective
Follow up	12 to 85 months (Mean follow up – 48.2 months)	12 to 84 months (Mean follow up – 46.2 months)

Follow Up

Prospective patients were reviewed regularly at 6 weeks, 6 months, 1 year and then yearly follow up.

Retrospective study patients were reviewed every yearly.

Patients were assessed radiologically and assessed clinically using Harris hip score.

Results

The 20 hips each for unipolar and bipolar were evaluated clinically. Clinical evaluation was done using Harris hip score which reveals the following results.

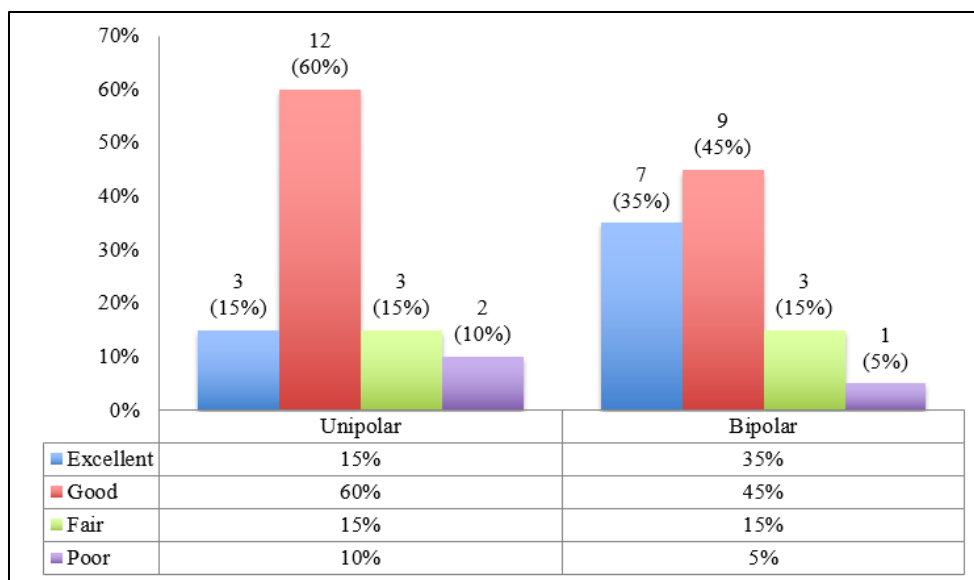


Fig. 1: Unipolar and bipolar hemiarthroplasty – functional results

Unipolar and Bipolar Hemiarthroplasty – Functional Results

Table 2: Comparison of unipolar and bipolar hemiarthroplasty - functional results

Functional Results	Unipolar(20)		Bipolar(20)	
	Uncemented(10)	Cemented(10)	Uncemented(10)	Cemented(10)
Excellent	3(30%)	0(0%)	5(50%)	2(20%)
Good	3(30%)	9(90%)	3(30%)	6(60%)
Fair	2(20%)	1(10%)	2(20%)	1(10%)
Poor	2(20%)	0(0%)	0(0%)	1(10%)

Table 3: Comparison of pre-op and latest Harris Hip score of unipolar and bipolar hemiarthroplasty

HSS	Mean pre-op	Mean latest	Mean Difference
Unipolar	36.2	81.8	45.6
Bipolar	39.1	85.05	45.95

Complications of Unipolar Hemiarthroplasty

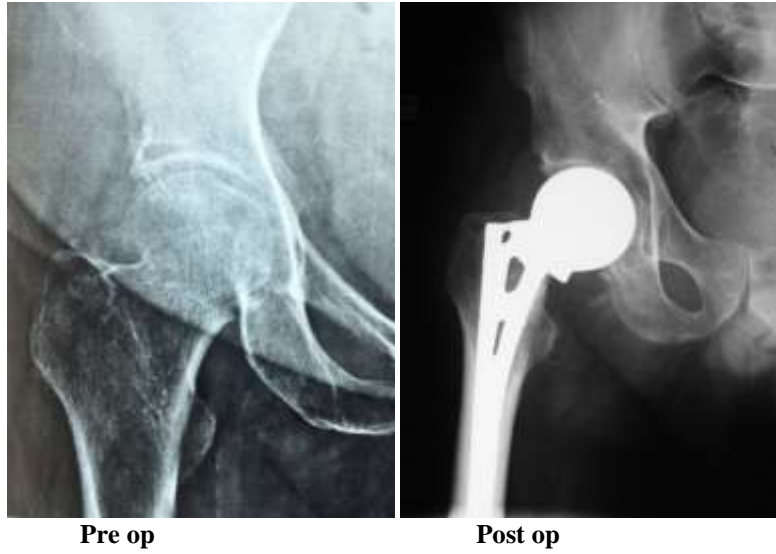
1. Heterotopic Ossifications → 1 (5%)
2. Limb Length discrepancy → 2 (10%)
3. Sciatic nerve palsy → 1 (5%)
4. Periprosthetic fracture → 1 (5%)
5. Acetabular erosion → 2 (10%)

Complications of Bipolar Hemiarthroplasty

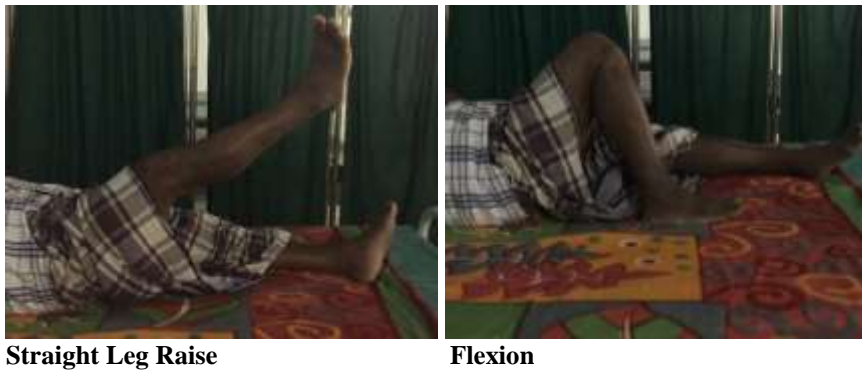1. Heterotopic Ossifications → 1 (5%)
2. Limb Length discrepancy → 1 (5%)
3. Sciatic nerve palsy → 1 (5%)
4. Periprosthetic fracture → 1 (5%)
5. Acetabular erosion → 1 (1%)

Clinical Examples

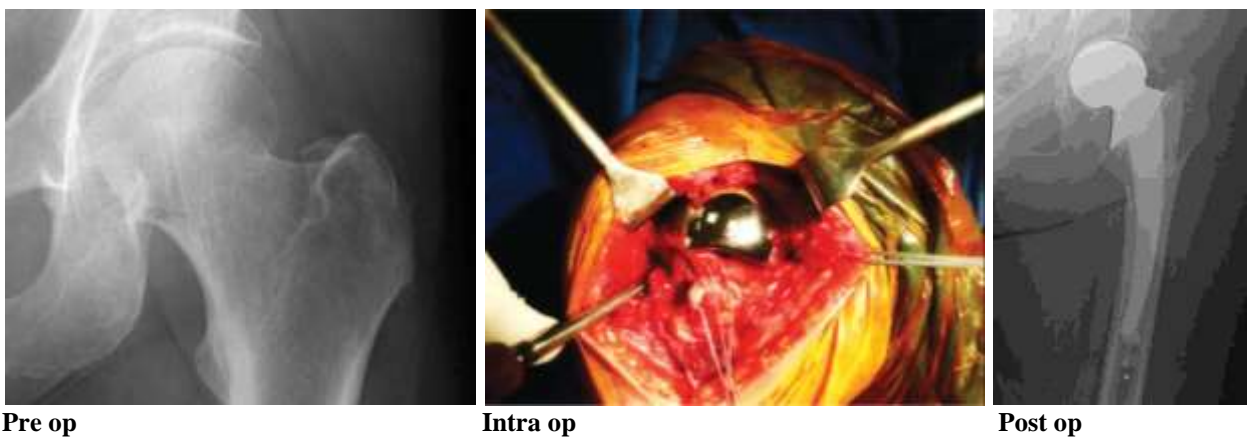
- I. Unipolar Hemiarthroplasty
- II. Case 1 – Excellent Result
- III. Pre op HHS – 36
Latest HHS - 92



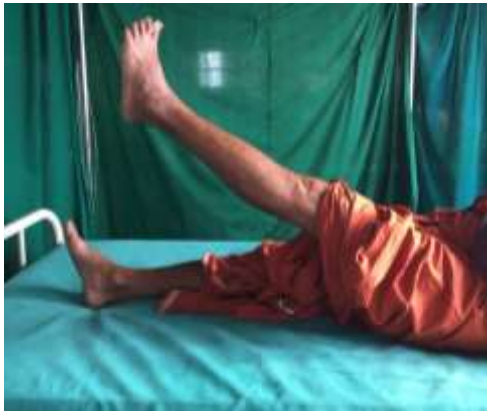Case 1: Excellent Result



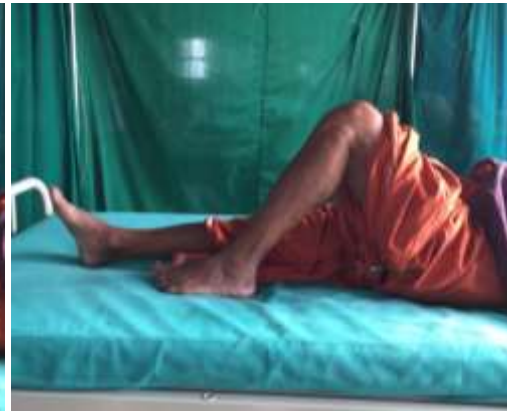Case 2: Good Result
Pre op HHS – 39
Latest HHS – 88



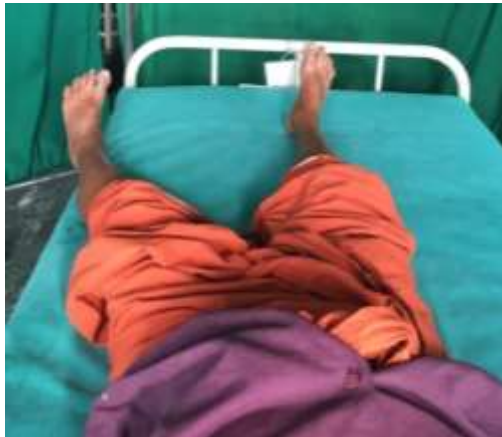Case 2: Good Result



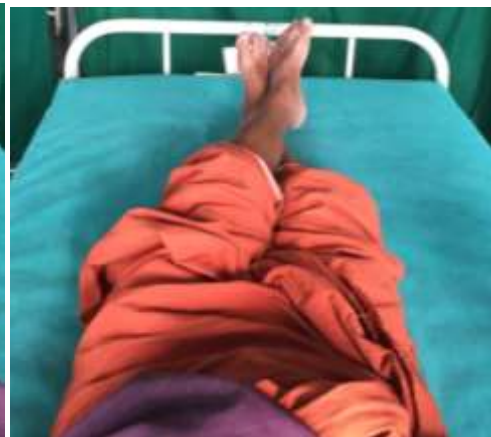Straight Leg Raise



Flexion



Adduction

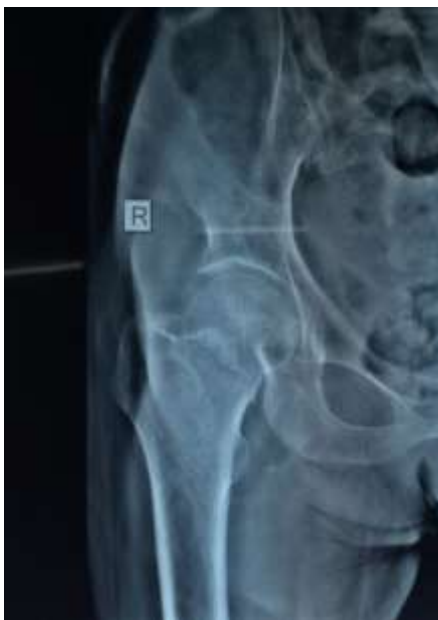

Abduction

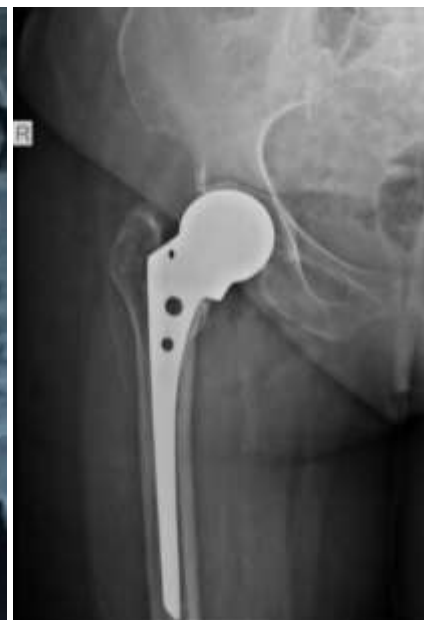Case 3: Poor Result

Pre op HHS – 34

Latest HHS – 58

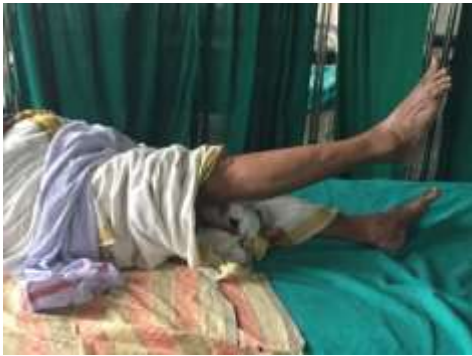

Pre op

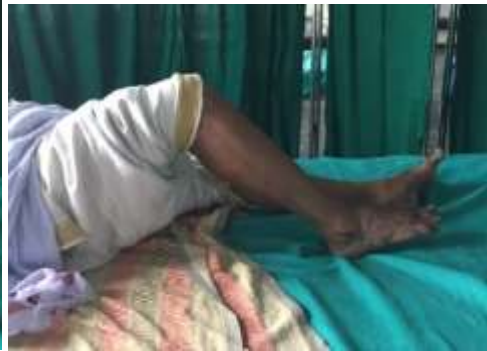

Post op

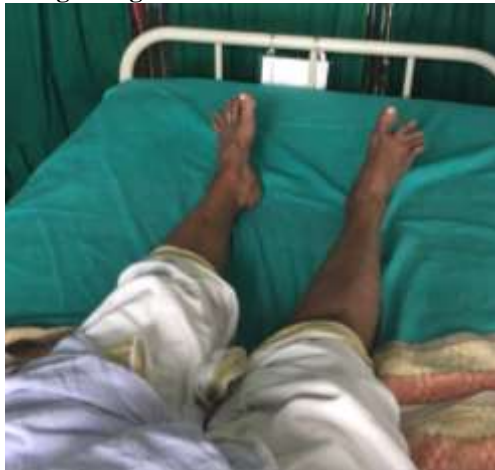Case 3: Poor Result



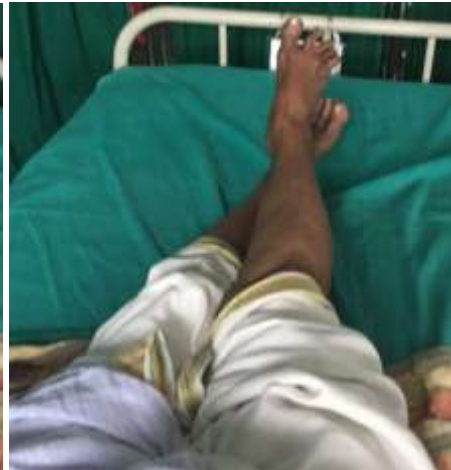Straight Leg Raise



Flexion



Abduction



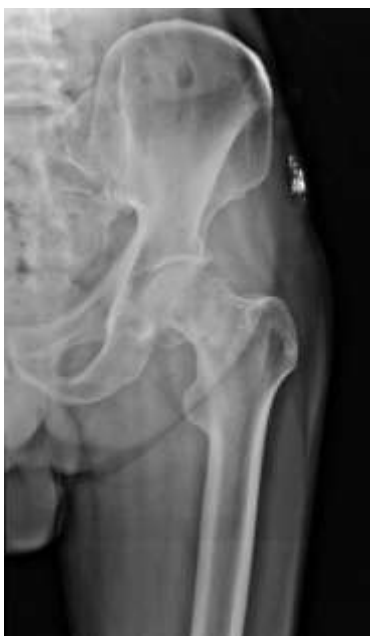Adduction

II. Bipolar Hemiarthroplasty

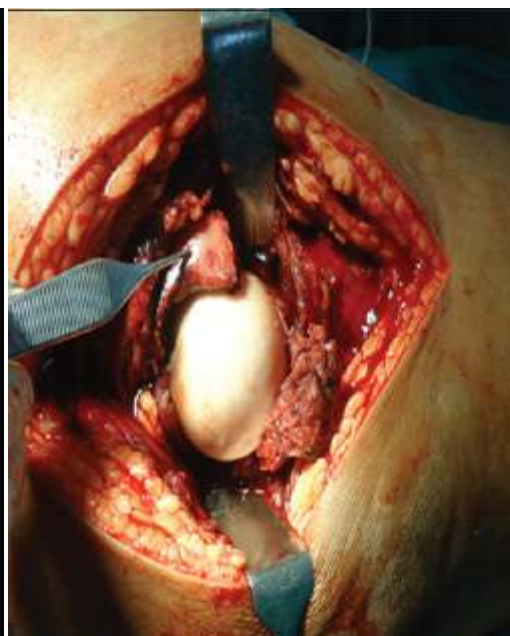
Case 1 – Excellent Result

Pre op HHS – 53

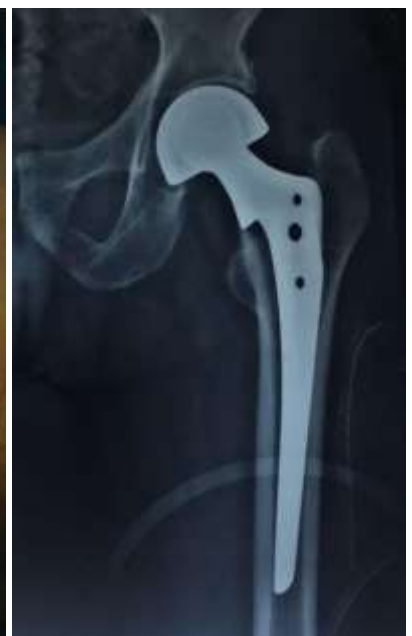Latest HHS – 92



Pre op

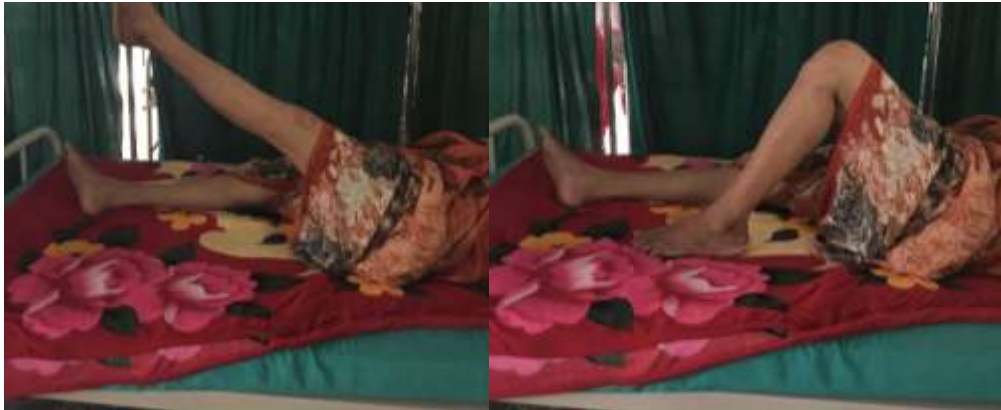

Intra op



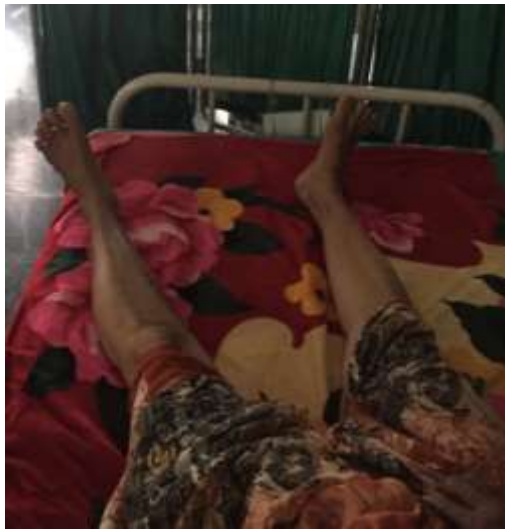Post op

Case 1: Excellent Result

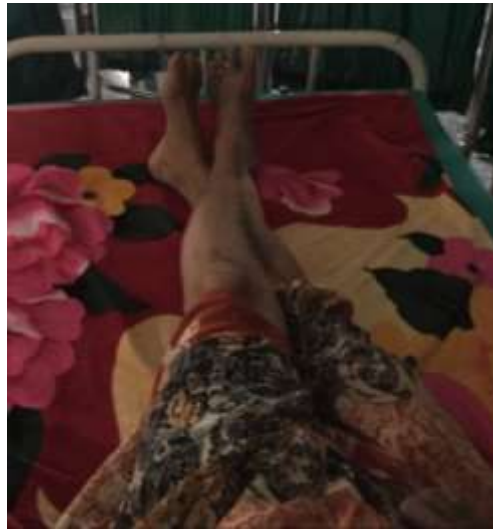

Straight Leg Raise

Flexion

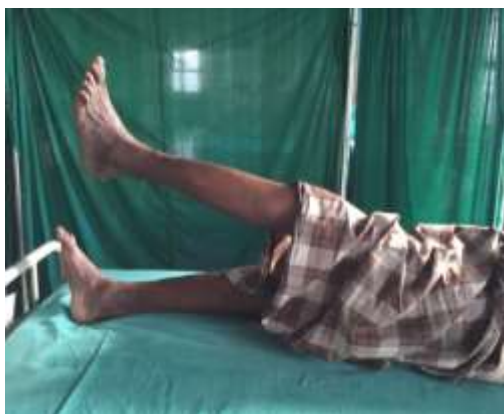

Abduction

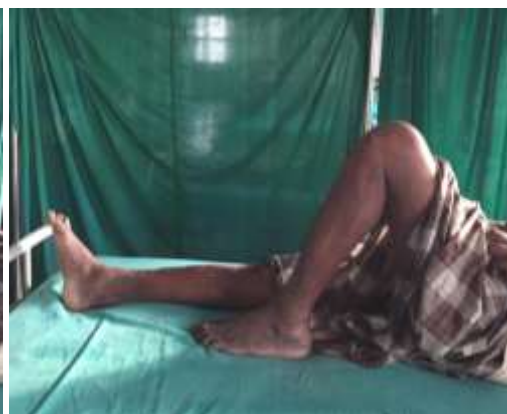

Adduction

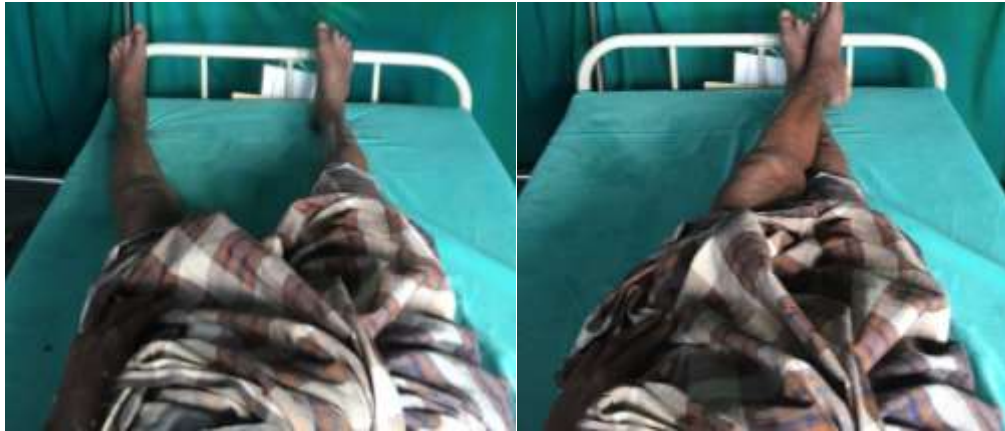Case 2: Good Result



Straight Leg Raise



Flexion



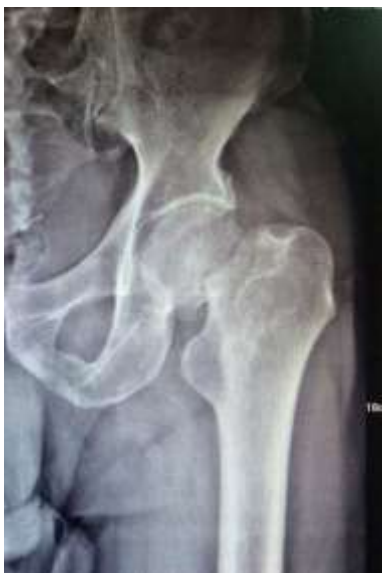Abduction

Adduction

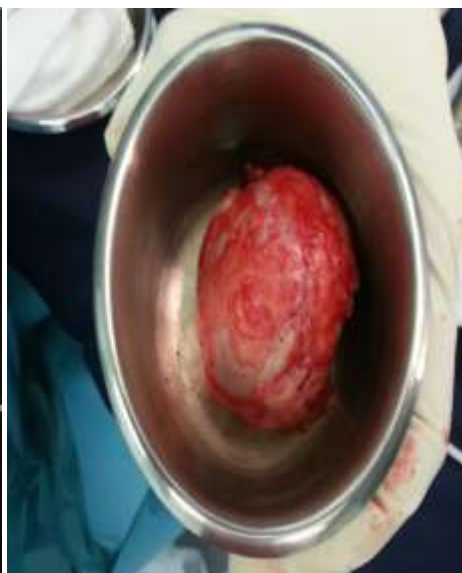
Case 3: Poor Result

Pre op HHS – 22

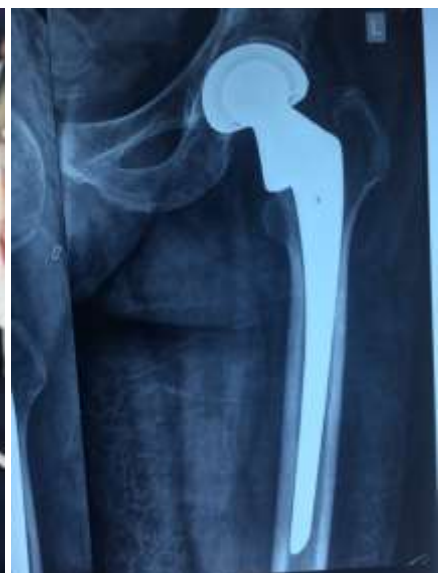Latest HHS – 65



Pre op

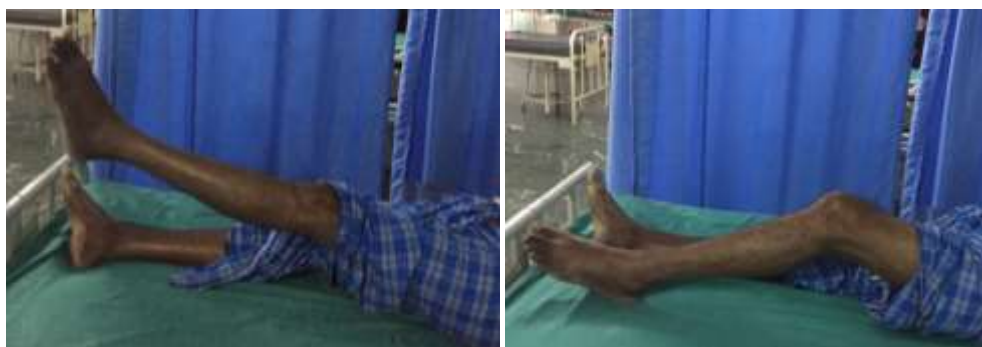

Intra op – Resected femoral head



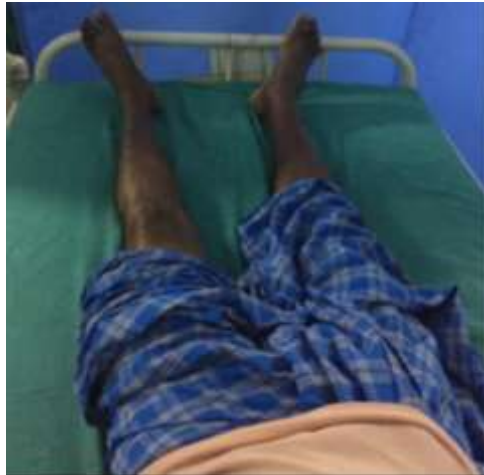Post op

Case 3: Poor Result

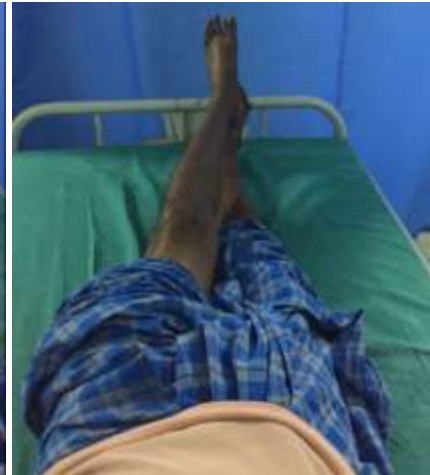

Straight Leg Raise

Flexion

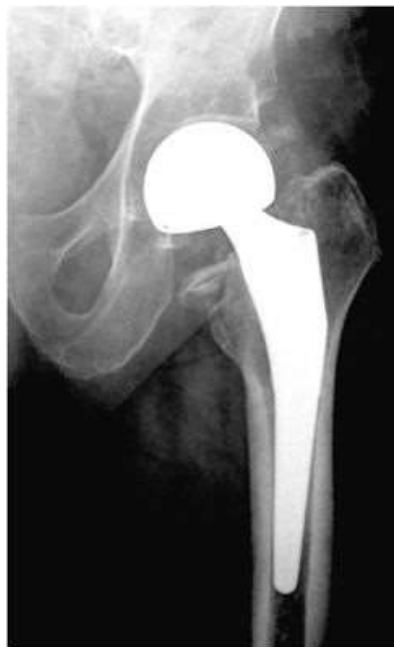

Abduction

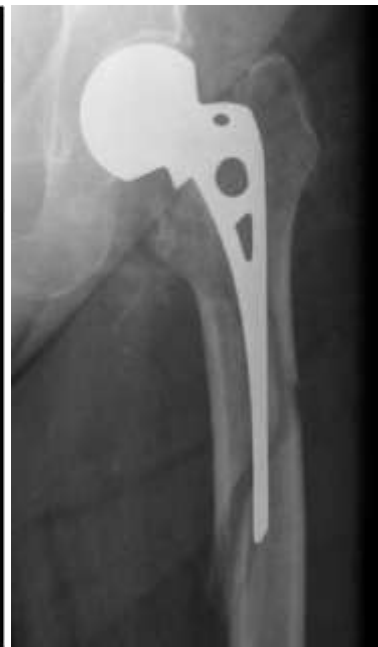

Adduction

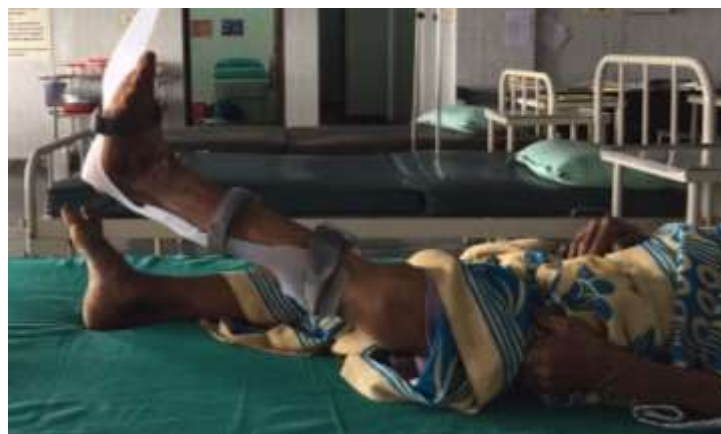Complications



Heterotopic ossification



Periprosthetic fracture



Sciatic nerve palsy

Discussion

Hemiarthroplasty, as an effective technique for femoral neck fractures, could help early ambulation and satisfied function recovery and is increasingly performed by the surgeons.⁴⁻⁶ However, controversy has persisted for a long time regarding the use of bipolar versus unipolar prosthesis. This study suggests that (1) Bipolar hemiarthroplasty is associated with similar or better improvement in hip functionality, hip pain, and quality of life compared with Unipolar hemiarthroplasty while with a higher cost and that (2) there are no significant differences between Bipolar hemiarthroplasty and Unipolar hemiarthroplasty with regard to operation time, blood loss, blood transfusion, hospital stay, mortality, reoperation, dislocation, and complications, and that (3) Bipolar hemiarthroplasty could not decrease acetabular erosion rate in the long term.

Compared with Unipolar hemiarthroplasty, bipolar prosthesis with an additional inner articulation has the theoretical advantages of less acetabular erosion and less dislocation.⁷⁻⁸

This study demonstrates that the incidence of acetabular erosion in Bipolar hemiarthroplasty is less than that in the Unipolar hemiarthroplasty group at the follow-ups. However, statistical difference was only noted at 1 year follow-up and the acetabular erosion rate increased at the later follow-ups. This may be because the bipolar articulation loses mobility with time and functions as a Unipolar hemiarthroplasty.⁹ Regarding to dislocation, it is not proved to be less comparing Bipolar hemiarthroplasty with Unipolar hemiarthroplasty in this study.

Pain following hemiarthroplasty is usually due to one of the two pathological processes: articular cartilage degeneration in the acetabulum or loosening of the prosthesis.

In the unipolar study Jadhav AP et al,¹⁰ reported mean age 65.7, Onche and Yinusa showed mean age in the study 67.4, in another study of Esho J.B Sie M. Da et al reported range of the age 55-88 years with the standard deviation of 7.2. Similarly in this study mean age 69.45 was showed as mean \pm SD 64.98 \pm 4.13. In the study of Ahmed I, 15 reported male female ratio was 1:2. While in this study female were in the majority as compare to male with the 11:9.

According to the unipolar study of Barners CL et al.¹¹ dislocation rate was 1.5%. Other authors reported 4% dislocation rate. Noor SS,¹² reported 0% dislocation in their study with unipolar hemiarthroplasty. We have 0% dislocation rate because we fasten abduction pillow to the leg postoperatively, for 1 to 2 weeks, along the careful shifting of the patients from theatre table to the bed and also for X-ray. Postoperative wound infection 0% reported by Noor SS,¹² and 7.5% reported by Dinesh Dhar.¹³ In general, duration of operation has been proven conclusively to be a potent risk factor in the development of postoperative infection. We have only 4% superficial infection, because all the surgeries were performed by senior surgeons having less operating time with pre and post antibiotic cover and the special care was taken for patients hygiene and theatre

condition. And those superficial infection settled well and now patients are not having any infections.

In the study of Anshu Shekhar et al¹⁴ reported outcome of hemiarthroplasty treatment in patients with femoral neck fracture as excellent 43.5%, good 38.4%, fair 11.3% and poor 6.8%. Dinesh Dhar et al reported outcome of Austin-Moore in femur neck fracture outcome excellent 80.2% and fair 19.8%. Noor SS et al reported outcome as, excellent 38%, good 21%, fair 24% and poor 17.3%. Similarly in the present study outcome in 45 remaining patients was as; the excellent results were found in the 44.44% of the study participants, good and satisfied results were seen with the percentage of 26.66% and 20% respectively while poor results were seen in 8.88% of the patients.

Table 4: Comparison of Functional results with previous studies

Functional Result	Anshu Shekhar et al ¹⁴	Our Study
Excellent	43.5%	15%
Good	38.4%	60%
Fair	11.3%	15%
Poor	6.8%	10%

Conclusion

1. Based on Harris hip score we have 15% of excellent results in unipolar and 35% in bipolar hemiarthroplasty. We have 60% good results in unipolar and 45% in bipolar hemiarthroplasty and 15% fair result in each.
2. Bipolar hemiarthroplasty gave better results than unipolar hemiarthroplasty in both cemented and uncemented groups.
3. Acetabular erosion is the most common complication in unipolar hemiarthroplasty than the bipolar hemiarthroplasty.
4. Overall mean Harris hip score pre-operatively for unipolar was 36.2 and bipolar hemiarthroplasty was 39.1 which increased to 81.8 for unipolar and 85.05 for bipolar hemiarthroplasty respectively, with the p-value of <0.561.

Conflict of Interest: None.

References

1. Marya SKS, Thukral R, Singh C. Prosthetic replacement in femoral neck fracture in the elderly: Results and review of the literature. *Indian J Orthop* 2008;42(1):61-67.
2. Canale ST. Hip fractures and dislocations. Campbell's Operative Orthopaedics, 11th ed. Mosby;2012.
3. Victor CR. Unipolar versus bipolar Arthroplasty. *Tech Orthop* 2004;19(3):138-142.
4. Bhandari M, Devereaux PJ, Tometta P 3rd. Operative management of displaced femoral neck fractures in elderly patients. An international survey. *J Bone Joint Surg Am* 2005;87:2122-130.
5. Iorio R, Schwartz B, Macaulay W, Teeney SM, Healy WL, York S. Surgical treatment of displaced femoral neck fractures in the elderly: a survey of the American Association of Hip and Knee Surgeons. *J Arthroplasty* 2006;21:1124-1133.

6. Crossman PT, Khan RJ, MacDowell A, Gardner AC, Reddy NS, Keene GS. A survey of the treatment of displaced intracapsular femoral neck fractures in the UK. *Inj* 2002;33:383-386.
7. Bhattacharyya T, Koval KJ. Unipolar versus bipolar hemiarthroplasty for femoral neck fractures: is there a difference? *J Orthop Trauma* 2009;23:426-427.
8. Gilbert MS, Capozzi J. Unipolar or bipolar prosthesis for the displaced intracapsular hip fracture? An unanswered question. *Clin Orthop Relat Res* 1998;353:81-85.
9. Inngul C, Hedbeck CJ, Blomfeldt R, Lapidus G, Ponzer S, Enocson A. Unipolar hemiarthroplasty versus bipolar hemiarthroplasty in patients with displaced femoral neck fractures. A four-year follow up of a randomized controlled trial. *Int Orthop* 2013;37:2457-2464.
10. Jadhav AP, Kulkarni SS, Vaidya SV, Divekar MM, Suralkar SP. Results of Austin Moore replacement. *J Postgrad Med* 1996;42:33-38.
11. Barnes CL, Berry DJ, Sledge CB. Dislocation after bipolar hemiarthroplasty of the hip. *J Arthroplasty* 1995;10:667-669.
12. Noor SS, Hussain N, Javed I. Outcome of Austin Moore hemiarthroplasty in elderly patients with fracture neck of femur. *J Pak Orthop Assoc* 2010;22(1):14-19.
13. Dhar D. Early Results of Austin Moore Prosthesis in Elderly Patients with fracture neck femur. *J Orthop* 2007;4(1)e3.
14. Shekhar A, Murgod G, Korlhalli S. Two years outcome of cemented Austin Moore hemiarthroplasty for fracture neck femur. *J Dent Med Sci* 2013;11(6):10-15.

How to cite this article: Jose RS. Study of functional outcome of unipolar and bipolar hemiarthroplasty in fracture neck of femur. *Indian J Orthop Surg* 2019;5(1):72-82.