

To evaluate the functional outcomes in patella rim cauterized total knee arthroplasty

Ashwin Shetty¹, Nikhil Manvi^{2*}, Sanath Kumar Shetty³

¹MS Ortho, ²Junior Resident, ³DNB Ortho, Dept. of Orthopaedics, KS Hegde Medical Hospital, Karnataka, India

***Corresponding Author: Nikhil Manvi**

Email: manvinikhil33@gmail.com

Abstract

Introduction: In post Total Knee Arthroplasty (TKA) patient's anterior knee pain is considered to be a major problem. Anterior knee pain reduces patients satisfaction post TKA in almost one fourth of the cases. With an increase in number of TKA performed and higher demands of patients for quality of life, anterior knee pain attracts increasing attention from orthopaedic surgeons. Suggestions are there that anterior knee pain is caused due to distribution of nerve fibers and substance - P in soft tissue around the patella. Patella denervation by electrocautery can theoretically interrupt these pain receptors and reduce anterior knee pain. Hence, the aim of our study is to evaluate the effect of electrocautery on Patellar Non resurfacing TKA.

Materials and Methods: This is an observational study of the patients undergoing TKA (unilateral/bilateral) at from September 2016 to August 2018, diagnosed with Osteoarthritis (primary/secondary) of the knee joint. 66 patients were included into the study undergoing non resurfacing TKA, 33 underwent patellar rim cauterization and 33 were taken as control. Statistical analysis was evaluated with ROM, KSS (functional/objective), WOMAC and Feller's scoring at preoperative, 6weeks, 12weeks and 24 weeks postoperative periods.

Result: Significant improvement in the scores were noted from pre-operative to post-operative period in the patient who underwent patellar rim cauterization. But when compared between cautery and control group some statistically significant difference was noted in the KSS objective scoring in favor of circumpatellar cautery at 6weeks, but at 12 and 24 weeks no significant difference were noted. Whereas, no significant difference were found in the remaining scoring systems at 6, 12 and 24 weeks.

Conclusion: The use of electrocautery of patella rim in non-resurfacing total knee replacement had better results as per KSS objective scores at 6 weeks. However after 6 weeks follow up similar clinical outcomes were noted. Hence, we conclude electrocautery of patellar rim is not an effective measure for relieving anterior knee pain.

Keywords: Total knee arthroplasty, Electrocautery, Anterior knee pain, patellar rim MeSh terms- Arthroplasty, Knee joint, Patella, Osteoarthritis, Anterior knee pain, Patella innervation, Range of motion.

Introduction

Total knee arthroplasty (TKA) is considered a major orthopaedic surgery which is an established reliable means to correct deformity, restore joint function and relieve pain in osteoarthritic knees.¹⁻³ Anterior knee pain tends to decrease patient functional satisfaction⁴ and is noted in up to 25% of the patients after TKA.⁵ Normal cartilage does not carry any nerve supply, basically it is aneural, hence the lesions over the surface cant induce pain. Patella associated problems are usually the cause for patient dissatisfaction, reoperation after TKA and morbidity. Anterior knee pain has been noted in 4 to 49% of patients after TKA.^{6,7} Some studies have implicated other causes for the pain such as retinaculum, synovium and infrapatellar fat pad.^{8,9}

Extensive studies have been done over the innervation of the anterior knee and have found substance - P nociceptive afferent fibers in peripatellar soft tissue.^{10,11} By disabling these pain receptors by electrocautery, we can theoretically achieve denervation of anterior knee region.^{12,13} Basically, denervation of patella with the use of cautery and patelloplasty, where the osteophytes are removed, is used for the treatment of knee pain in anterior region in TKA.¹⁴⁻¹⁶ This has got an easy implementation and fewer additional surgical procedures. Theoretically, it should interrupt the patella peripheral nerve conduction, hence blocking the pain receptors and give pain relief.^{17,18} Hence, the aim of our study is to evaluate the functional outcomes of patellar rim cauterization and our hypothesis is that patellar denervation provides some benefit in terms of

pain relief and clinical outcomes after TKA without patellar resurfacing.

Materials and Methods

It is an observational study and all patients undergoing TKA (unilateral/bilateral) between September, 2016 and August, 2018 are included after explaining the procedure and getting the consent.

Total of 66 cases were included into the study, in which 33 patients underwent non resurfacing TKA with patellar rim cauterization using electrocautery, and 33 patients underwent non resurfacing TKA without patella denervation and were taken as control Convenience sampling was done for all the cases and divided into two groups as mentioned above.

Inclusion and exclusion criteria for the study is as follows-

Inclusion Criteria

1. Primary Osteoarthritis
2. Secondary Osteoarthritis

Exclusion Criteria

1. Previously underwent hip arthroplasty.
2. History of patellar fracture.
3. Rheumatoid Arthritis.

Procedure and Technique

All procedures were carried out in sterile operation theatres after taking informed consent. In all cases fixed bearing posterior cruciate ligament sacrificing implants were used with cement.

Tourniquet was used for all cases. Medial parapatellar approach was made in all the patients. After a linear skin incision was made, capsular incision was done in medial parapatellar line to expose both the femoral condyles and the proximal tibia. If synovial thickening was noted in a given patient, a synovectomy was performed. Chondral shaving and thorough osteophyte removal was performed. Soft tissue release is carried out according to the pre-operative deformity. Cuts were made for the distal femoral bone using measured resection techniques. Perpendicular to the mechanical axis tibial cuts were made using an extra medullary alignment guide, with posterior tibial slope set at 0 degrees. Trial implant was placed to assess the joint space, varus /valgus stability, condylar lift off and patellar mal tracking. Gentamycin coated bone cement was used for fixation of the femoral and tibial prosthesis. Patelloplasty is performed in all patients in all the knees with or without denervation of patella. Resurfacing of patella was not performed on all knees. Electro cautery was performed using electro cautery unit with monopolar coagulation which was set at 35 ECU (50W), and it was performed to a depth of approximately 1mm, and within 2 mm margin around the patella (Fig. 1). After implantation, knee stability and patella tracking was checked. Drain was secured and skin was closed in layers. Knee bending and quadriceps strengthening exercises were initiated from the day of surgery. The drain removal was done on 3rd post-operative day and full weight bearing mobilization was initiated. Every third day dressing was changed and post-operative analgesics were continued for a period of 8-10days and suture removal done on 11th post-operative day.

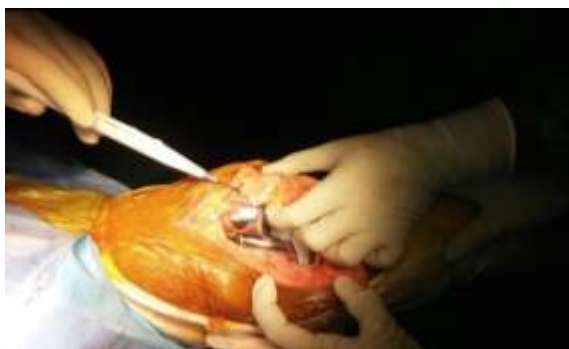

Fig. 1: Patellar rim cauterization

Table 1: Comparison between cautery and non cautery with ROM (range of motion), WOMAC (Western Ontario and Mc Masters Universities), KSS (Knee Society Score)

	Group	N	Mean	Std. Deviation	T	Df	P value
Pre-operative: ROM	Non Cautery	33	85	17.545	-0.686	64	0.495
	Cautery	33	87.73	14.636			
6 Weeks: ROM	Non Cautery	33	98.18	12.858	-1.323	64	0.191
	Cautery	33	101.82	9.17			
12 Weeks: ROM	Non Cautery	33	104.55	7.942	-1.448	64	0.152
	Cautery	33	107.58	9.024			
24 Weeks: ROM	Non Cautery	33	107.58	7.513	-0.935	64	0.353
Pre-operative: KSS objective	Non Cautery	33	56.67	5.109	-0.327	64	0.744
	Cautery	33	57.09	5.41			

Assessment

All patients undergoing patellar rim cauterization were evaluated with Knee society score (objective and functional), WOMAC (Western Ontario and McMasters Universities), Feller's Knee score and ROM (range of motion) at pre-operative and post-operative period (6 weeks, 12 weeks and 24 weeks).

Statistical Analysis

All statistical analysis was done using SPSS version 16 software. A continuous variable were expressed as mean+/- Standard Deviation. The inter group comparisons used independent samples t-test, whereas the pre and post-operative values were compared by using paired sample t-test. A P-value <0.05 was considered to be significant.

Results

66 patients were included in the study, the mean age is 64.4 and 63 years for cautery and non-cautery respectively, in which majority of them lie in the age group between 61-70 years (around 51.5%). Out of the 66, 49 (74.2%) were females and 17 were males. ROM between the two groups shows that 6 Weeks ROM is higher in cautery group with a t value of -1.323 and is found to be statistically non-significant with a p value of 0.191. Similarly at 12 weeks and 24 weeks, results were noted to be higher in cautery group but were found to be statistically insignificant with p values of 0.152 and 0.353 respectively. KSS objective scoring between the two groups at 6 Weeks shows higher scores in cautery group with a t value of -2.268 and is statistically significant with a P value of 0.027, but no significant change was noted between the two group at 12 and 24 weeks with p value of 0.086 and 0.857 (Fig. 2). For KSS functional, WOMAC and Feller's knee score significant improvement was noted from pre operative to post operative period in both the groups, but no significant difference was noted between the two groups at pre operative, 6 weeks, 12 weeks and 24 weeks. (Fig. 3)(Table 1).

6 Weeks: KSS objective	Non Cautery	33	71.79	6.909	-2.268	64	0.027
	Cautery	33	75.27	5.496			
12 Weeks: KSS objective	Non Cautery	33	80.15	5.501	-1.746	64	0.086
	Cautery	33	82.24	4.131			
24 Weeks: KSS objective	Non Cautery	33	83.7	4.341	-0.748	64	0.457
Pre-operative: KSS Functional	Non Cautery	33	56.55	4.139	1.051	64	0.297
	Cautery	33	54.61	9.763			
6 Weeks: KSS Functional	Non Cautery	33	69.33	6.357	-1.137	64	0.26
	Cautery	33	70.91	4.792			
12 Weeks: KSS Functional	Non Cautery	33	77.03	4.246	-0.396	64	0.693
	Cautery	33	77.45	4.452			
24 Weeks: KSS Functional	Non Cautery	33	81.36	3.904	0.039	51.46 2	0.969
	Cautery	33	81.33	2.273			
Pre-operative: WOMAC	Non Cautery	33	54.54849	4.396669	0.373	64	0.71
	Cautery	33	54.13636	4.580176			
6 Weeks: WOMAC	Non Cautery	33	65.64546	5.391724	0.135	64	0.893
	Cautery	33	65.46667	5.373934			
12 Weeks: WOMAC	Non Cautery	33	73.78788	3.523205	-0.476	64	0.636
	Cautery	33	74.24849	4.29681			
24 Weeks: WOMAC	Non Cautery	33	81.67879	3.982521	-0.619	64	0.538
	Cautery	33	82.25758	3.599395			
Pre-operative: Feller's	Non Cautery	33	13.94	1.919	-1.239	64	0.22
	Cautery	33	14.61	2.423			
6 Weeks: Feller's	Non Cautery	33	21.15	2.706	-0.765	64	0.447
	Cautery	33	21.64	2.434			
12 Weeks: Feller's	Non Cautery	33	24.82	1.685	-0.892	64	0.376
	Cautery	33	25.24	2.151			
24 Weeks: Feller's	Non Cautery	33	26.39	1.58	-1.555	64	0.125

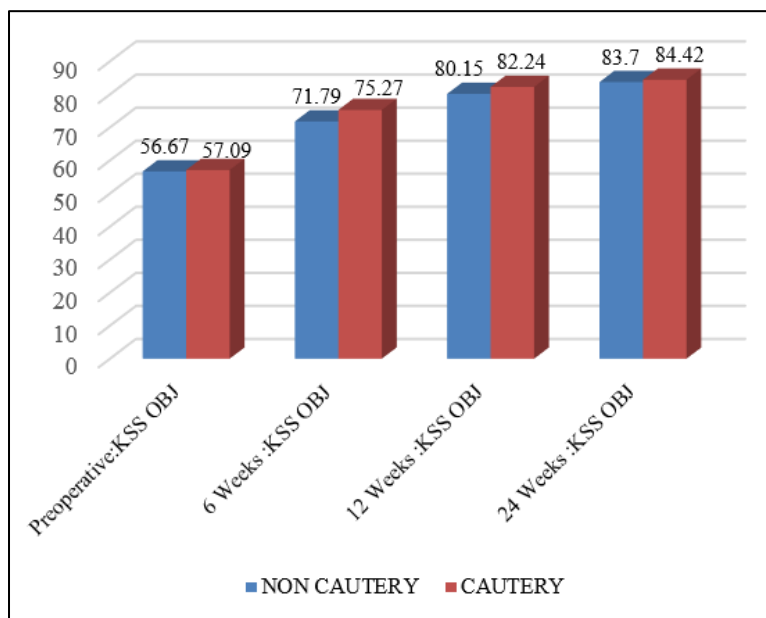


Fig. 2: KSS objective scores at 6, 12 and 24 weeks in cautery and non cautery groups

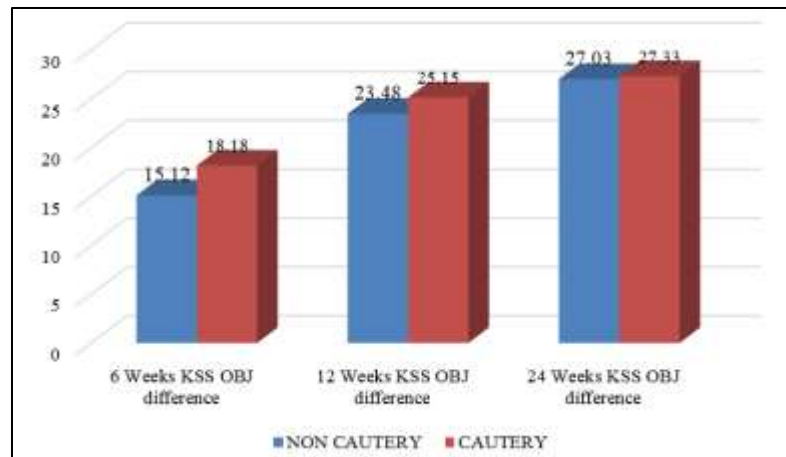


Fig. 3: KSS objective score difference

Discussion

In post TKA patients, many studies have addressed the anterior knee pain which is strongly associated with the patellofemoral area.^{19,20} In osteoarthritis the pathophysiology of anterior knee pain is multifactorial; hence many aspects of anterior knee pain after TKA needs more detailed studies. Patella component related complications are also associated with anterior knee pain such as component wear, fractures, loosening, ligament and tendon ruptures, maltracking hence indicating for patellar retention or selective resurfacing of the patella. In this study, we performed patellar rim cauterization to relieve the pain in patellofemoral region, as has been performed by several authors.^{14,15} According to Maralclan et al,²¹ there are two primary nerve supplies to the patella, superomedial and super lateral, which course within the substance of vastus medialis and lateralis, hence denervation should include both. Therefore, we performed a circumpatellar denervation.

In our study, we found the mean age for cautery and non-cautery to be 64.64 and 63 years respectively. 51.5% of the total patients in the study belonged to the age group between 61-70 years. In the study done by Gupta et al,²² the mean age group was found to be 67.43 in cautery and 67.41 in non-cautery. In our study we found statistically significant difference between the patella rim cauterized and non-cauterized group at 6 weeks for Objective Knee society scores, however the objective knee scores showed no statistical significance at 12 and 24 weeks. The Range of motion, KSS functional score, Feller's patellar score and WOMAC score did not show any statistical significance for electro cautery of the patellar rim with patella non-resurfacing. Study done by Soo Jae Yim et al²³ concluded no significant differences between cauterization and non-cauterization groups, their scoring systems, which was similar to our study.

There are not many studies documenting favorable outcomes for use of patellar rim electrocautery.²⁴ Also pain is considered to be more of a subjective symptom, hence making it more difficult to assess the patellofemoral joint pain. Another study done by Altay MA et al,¹⁷ to evaluate the effect of patellar denervation using electrocautery in 35

cases of bilateral TKA, he concluded that electrocautery seems to decrease anterior knee pain and improve clinical outcomes. In our study we found no significant difference in functional outcomes after patellar rim cauterization. Hence, the anterior knee pain relieving measure by electro cauterization of patellar rim is not clearly defined.

The limitations of this study include the small number of patients and period of follow up being only 6 months. Also, due to financial constraints among the patients different implants were used from different manufactures which may also have affect over the functional outcomes, but all TKA prosthesis were fixed bearing posterior cruciate ligament sacrificing type. Further, larger long term prospective comparative series are required to support these results.

Conclusion

The use of electrocautery of patella rim in non-resurfacing total knee replacement did not result in significant improvement in the functional outcomes, ROM, KSS scores, Feller's scoring and WOMAC score.

Hence, we conclude electrocautery of patellar rim is not an effective measure for relieving anterior knee pain.

Patient Declaration Statement

"The authors certify that they have obtained all appropriate patient consent forms. In the form the patient(s) has/have given his/her/their consent for his/her/their images and other clinical information to be reported in the journal. The patients understand that their names and initials will not be published and due efforts will be made to conceal their identity, but anonymity cannot be guaranteed."

Conflict of Interest: None.

References

1. Scott WN, Rubinstein M, Scuderi G. Results After knee replacement with a posterior cruciate- substituting prosthesis. *J Bone Jt Surg Am* 1988;70:1163.
2. Riley LH, Hungerford DS. Geometric Total knee replacement for treatment of rheumatoid knee. *J Bone Joint Surg* 1976;60:523.

3. Laskin R. Modular total knee arthroplasty. A review of 89 patients. *J Bone Joint Surg Am* 1976;60:523.
4. Scott CE, Howie CR, Mac Donald D. Predicting dissatisfaction following total knee replacement, a prospective study of 1217 patients. *J Bone Joint Surg Br* 2010;92:1253.
5. Fu Y Wang, Fu Q. Patellar resurfacing in total knee arthroplasty for osteoarthritis. A meta analysis. *Knee surg Sports traumatol Arthrosc*. 2011;92:1253.
6. Muoneke HE, Khan AM, Giannikas KA, Haggulund E, Dunningham TH. Secondary resurfacing of patella for persistent anterior knee pain after total knee arthroplasty. *J Bone and Joint Surg* 2003;85:675-678.
7. Smith AJ, Wodt DJ, Li MG. Total Knee Replacement with and without patellar resurfacing: a Prospective, randomised trial using Profix Total knee system. *J Bone Joint Surg* 2008;90:43-49.
8. Lehner B, Koeck FX, Capelino S, Schubert TE, Hofbauer RP. Prepondance of sensory versus sympathetic nerve fibres and increased cellularity in infrapatellar fat pad in anterior knee pain patients after primary arthroplasty. *J Orthop Res* 2008;26:342-350.
9. Macule F, Sastre S, Lasurt S, Sala P Segur JM, Mallofre C. Hoffas fat pad resection in total knee replacement. *Acta Ortho Belgium* 2005;71;714-717.
10. Witonski D, Wagrowska - Danielewicz. Distribution of substance P nerve fibres in the knee joint, in patients with anterior knee pain syndrome. *Knee Surgery Sport Traumatol Arthrosc* 1999;7:177-183.
11. Wojtys EM, Beaman DN, Glover RA. Innervation of human knee with substance P fibres. *Arthrosc* 1990;6:254-263.
12. Vega J, Golanon P, Perrez- Carro L. Electrosurgical Arthroscopic patellar denervation. *Arthrosc* 2006;22:1028e1-3.
13. Moati JC, Zucman J. Treatment of femoropatellar chondropathies by circular denervation of patella. *Rev Chir Orthop Reaparantice Appar Mot* 1987;2:126-129.
14. Keblish PA, Varma AK, Greenwald AS. Patellar resurfacing or retention in total knee arthroplasty. *J Bone Joint Surg* 1994;76:930-937.
15. Barrak RL, Burak C. patella in total knee arthroplasty. *Clin Orthop Relat Res* 2001;389:62-73.
16. Kim Th, Lee DH, Bin SL. The next gen LPS-flex to the knee prosthesis at the minimum of three years. 2008;90:1304-1310.
17. Altay MA, Erturk C. Patellar Denervation in total knee arthroplasty without patellar resurfacing. *Orthop Traumatol* 2012;98:421.
18. Van Jonbergern HP, Scholtes VA, Van kampen A. A randomised, controlled trial of circumpatellar electrocautery in total knee replacement without patellar resurfacing. *J Bone joint Surg* 2011;93:1054.
19. Giles S, Philip N, Jess L, Willam S. The New knee Society Scoring System. *Clinical Orthopaedic and Related Research* November 2011. 2012;4703:3-19.
20. Brunett RS, Boone JL, Rosenzweig SD, Steger-May K, Barrack RL. Patellar resurfacing compared with non resurfacing in total knee arthroplasty, A consise follow up of a randomized trial. *J Bone Joint Surg Am* 2009;91:2562-2567.
21. Maraclan G, Kuru I, Issi S. The innervation of patella: Anatomical and clinical study. *Surg Radil Anat* 2005;27(4):331-335.
22. Gupta S, Augustine, Horey L, Meek RM, Hullin MG, Mohammed A. Electrocautery of patellar rim in primary total knee replacement: beneficial or unnecessary? *J Bone Joint Surg Br* 2010;92:1259-1261.
23. Soo Y, Mun J, Hee K. The effect of electrocautery around the patellar rim in patellar non resurfacing total knee arthroplasty. *Knee Surg Relat Res* 2012;24(2):104.
24. Mori Y, Kuroki Y, Yamamoto R, Fujimoto A, Okumo H, Kubo M. Clinical and histological study of patellar chondropathy in adolescents. *Arthrosc* 1991;7:182-197.

How to cite this article: Shetty A, Manvi N, Shetty SK. To evaluate the functional outcomes in patella rim cauterized total knee arthroplasty. *Indian J Orthop Surg* 2019;5(1):83-87.